

Phrygian Cap Gallbladder and Recurrent Pancreatitis in a Woman

Vitorino Modesto dos Santos¹, Samuel Abner², Marcelo Martins Oliveira³, Viviane Vieira Passini Soares², Uadson Silva Barreto², Lister Arruda Modesto dos Santos⁴

¹ Department of Internal Medicine, Armed Forces Hospital and Catholic University of Brasília, Brasília-DF, Brazil

² Department of Internal Medicine of Armed Forces Hospital, Brasília-DF, Brazil

³ Gastroenterology Division of Armed Forces Hospital, Brasília-DF, Brazil

⁴ Department of General Surgery, State Workers Hospital, São Paulo-SP, Brazil

Received: 24 Apr. 2017; Accepted: 30 Apr. 2017

Abstract- A 65-year-old woman with hypothyroidism and arterial hypertension was admitted with epigastric pain and hyperemesis. Five months before, she had the diagnosis of non-lithiasic acute pancreatitis without complications, and the hypothesized etiology was alcohol abuse. The current manifestations were initially related to an active gastric ulcer evidenced by the endoscopic study. Laboratory data were consistent with acute pancreatitis, and ultrasonography showed images of pancreatitis, in addition to the incidental detection of the hydropic gallbladder with a Phrygian cap. These diagnoses were confirmed by the imaging study of computed tomography with contrast. Clinical significance of Phrygian cap anomaly is herein emphasized because of diagnostic challenges, in addition to possible etiopathogenic role in cholecystitis, gallstones, and pancreatitis. The eventual association of the gallbladder anomaly with the Saint's triad is also commented. This scarcely reported triad includes hiatus hernia, diverticulosis, and lithiasic cholecystopathy.

© 2018 Tehran University of Medical Sciences. All rights reserved.

Acta Med Iran 2018;56(11):729-731.

Keywords: Hydropic gallbladder; Pancreatitis; Phrygian cap anomaly; Saint's triad

Introduction

The phrygian cap is the most common congenital anomaly involving the shape of the gallbladder and develops during the fourth week of gestation, but it is more often incidentally diagnosed (1-4). The isolated change of Phrygian cap may be considered without pathologic significance, but this uncommon anomaly can play an etiologic role in gallstones, cholecystitis, and pancreatitis (1-8). Saint's triad is the concomitance of hiatus hernia, diverticulosis, and lithiasic cholecystopathy. The aim was to describe this scarcely reported entity and its implications according to literature, and report the case of an elderly woman affected by this condition and recurrent pancreatitis. Additional comments about the eventual association of this anomaly with the Saint's triad are discussed.

Case Report

A 65-year-old woman with hypothyroidism and arterial hypertension was admitted with moderate continuous epigastric pain, and several episodes of

vomiting, initiated one day before. She was hospitalized five months ago due to acute pancreatitis without evidence of cholelithiasis, and imaging studies detected a Phrygian cap deformity in a hydropic gallbladder (Figures 1A to 1C). She was tobacco smoker (52 pack/year) and alcohol abuser (61.6 unities/week) but denied increased alcohol ingestion in the recent period preceding this hospitalization. On admission, she was dehydrated (+/4+), with the absence of normal abdominal sounds, and hypertympanic percussion sounds in upper abdominal areas, in addition to pain elicited by palpation on the epigastric region and on the left iliac fossa. The rest of physical examination was unremarkable. Abnormal laboratory tests were hemoconcentration (hemoglobin 16.6 g/dl, hematocrit 47.8%), leukocytosis (14.870/mm³, 88% segmented, and 4% band forms), high levels of amylase (268.7 IU/L), lipase (718.6 IU/L), AST (657.4 U/L), ALT (262.4 U/L), gamma GT (919 U/L), alkaline phosphatase (224.3 U/L), and bilirubin (total 3.58, direct 2,21 mg/dl). Lipid profile and thyroid function tests were: total cholesterol 112 mg/dl, triglycerides 150 mg/dl, HDL 9 mg/dl, LDL 73 mg/dl, VLDL 30 mg/dl, TSH 0.28 µIU/ml, free T4 1.78 ng/dl. Computed tomography (CT)

Corresponding Author: V. Modesto dos Santos

Department of the Internal Medicine, Armed Forces Hospital and Catholic University of Brasília, Brasília-DF, Brazil
Tel: + 55 61 39662103, Fax: + 55 61 32331599. E-mail address: vitorinomodestos@gmail.com

of the abdomen with contrast showed a Balthazar D pancreatitis without necrosis, the Phrygian cap anomaly, and the hydropic gallbladder (Figures 1B and 1D); gallstones were not detected. Moreover, colonic diverticulosis was also observed (Figures 1D and 1E). Although microlithiasis was not entirely ruled out, alcoholism was the main probable etiologic factor in the present case study. Laboratory determinations on the occasion of hospital discharge showed hemoglobin 12.9 g/dl, hematocrit 36.6%, leukocytes 9,700/ mm³, 56%

segmented (without band forms), amylase 32.7 IU/L, lipase 58.6 IU/L, AST 51.7 U/L, ALT 64 U/L, gamma GT (883 U/L), and alkaline phosphatase (154 U/L). The symptoms claimed at admission were attributed to an active gastric ulcer revealed by upper digestive endoscopy. The patient underwent nutritional and clinical symptomatic management and had rapid improvement. Successfully controlled, the patient was referred to follow-up on Gastroenterology outpatient service.

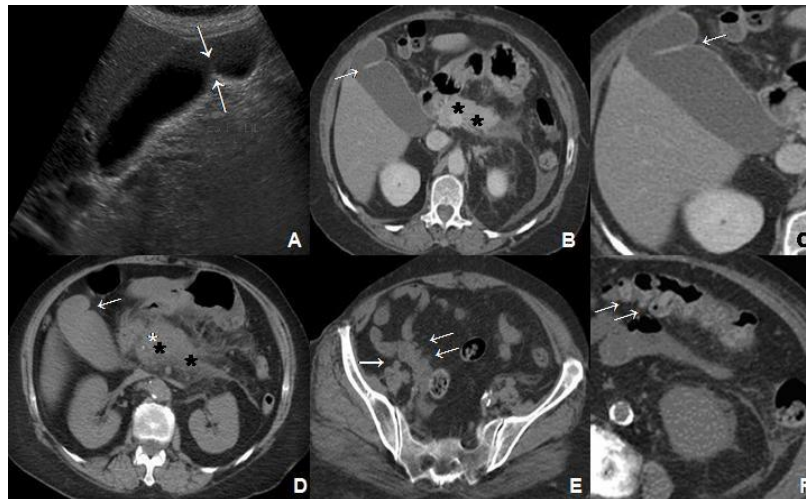


Figure 1. A: Ultrasonography of abdomen showing a septae between the body and the fundus of gallbladder (arrows), which causes a “Phrygian cap” aspect; B and C: CT of abdomen done during a previous episode of pancreatitis, showing the Phrygian cap anomaly (arrows) and the changes of pancreatitis (stars); D: Phrygian cap gallbladder (arrow), diffuse increase of pancreatic volume (stars) and of the density in peripancreatic fat, mainly in the body and tail, and thickening of perirenal space detected by CT in present admission; E and F: diverticulosis (arrows) observed in colonic segments

Discussion

Phrygian cap anomaly is the most common congenital change of gallbladder, with an estimated prevalence of 4%, and characterized by fold or septa between the body and fundus (Figures 1A to 1D). This was described by Boyden (1935), who associated the typical change with the aspect of the caps utilized by ancient Phrygians from Minor Asia during 1200-700 BC (1-4). The anomaly appears during the fourth week of gestation, the embryogenic phase in which the liver, biliary tree, and gallbladder ventrally origin from the most distal portion of the anterior intestine (3,4). The peculiar Phrygian cap format is usually due to a fold or kinking between the body and the fundus of the gallbladder (1-4), but it has been also associated with the presence of septae (7). Therefore, it may mimic or appear synchronously with bilobed or with septate gallbladder anomaly (2,6). The single change of Phrygian cap can be considered without pathologic significance, but many cases have been described in

association either with calculous or acalculous cholecystitis (1,2,5-7). Kannan *et al.*, (2014), reported the case of a 55-year-old man with bilobed gallbladder coexistent with Phrygian cap anomaly in each of the lobes, and a 30 mm gallstone was found (2). Worthy of note, the incidence of both of these conditions are 0.025% and 4%, respectively (2). Similarly, the case of a 51-year-old woman with Phrygian cap associated with three gallstones and acute cholecystitis was reported by de Csepel *et al.*, in 2003 (1). In their opinion, prophylactic cholecystectomy should be done if there is potential biliary stasis in Phrygian cap anomaly (1). According to Lee and Enns (2007), microlithiasis is a common cause of idiopathic acute pancreatitis, with the prevalence of 6 to 73% (9). As microliths are smaller than 3 mm in diameter, they sometimes pass undetected in imaging studies by ultrasonography, CT or magnetic resonance (9). Microlithiasis can cause acute pancreatitis by transitory obstruction of the duodenal papilla and consequent stasis of the flux by pancreatic duct. Therefore, microlithiasis should be the major concern in

idiopathic recurrent pancreatitis, and cholecystectomy is the best option (9). Embryological septa may be isolated or multiple and are usually detected by ultrasonography, CT, cholescintigraphy, and endoscopic retrograde cholangio pancreatography (ERCP) studies (2). Basaranoglu and Balci (2005) described biliary sludge, cholangitis, and recurrent pancreatitis in a 31-year-old woman with Phrygian cap anomaly (6). Esper *et al.*, (1992), reported septate gallbladder and cholelithiasis in a 6-year-old girl with chronic abdominal pain and commented on the major role of septa as predisposing factor of gallstones (8). Gmelin *et al.*, (1981), described gallstones in Phrygian cap disorder and commented the false-positive diagnosis posed by gallbladder septa, which can mimic gallstones in gray scale ultrasonography (7). Miwa *et al.*, (2000), reported unsuspected multiseptate gallbladder and cholelithiasis in an old woman with gastric ulcers. Biliary disorders were incidentally detected in ultrasonography and confirmed by ERCP studies (10). Spech *et al.*, (2013), reviewed data from 2,437 patients and found 3.8% with septate gallbladders (11). The septa were incidentally detected, and there were no differences in gender distribution or related to aging. Worthy of note, gallstones occur more often in septate gallbladders, and symptomatic septa may be not clinically differentiated from cholelithiasis (11). Additional concern is about acalculous cholecystitis in Phrygian cap anomaly, as was reported by Al-Ashqar *et al.*, (2013), in a 53-year-old woman submitted to cholecystectomy (5). Moreover, Wani *et al.*, (2009), described acalculous cholecystitis in a 46-year-old woman with bilobed gallbladder diagnosed by ultrasonography (12). However, the septae originated a transversal division in the gallbladder, different from the present report. Similar to the case herein described, an 81-year-old man was reported with Phrygian cap anomaly and diverticulosis (4), phenomenon hypothetically favoring mechanisms of herniosis to explain the Saint's triad (13). Currently, Saint's triad means hiatus hernia, diverticulosis, and cholecystitis or cholelithiasis (13), but the authors believe that gallbladder anomalies with or without lithiasic complications might be included. Further studies, with more representative number of patients, would help to settle this matter.

In the absence of hernia, the current reported patient had two of the three components of the Saint's triad. The current literature strongly indicates a potential pathogenic role played by congenital anomalies like Phrygian cap gallbladder, in special in the setting of

gallstones, cholecystitis, and pancreatitis. Therefore, it would be better to consider the possible further inclusion of this condition in the Saint's triad. Case studies may increase the suspicion index and the interest of researchers about rare entities.

References

1. de Csepel J, Carroccio A, Pomp A. Soft-tissue images. "Phrygian cap" gallbladder. *J Can Chir* 2003;46:50-1.
2. Kannan NS, Kannan U, Babu CPG. Congenital bilobed gallbladder with Phrygian cap presenting as calculus cholecystitis. *J Clin Diag Res* 2014;8:ND05-6.
3. Rafailidis V, Varelas S, Kotsidis N, Rafailidis D. Two congenital anomalies in one: an ectopic gallbladder with Phrygian cap deformity. *Case Rep Radiol* 2014;2014:246476.
4. van Kamp MJS, Bouman DE, Steenvoorde P, Klaase JM. A Phrygian cap. *Case Rep Gastroenterol* 2013;7:347-51.
5. Al-Ashqar M, Maliyakkal AK, Shiwani MH, Anwar S. Acalculous Phrygian cap cholecystitis. *BMJ Case Rep* 2013;2013:bcr2013009921.
6. Basaranoglu M, Balci NC. Recurrent cholangitis associated with biliary sludge and Phrygian cap anomaly diagnosed by magnetic resonance imaging and magnetic resonance cholangiopancreatography despite normal ultrasound and computed tomography. *Scand J Gastroenterol* 2005;40:736-40.
7. Gmelin E, Freitag H, Fuchs HD. Ultrasound misdiagnosis of gallbladder concrements in "Phrygian cap" deformity. *Dtsch Med Wochenschr* 1981;106:1067-8.
8. Esper E, Kaufman DB, Crary GS, Snover DC, Leonard AS. Septate gallbladder with cholelithiasis: a cause of chronic abdominal pain in a 6-year-old child. *J Pediatr Surg* 1992;27:1560-2
9. Lee JK, Enns R. Review of idiopathic pancreatitis. *World J Gastroenterol* 2007;13: 6296-313.
10. Miwa W, Toyama K, Kitamura Y, Murakami K, Kamata K, Takada T, Tanabe H, Kanayama M. Multiseptate gallbladder with cholelithiasis diagnosed incidentally in an elderly patient. *Intern Med* 2000;39:1054-9.
11. Spech HJ, Hümmer N, Braun H. Septate gallbladder. *Med Klin* 1975;70:941-6 .
12. Wani I, Bhat Z, Charak A, Sofi R. Acalculous cholecystitis in a septate gallbladder. *Internet J Third World Med* 2008;7:2.
13. Hauer-Jensen M, Bursac Z, Read RC. Is herniosis the single etiology of Saint's triad? *Hernia* 2009;13:29-34.