

Recurrent Abdominal Actinomycosis With Multiple Organ Involvement: A Rare Clinical Presentation

Vikram Rajput¹, Basavraj Warad¹, Vijay Chincholkar², Milind Davane³, Basavraj Nagoba³

¹ Department of Surgery, MIMSR Medical College, Latur, India

² Department of Microbiology, Govt. Medical College, Latur, India

³ Department of Microbiology, MIMSR Medical College, Latur, India

Received : 03 Aug. 2017; Accepted: 19 Dec. 2017

Abstract- Actinomycosis is a chronic granulomatous bacterial disease. It has a tendency to spread contagiously and suppurate forming granulation tissue, and multiple abscesses, which drain through skin forming sinus tracts. Sulphur granules discharging through sinus tracts are the characteristic features. Its varied presentation is always confused with malignancy rather than an infective process. We report an extraordinary case of recurrent abdominal wall actinomycosis spreading to the liver, right kidney, intestine, and pelvic organs because of discontinued treatment with penicillin. We emphasize the importance of long-term antibiotic treatment, which if deferred can lead to recurrence of the disease which could be life threatening at times.

© 2018 Tehran University of Medical Sciences. All rights reserved.

Acta Med Iran 2018;56(11):732-735.

Keywords: Actinomycosis; Laparotomy; Antibiotic treatment; Abdominal wall; Recurrence

Introduction

Actinomycetes are normally present in the oral cavity, gastrointestinal tract, and female genital tract. They are non-virulent commensals, which are unable to invade deeper tissues and cause illness as long as there is no break in the integrity of the mucous membranes and no devitalized tissue is present. The destruction of the mucosal barrier by trauma, operations, immunosuppression, and chronic inflammatory diseases are important predisposing factors. They cause multiple abscesses and sinus tracts and can invade any organ without anatomical plane defined (1-4). Its varied clinical presentation is always confused with malignancy rather than an infective process and hence, is described as 'the most misdiagnosed disease (5-7).

We report a case of primary abdominal wall actinomycosis, which is rare and then noncompliance of patient to antibiotics leading to recurrence of disease with multiple organs involvement. To the best of our knowledge, a case of recurrent actinomycosis involving multiple vital organs in a patient not using the intrauterine contraceptive device (IUCD) is being presented for the first time.

Case Report

A 40-year-old female, presented with fever, weakness, loss of appetite, multiple swelling over abdomen with multiple discharging sinuses over abdomen and groin regions for 6 months. She was operated 5 years back for a swelling over abdomen with the discharge of white granules like substance from it. Histopathologic examination of abdominal mass with sinus tract had confirmed the diagnosis of actinomycosis of the abdominal wall (Figure 1).

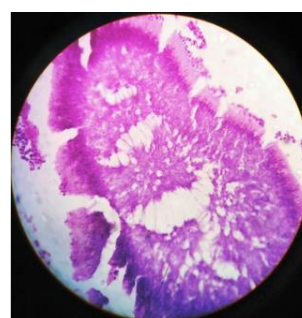


Figure 1. H and E stain showing characteristic bacterial colony with central sulfur granules and radiating filaments with club-like ends (sunray appearance) confirming the diagnosis of actinomycosis

Corresponding Author: B.S. Nagoba

Department of Microbiology, MIMSR Medical College, Latur, India

Tel: + 91 23 82227424, Fax: +91 23 82227246, E-mail addresses: dr_bsnagoba@yahoo.com

She was advised to take penicillin injections for 6 months, but she took only for 1 month. Patient had history of tubal ligation 15 years back. She did not have an intra-uterine contraceptive device. On examination, she was febrile with pallor and edema of lower limbs. In examination of the abdomen, the scar of previous surgery was found extending from infra-umbilicus to above suprapubic region. Tenderness was present all over the abdomen. Lower abdomen and groin region showed 5-6 healed and 2-3 active discharging lesions (Figure 2).

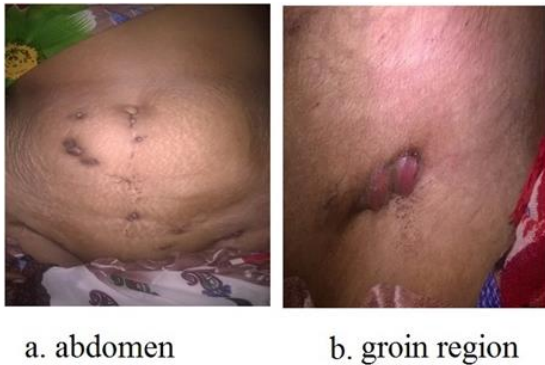

Figure 2. Lower abdomen and groin region showing healed and active discharging lesions

There was irregular swelling over left iliac fossa, which on palpation found to be firm mass. The liver was found to be palpable 2 fingers below the costal margin and was nodular in consistency.

Her investigations revealed anaemia (Hemoglobin-7.6 mg/dl), white blood cells (WBC) count 18,000/mm³ with 91% neutrophils and erythrocyte sedimentation rate (ESR) 35 mm. Her renal and liver function tests and serum electrolytes were within normal limits.

On ultrasonography (USG) of abdomen hyperechoic lesions in the right lobe of the liver, upper pole of right kidney, pelvis, and an elongated cystic lesion in the anterior abdominal wall were seen. On computed tomography (CT) scan of abdomen and pelvis, multiple well defined peripherally enhancing lesions involving right lobe of liver and upper pole of the right kidney were seen. Similar lesions over the anterior and posterolateral abdominal wall were also seen. A heterogeneous enhancing mass involving right adnexa and well defined cystic mass in the right ovarian region were seen (Figures 3 and 4).

She was counseled regarding surgical intervention, but she denied any surgical procedure. She took discharge against medical advice and subsequently died at home after one month.

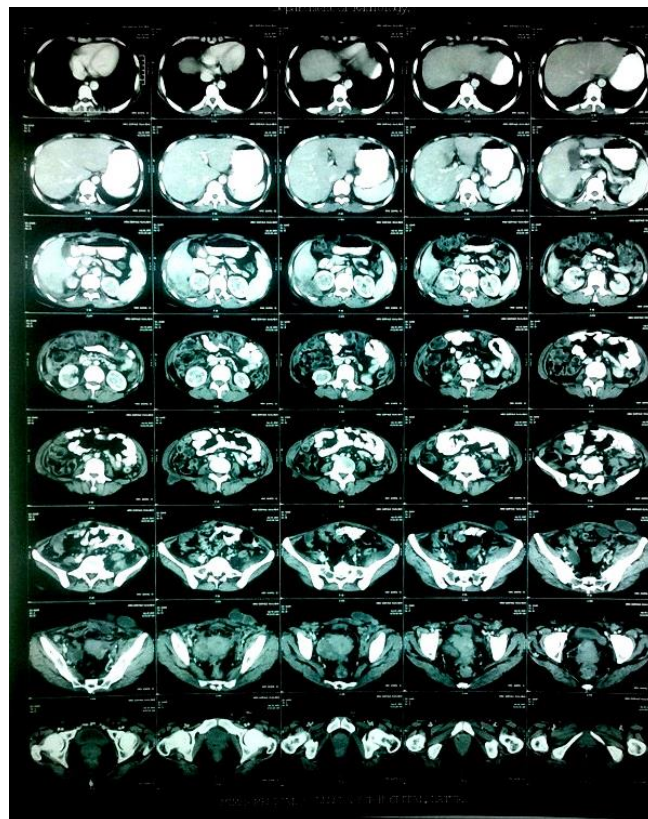


Figure 3. Abdominal CT sections showing multiple well defined peripherally enhancing lesions involving right lobe of liver and upper pole of the right kidney

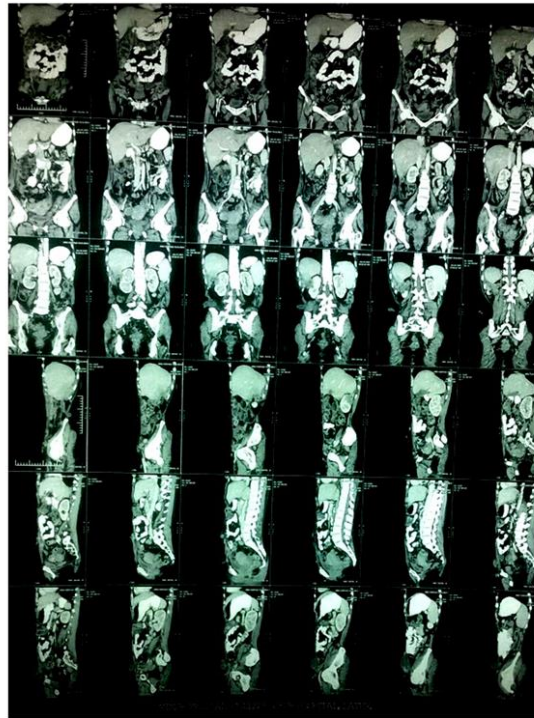


Figure 4. Abdominal CT sections showing multiple well defined peripherally enhancing lesions over anterior and posterolateral abdominal wall, a heterogeneous enhancing mass involving right adnexa and well defined cystic mass in the right ovarian region

Discussion

Actinomycosis is a clinical infection most commonly caused by *Actinomyces israelii*. This organism is a part of normal flora and has very low virulence potential because of which unable to cause infection unless the normal mucosal barrier is broken (2). The most frequent site of human infection is the cervicofacial area, accounting for about 50 to 65 % cases followed by abdominal (20%) and thoracic (15%) areas (1,2). The abdominal disease usually results from clinical or subclinical disruption of bowel mucosa. It often occurs as a firm mass that appears fixed to the surrounding tissue and can be mistaken for tumor (5,6,8,9). Actinomycosis mimics malignancy on clinical presentation, and hence, diagnosis is often made only after laparotomy for suspected malignancy.

It has been reported that the majority of the cases of actinomycosis are seen in women (75%) and most of them are associated with IUCD (60%) (10). Abdominopelvic actinomycosis or isolated abdominal wall actinomycosis has been frequently reported in females using an IUCD (1,2,11-13). In recent years, abdominal actinomycosis in females has acquired importance because of its frequent occurrence in IUCD

users (14). In the present case, the infection was not associated with the use of IUCD, although long-term use of an IUCD as a significant risk factor for pelvic actinomycosis and its spread to other sites such as the abdominal wall has commonly been reported in most of the earlier studies (1,2,11-13).

Prolonged use of antibiotics is a choice of treatment in case of local infection. However, in case of extensive involvement of tissues/organs, surgical intervention along with post-operative prolonged antibiotic therapy for weeks to several years should be the choice of treatment as the intense desmoplastic reaction associated with actinomycosis limits drug penetration (3). Inadequate use of antibiotics for post-operative patients can lead to recurrence and need of 2nd laparotomy, and if not managed at this stage, it may become life-threatening. The recurrence involving multiple organs in the present case is the result of discontinued treatment with penicillin after first laparotomy and further denial for the second laparotomy is the reason for the death of patient indicating the importance of second laparotomy, adequate antibiotic treatment, and meticulous follow up.

The uncommon aspect of this case is that it was a case of recurrent abdominal actinomycosis with inadequate antibiotic treatment that resulted in extensive

involvement of many organs like an abdominal wall, intestine, kidney, pelvis, ovarian region, groin, and liver. To the best of our knowledge, such a case of wide involvement of recurrent actinomycosis is very rare and is being reported for the first time.

It is concluded on the basis of literature review and findings in the present case that actinomycosis of the abdomen is a rare presentation, and is very rare in non-IUCD users. Post-surgical discontinued antibiotic treatment of primary actinomycosis leads to recurrent actinomycosis with multiple organs involvement, which is very difficult to cure. The results also emphasize the importance of surgery and continuous adequate antibiotic therapy in the appropriate management of actinomycosis, even in cases of recurrent actinomycosis (12).

References

1. Sergent F, Marpeau L. Actinomycose abdominopelvienne: un syndrome tumoral lié à une bactérie. *J Chir (Paris)* 2004;141:150-6.
2. Filiporic B, Milinic N, Nikolic G, Ranelovic T. Primary actinomycosis of the anterior abdominal wall: case report and review of the literature. *J Gastro Hepatol* 2005;20:517-20.
3. Bennhoff DF. Actinomycosis: diagnostic and therapeutic considerations and a review of 32 cases. *Laryngoscope* 1984;94:1198-217.
4. Karateke F, Özyazıcı S, Menekşe E, Daş K, Özdoğan M. Unusual presentations of actinomycosis; anterior abdominal wall and appendix: report of three cases. *Balkan Med J* 2013;30:315-7.
5. Yi F, Prasad S, Sharkey F, Kahlenberg M. Actinomycotic infection of the abdominal wall mimicking a malignant neoplasm. *Surg Infect* 2008;9:85-9.
6. Kadioglu H, Ersoy YE, Bozkurt S, Memmi N, Cipe G, Gucin Z, Muslumanoglu M. Actinomycotic infection of the abdominal wall mimicking a malignant neoplasm. *Surg Infect* 2012;13:413-14.
7. Weese WC, Smith IM. A study of 57 cases of actinomycosis over a 36-year period. A diagnostic 'failure' with good prognosis after treatment. *Arch Intern Med* 1975;135:1562-8.
8. Perlow JH, Wigton T, Yordan EL, Graham J, Wool N, Wilbanks GD. Disseminated pelvic actinomycosis presenting as metastatic carcinoma: association with the Progestasert intrauterine device. *Rev Infect Dis* 1991;13:1115-9.
9. Hinnie J, Jacques BC, Bell E, Hansell DT, Milroy R. Actinomycosis presenting as carcinoma. *Postgrad Med J* 1995;71:749-50.
10. Lunca S, Bouras G, Romedea NS, Pertea M. Abdominal wall actinomycosis associated with prolonged use of an intrauterine device: a case report and review of literature. *Int Surg* 2005;90:236-40.
11. Yilmaz M, Akbulut S, Samdanci ET, Yilmaz S. Abdominopelvic actinomycosis associated with an intrauterine device and presenting with a rectal mass and hydronephrosis: A troublesome condition for the clinician. *Int Surg* 2012;97:254-9.
12. Carkman S, Ozben V, Durak H, Karabulut K, Ipek T. Isolated abdominal wall actinomycosis associated with an intrauterine contraceptive device: A case report and review of the relevant literature. *Case Reports in Med.* 2010;2010:pii 340109.
13. Galata CL, Vogelmann R, Gaiser T, Post S, Horisberger K. Abdominopelvic actinomycosis in three different locations with invasion of the abdominal wall and ureteric obstruction: An uncommon presentation. *Int J Surg Case Rep* 2015;12:48-51.
14. Valour F, Senechal A, Dupieux C, Karsenty J, Lustig S, Breton P. Actinomycosis: etiology, clinical features, diagnosis, treatment, and management. *Infect Drug Resist* 2014;7:183-97.