

Adenoid Hyperplasia in a Patient With a Rare Type of Hyper Immunoglobulin M Syndrome Due to CD40 Deficiency

Ahmad Bahrami¹, Zahra Soltani¹, Mohammad Reza Fazlollahi², Farzaneh Rahmani^{3,4,5}, Massoud Houshmand⁶, Marzieh Mazinani², Nima Rezaei^{3,4,7}

¹ Division of Allergy and Immunology, Ali-Asghar Hospital, Iran University of Medical Sciences, Tehran, Iran

² Immunology, Asthma and Allergy Research Institute, Tehran University of Medical Sciences, Tehran, Iran

³ Research Center for Immunodeficiencies, Children's Medical Center, Tehran University of Medical Sciences, Tehran, Iran

⁴ Network of Immunology in Infections, Malignancy, and Autoimmunity (NIIMA), Universal Scientific Education and Research Network (USERN), Tehran, Iran

⁵ NeuroImaging Network (NIN), Universal Scientific Education and Research Network (USERN), Tehran, Iran

⁶ Department of Medical Genetics, National Institute of Genetic Engineering and Biotechnology (NIGEB), Tehran, Iran

⁷ Department of Immunology, School of Medicine, Tehran University of Medical Sciences, Tehran, Iran

Received: 11 May 2018; Accepted: 08 Jun. 2018

Abstract- CD40 deficiency yield to an autosomal recessive subtype of hyper-immunoglobulin M syndrome (HGIM type 3), presenting with an almost identical clinical picture to X-linked CD40L deficiency (HIGM type 1) with profound T-cell dysfunction yielding to opportunistic infections as well as neutropenia, autoimmunity, and malignancy. We presented a girl with recurrent upper respiratory tract infections and lymphoid hyperplasia which was diagnosed with type 3 hyper IgM syndrome due to CD40 gene mutation. Otitis media with opportunistic germs and no evidence for an X-linked pattern of inheritance were diagnostic keys to type 3 hyper IgM syndrome in our patient.

© 2018 Tehran University of Medical Sciences. All rights reserved.

Acta Med Iran 2018;56(12):811-814.

Keywords: Hyper-immunoglobulin M syndrome; CD40; HIGM type 3; Lymphoid hyperplasia

Introduction

Hyper IgM syndrome (HIGM) is a rare genetic disorder defined by normal or elevated serum IgM in the presence of marked decrease or absence of other immunoglobulin subtype levels (IgG, IgA, IgE) (1). HIGM is a result of defective immunoglobulin class-switch recombination (CSR), which means the inability of naïve B-cells to express other immunoglobulin isotypes than IgM and IgD, and is usually associated with somatic hypermutation (SHM) defect, meaning inability of effector B-cell descendants to produce antibodies with higher binding affinity to the target antigen.

HIGM can be clinically classified into defects confined to B-cell function resulting in pure humoral immunodeficiency and defects that additionally interfere with the function of monocyte, dendritic cells (DCs) as well as T-cell functions, giving rise to combined immunodeficiency phenotype (2). The clinical picture of

HIGM ranges from recurrent sinopulmonary infections, susceptibility to opportunistic infections famously, *Pneumocystis carinii* pneumonia, chronic diarrhea due to *Cryptosporidium* infections, and in subtypes with T-cell dysfunction, increased rate of autoimmune disorders, lymphoid malignancies and neutropenia (3).

Case Report

A 6-year-old girl was referred to the immunology clinic with a history of recurrent upper respiratory tract infections. She was the first and only child, born full-term to second-degree consanguineous parents. Her umbilical cord had separated at the right time, and she had completed her immunization program with no complications.

She was doing well during her first two years of life when at 26 months had an episode of afebrile urinary tract infection, which was managed outpatient with oral antibiotics after anatomical and functional abnormalities

Corresponding Author: N. Rezaei

Research Center for Immunodeficiencies, Children's Medical Center, Tehran University of Medical Sciences, Tehran, Iran
Tel: +98 21 66929234, Fax: +98 21 66929235, E-mail address: rezaei_nima@tums.ac.ir

Adenoid hyperplasia in HIGM type 3

were ruled out with normal urologic imaging. A few months later, she had an episode of conjunctivitis which was treated with a local antibiotic eye drop, followed by the first bout of severe upper respiratory tract infection which was treated with proper antibiotic therapy. This was followed by similar less severe episodes of respiratory infections, at least four times a year.

Her parents had noted snoring when she was three years old, which led to bilateral adenotonsillectomy. She re-experienced snoring, this time with chronic ear pain and bilateral hearing problems at the end of her fourth year of life. She underwent bilateral myringotomy and tympanostomy to relieve persistent middle ear effusion due to chronic otitis media and also another bilateral adenotonsillectomy, due to re-growth of lymphoid tissue in her tonsils and nonetheless, she continued to endure multiple episodes of productive cough with fever with intermittent episodes of purulent ear discharge. She was treated outpatient with oral antibiotic administration for recurrent sinusitis, and recurrent otitis and was twice treated with a complete IV course ceftazidime according to positive culture for *Pseudomonas aeruginosa* from ear discharge. She was also prescribed intra-nasal corticosteroid spray with a diagnosis of allergic rhinosinusitis, following her second adenotonsillectomy.

Reason for her referral to our clinic was further workup due to unusual recurrence of the URIs. On examination, we noticed sinus tenderness, purulent discharge from nose and serous fluid from her tympanostomy. She was febrile with T: 38.2C ° oral and her lab tests revealed leukocytosis, white blood cells: $15.7 \times 10^3/\mu$ with 75% polymorphonuclear, hemoglobin of 13.5 mg/dl and platelet count of $470 \times 10^3/\mu$. Recurrent sinopulmonary infections mandated a workup to find humoral immunodeficiencies. Serum immunoglobulin levels revealed abnormally high IgM levels with low serum IgG. Anti-tetanus and anti-diphtheria antibody titers were both below the desired levels of 0.1 IU/ml. Her blood group was type A, and anti-B antibody titer was within normal range, and anti-A antibody titers were not detectable.

With a look at other primary immunodeficiencies associated with low serum immunoglobulins, including combined immunodeficiencies, enumeration of lymphocyte subsets using flow cytometry was performed revealing slightly below normal CD8⁺ and CD20⁺ lymphocytes counts, relatively absent CD19⁺ gated CD27⁺ lymphocytes, with a predominance toward CD45⁺ cells, 66%. Overnight incubation of T-cells with phytohaemagglutinin revealed normal expression of CD40 ligand (CD40L) along with control surface

markers of T-cell activation, CD25, and CD69.

Considering secondary causes for recurrent URI, chest computed tomography showed the absence of anatomical abnormalities, foreign bodies, sequestration or fungus balls, showing only diffuse bronchiectasis in bilateral lower lobes. Sweat chloride level was normal, which added to her normal development and thrive, ruled out cystic fibrosis as a common cause of bronchiectasis. Gastroesophageal reflux, swallowing problems and asthma was ruled out with clinical examination and interview.

Due to abnormally high levels of IgM, and low levels of other immunoglobulins, she was diagnosed with hyper IgM syndrome. Due to the absence of relevant family history, and normal surface expression markers of activated T-cells, typical HIGM type 1 with CD40L mutation was unlikely the diagnosis. Parental consanguinity leads to suspicion of autosomal recessive forms of HIGM, and the presence of opportunistic organisms, i.e. *Pseudomonas aeruginosa* led to pre-diagnosis of type 3 HIGM. The CD40 gene was amplified by exon-specific primers which revealed a previously reported mutation in the promoter of CD40 at position -1, T>C, compatible with a previously known mutation in Type-3 Hyper IgM Syndrome (Figure 1).

Her treatment was abruptly started with monthly intravenous immunoglobulin (IVIg) infusions and prophylactic antibiotics, daily trimethoprim-sulfamethoxazole and weekly fluconazole. She hasn't since experienced any other episode of URI, and her tympanostomy tubes were removed. She was closely followed for the emergence of neutropenia, the rise in liver enzymes and early signs of autoimmune or malignant disorders.

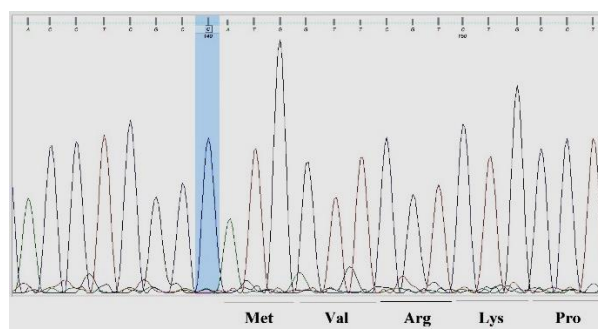


Figure 1. Results of exon amplification of CD40 gene in a six-year-old girl with recurrent pneumonia

Discussion

Type 3 HIGM was first identified in patients presenting with the autosomal recessive mood of

inheritance of HIGM syndrome and absence of known mutations in AID or UNG genes (4). To date, only 7 genetically confirmed reports of HIGM type 3 exist in literature, all from children of consanguineous families (4-7). Up to 70-90% of patients with clinical HIGM have a defect in CD40 ligand (CD154) gene, accounting for the most common subgroup of patients with HIGM, with an X-linked recessive form of inheritance and both CSR deficiency and cellular immunity dysfunction.

CD40/CD40L interaction is mandatory for antigen-dependent initiation of CSR and SHM in B-cells, for induction of maturation of naïve dendritic cells, cross-talk between DCs and lymphocytes and cross-regulation of antigen presenting cells function and B-cell and T-cells function (8). CD40/CD40L is essential for DCs production of IL-12 and IFN- γ necessary for polarization of T-helper 1. This interaction also provides crucial signals for B-cells to commence CSR and mature into memory B-cells, along with DCs maturation and the resulting formation of germinal centers (9). AID and UNG mediate the intricate CSR in tandem, thus have only a minor role in the cascade of events following CD40/CD40L interaction. Class switch defects result in a profound decrease in IgG and IgA levels and humoral immunity deficiency, with increased susceptibility to bacterial infections as a result. Indeed, two or more serious sinopulmonary infections within a year in a child, should raise suspicion for immunodeficiency and mandates proper workup (10), as was performed in our patients. Parental consanguinity and absence of history of the same condition in male relatives of the maternal family suggested an autosomal recessive form of inheritance which is observed more frequently with AID and UNG mutations and less frequently in CD40 defects (2). The key to suspicion of the HIGM type 3 was documented *P. aeruginosa* otitis media which raised suspicion for combined immunodeficiency subtypes of HIGM, i.e., type 1 and 3. *Cryptosporidium parvum* chronic diarrhea is another common opportunistic infections (9), which was absent in our patient.

CD40L is transiently expressed on T-cells and can be induced by overnight incubation of lymphocytes with phytohaemagglutinin, prior to flow cytometry analysis (9). The absence of CD40L on activated lymphocytes with a normal CD40 positive count confirms the diagnosis for the most common subtype of HIGM (type 1) (1), which was not the case for our patient.

Unlike CD40L, CD40 is constitutively expressed on monocytes, macrophages, DCs and on nonimmune cell types, explaining the broad spectrum of manifestations

that result from CD40-CD154 signaling defect (10). CD40 is however not routinely investigated in flow cytometry analyses, and there are reports of normal flow cytometric expression of CD40 in patients with genetically confirmed mutations in CD40 (5).

There is report of successful myeloablative HSCT in one patient with HIGM type 3, but the efficacy of such protocol is under question, considering the inability of HSCT to reconstitute CD40 expression on non-hematopoietic cells (7).

Our patient had HIGM syndrome type 3 which initially presented with upper respiratory tract infections and adenoid hyperplasia. Her history of relapsing adenoid hyperplasia added to the fact that lymphoid hyperplasia and giant germinal centers are by far known to be most common in type 2 HIGM (AID deficiency) (3), made type 3 HIGM hardly a suspicion during initial workup. Otitis media with opportunistic germs and no evidence for X-linked pattern of inheritance shed light at HIGM type 3 as a probable diagnosis.

References

1. Notarangelo LD, Hayward AR. X-linked immunodeficiency with hyper-IgM (XHIM). *Clin Exp Immunol* 2000;120:399-405.
2. Davies EG, Thrasher AJ. Update on the hyper immunoglobulin M syndromes. *Br J Haematol* 2010;149:167-80.
3. Quartier P, Bustamante J, Sanal O, Plebani A, Debre M, Deville A, et al. Clinical, immunologic and genetic analysis of 29 patients with autosomal recessive hyper-IgM syndrome due to Activation-Induced Cytidine Deaminase deficiency. *Clin Immunol* 2004;110:22-9.
4. Ferrari S, Giliani S, Insalaco A, Al-Ghoniium A, Soresina AR, Loubser M, et al. Mutations of CD40 gene cause an autosomal recessive form of immunodeficiency with hyper IgM. *Proc Natl Acad Sci U S A* 2001;98:12614-9.
5. Karaca NE, Forveille M, Aksu G, Durandy A, Kutukculer N. Hyper-immunoglobulin M syndrome type 3 with normal CD40 cell surface expression. *Scand J Immunol* 2012;76:21-5.
6. Kutukculer N, Moratto D, Aydinok Y, Lougaris V, Aksoylar S, Plebani A, et al. Disseminated cryptosporidium infection in an infant with hyper-IgM syndrome caused by CD40 deficiency. *J Pediatr* 2003;142:194-6.
7. Mazzolari E, Lanzi G, Forino C, Lanfranchi A, Aksu G, Ozturk C, et al. First report of successful stem cell transplantation in a child with CD40 deficiency. *Bone*

Adenoid hyperplasia in HIGM type 3

Marrow Transplant 2007;40:279-81.

8. Ma DY, Clark EA. The role of CD40 and CD154/CD40L in dendritic cells. *Semin Immunol* 2009;21:265-72.
9. Lougaris V, Badolato R, Ferrari S, Plebani A. Hyper immunoglobulin M syndrome due to CD40 deficiency: clinical, molecular, and immunological features. *Immunol Rev* 2005;203:48-66.
10. Borte S, von Döbeln U, Hammarström L. Guidelines for newborn screening of primary immunodeficiency diseases. *Curr Opin Hematol* 2013;20:48-54.