

Spontaneous resorption of extruded iliac crest graft in a case of high cervical myelopathy

Kumar R, (M.D.)⁺⁺ Chatleya A,^{*} Mahapatra AK,^{*}

Abstract

A 38 year old male patient presented to us with complaints of parasthesias in all four limbs with spastic quadriparesis. Magnetic resonance imaging of cervical spine revealed central disc herniation at C2-C3 level with significant cord compression. He was operated for C2-C3 Smith-Robinson anterior cervical discectomy. An autogenous tricortical iliac crest graft of 1.5×1.0 cm was snugly fitted into the disc space. Postoperative check X-ray of the cervical spine showed extrusion of the graft. The patient was managed conservatively. Repeat X-ray of the cervical spine after follow-up of 6 weeks showed resorption of the graft. The distinct strategy of management in this case along with a brief review of literature is discussed.

Key words: High cervical myelopathy: Extruded graft: Resorption

Introduction

Anterior cervical discectomy and fusion (ACDF) represents one of the most commonly performed spinal procedures. Graft extrusion is among the more significant complications occurring after ACDF, occurring in approximately 2% patients (1). The migration or dislodgement of these grafts may impinge on surrounding vital anatomic structures or result in a pseudoarthrosis, mandating surgical revision. Because of the low incidence, factors contributing

to graft extrusion are not well known (2). Management strategies in such cases have to be tailored for individual patients depending upon various factors including symptomatology, radiological features and patient factors like age and co-morbid conditions. We report a case of graft extrusion in a single level ACDF which was managed conservatively as patient remained asymptomatic. Follow up x-ray at 6 weeks showed graft resorption.

* Department Of Neurosurgery, Sanjay Gandhi Postgraduate Institute Of Medical Sciences, Lucknow- 226014, India.

++ Correspondence Address : Dr. Raj Kumar Professor and Head, Department of Neurosurgery, Sanjay Gandhi Postgraduate Institute of Medical Sciences, Lucknow-226014, U.P. [INDIA]
E-mail: @gmail.com rajkumar@sgpgi.ac.in

Case report

A 38 year old male patient presented to us with complaints of parasthesias in all four limbs with distal to proximal progression for 6 months. He also had associated spastic quadriparesis with progressive difficulty in walking for 4 months. There was no preceding history of trauma. On examination, tone was increased in all 4 limbs with power in proximal muscle groups 4+/5 and in distal muscle groups 4/5. All reflexes including pectoralis jerk reflex were exaggerated. Magnetic resonance imaging of cervical spine revealed central disc herniation at C2-C3 level with significant canal compression and T2 hyperintense signal changes in the cord. There was associated occipitalization of C1 arch (Fig 1). He was operated for C2-C3 Smith-Robinson anterior cervical discectomy. Since there was no rent in posterior longitudinal ligament, it was not excised. An autogenous tricortical iliac crest graft of 1.5×1.0 cm was snugly fitted into the disc space. Disc space distraction was 3 mm, the graft was inserted with the cortical surface positioned anteriorly and was countersunk 2 mm from the anterior vertebral border. Postoperatively, the parasthesias and feeling of tightness improved. Postoperative check X-ray of the cervical spine, however, showed extrusion of the graft (Fig 2). As the patient was asymptomatic and had no complaints of dysphagia or discomfort in the neck, it was decided to manage the patient conservatively. Meanwhile, the patient remained asymptomatic. Repeat X-ray of the cervical spine after 6 weeks follow up showed resorption of the graft to the size of 4×2 mm (Fig 3).

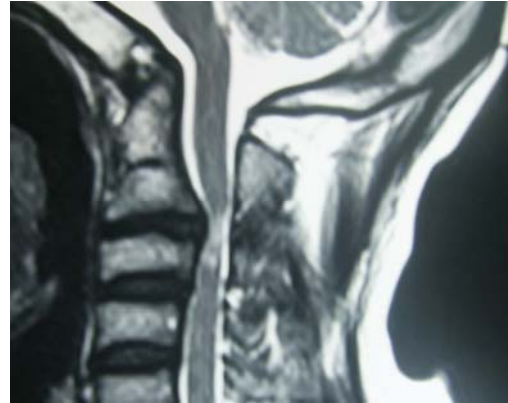


Figure 1: Sagittal T2 weighted MRI showing central disc herniation at C2-C3 level with significant canal compression and T2 hyperintense signal changes in the cord.

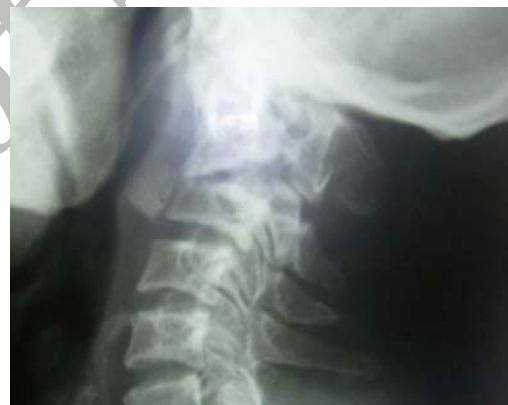

Figure 2: Plain X-ray of the cervical spine in the immediate postoperative period showing extrusion of the graft

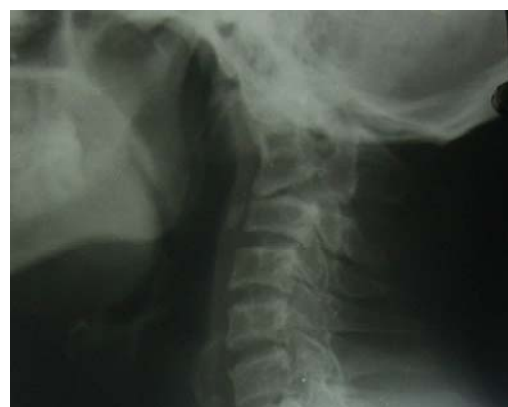

Figure 3: Plain X-ray of the cervical spine after a six-week follow-up showing spontaneous resorption of the graft

Discussion

The success of arthrodesis for anterior cervical fusion depends on several factors, including the number of surgical levels, smoking, proper patient selection, meticulous operative technique, nature of the graft, use of instrumentation and a good postoperative care. The fusion rate reported in literature varies from 90 -95% in most of the series (3,4). Patient's own bone (autograft) is considered best for grafting as it contains bone, osteoinductive bone, morphogenic protein and live osteogenic cells (5). Although plate fixation enhances the fusion rate in multilevel anterior cervical discectomy and fusion (ACDF), debate exists regarding the efficacy of nonplating to rigid plate fixation in one-level ACDF. In general, plate fixation should be reserved for patients unwilling or unable to wear a hard orthosis postoperatively for an extended period of time or for those patients who seek a quicker return to normal activities. Recent studies, however, show that non-plated group of patients undergoing one-level ACDF, had a significantly higher rate of poor outcomes they are requiring revision surgery for non-union, kyphosis, graft extrusion and graft collapse with foraminal stenosis as compared to those who in addition also had a rigid plate fixation (6).

Graft extrusion is a common problem occurring after ACDF, irrespective of the technique used. However, it appears to be less common with Cloward's procedure as compared to other techniques (7). There is a paucity of literature examining the factors commonly associated with this problem or explaining how to rectify it (1). The extruded graft causes a

significant discomfort in the neck along with dysphagia mandating its removal in most of the cases. The options available then include either removal of the graft or replacement of the graft along with anterior cervical plating. As the patient reported in our case was asymptomatic, it was decided to manage the patient conservatively. Review of the literature suggests that this strategy has not been reported before. The patient remained asymptomatic and X-ray of the cervical spine done after 6 weeks showed resorption of the graft. Thus, in selective cases, graft extrusion can be managed conservatively with serial follow-ups. A higher location of the graft could be a favorable factor for conservative management as the lateral compartment of the neck is comparatively wider at this level leading to decreased compression over the oesophagus. The size of the graft and other factors affecting resorption of the extruded graft need to be analyzed further.

References

1. Fountas KN, Kapsalaki EZ, Nikolakakos LG, Smisson HF, Johnston KW, Grigorian AA et al. Anterior cervical discectomy and fusion associated complications. *Spine* 2007; 32(21): 2310-2317.
2. Wang JC, Hart RA, Emery SE, Bohlman HH. Graft migration or displacement after multilevel cervical corpectomy and strut grafting. *Spine* 2003; 28(10): 1016-1022.
3. Bosacco DN, Berman AT, Leuenberg RJ, et al. Surgical results in anterior cervical discectomy and fusion using a counter sunk

- interlocking autogenous iliac bone graft. *Orthopedics* 1992; 15: 923-925.
4. Parthiban JK, Singhanian BK, Ramani PS. A radiological evaluation of allografts (ethylene oxide sterilized cadaver bone) and autografts in anterior cervical fusion. *Neurol India* 2002; 50:17-22.
 5. Wood EG, Hanley ENJ. Types of anterior cervical grafts. *Orthop Clin North Am* 1992; 23: 475-486.
 6. Mobbs RJ, Rao P, Chandran NK. Anterior cervical discectomy and fusion: analysis of surgical outcome with and without plating. *J Clin Neurosci* 2007; 14(7):639-42.
 7. Cloward RB. The anterior approach for removal of ruptured cervical discs. *J Neurosurg* 1958; 5: 602-616.

Archive of SID