

## ORIGINAL ARTICLE

# BOTULINUM TOXIN A (BTX-A) FOR TREATMENT OF PALMAR HYPERHIDROSIS

Haydeh Ghaninejad MD\*, Morteza Heidari MD\*\*

\*Department of Dermatology, Razi Hospital, Tehran University of Medical Sciences, Tehran, Iran

### Abstract

**Background-**Palmar hyperhidrosis is a fairly common disease with an unknown etiology. Some treatment modalities have shown benefits, the most recent of which is the injection of botulinum toxin A (BTX-A). We tried to test the beneficial effects of BTX (Dysport) in Iranian patients.

**Methods-**Fifteen volunteers with severe palmar hyperhidrosis, diagnosed by iodine starch test, were enrolled in the study. Employing a standardized scheme, Dysport was injected intradermally into the palmar aspect of patients' dominant hands. The distal parts of the non-dominant hands were injected by normal saline as control. Follow-up was performed using iodine starch test. Wilcoxon signed rank test was used for comparison between the cases and controls.

**Results-**Satisfactory response to treatment was achieved in 13 out of 15 patients. Comparing the cases with the controls, Dysport showed a significant beneficial effect ( $p < 0.001$ ). Weakness of handgrip was seen in 13 patients.

**Conclusion-**We suggest using Dysport in the treatment of selected cases of severe palmar hyperhidrosis.

**Keywords** • Hyperhidrosis • botulinum toxin A (Dysport)

### Introduction

Localized palmar hyperhidrosis is a common disease with an unknown etiology that is usually worsened by emotional stress. Disturbance in personal, social and occupational functions is frequently seen in severe cases. Involved skin is vulnerable to dermatitis and various secondary infections. Several kinds of treatment modalities including application of topical agents (acid, base and metal salts), systemic drugs such as anticholinergics, surgery (sympathectomy) and iontophoresis have been proposed to control the disease.<sup>1</sup> All of the above-mentioned treatments are accompanied by unwanted complications, have temporary benefits and are time consuming.<sup>2</sup> Treatment of hyperhidrosis with botulinum toxin A (BTX-A) is an easy and recent mode of therapy. BTX-A, which has two available commercial products (Botox and Dysport) blocks irreversibly the release

of acetylcholine from presynaptic membranes.<sup>3</sup> Considering the incomparable and unpredictable effects of these two products<sup>4</sup>, we studied the efficacy of Dysport in the treatment of palmar hyperhidrosis in our center.

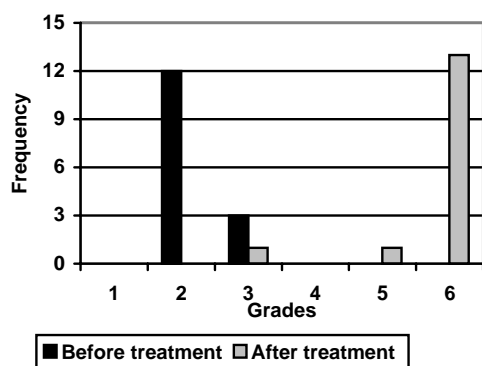
### Materials and Methods

Fifteen volunteer patients with informed consents (13 males) aged between 19 to 30 years ( $24.4 \pm 9.6$ ) with severe palmar hyperhidrosis, resistant to all conventional treatments, were recruited in the Department of Dermatology, Razi Hospital, Tehran, Iran, from 1999 to 2000.

Severe hyperhidrosis was defined as being wet with perspiration for more than 5 days a week or sweat dripping from the hands during usual activities. Inclusion criteria for the study were: 1) severe hyperhidrosis, 2) previous treatment (at least 3 months of topical therapy without any improvement), and 3) duration of the disease of more than 10 years. Exclusion criteria were considered as: 1) age less than 18 years, 2) pregnancy,

\*Correspondence: M. Heidari MD, Department of Dermatology, Razi Hospital, Tehran, Iran. E-mail: [morteza\\_hm@yahoo.com](mailto:morteza_hm@yahoo.com).

## Botulinum Toxin A for Treatment of Palmar Hyperhidrosis



**Figure 1.** Patients' response to treatment according to the presented grading system.

3) any recent systemic disease, and 4) application of any kind of antiperspirant agents.

Before injection of Dysport, the diagnostic iodine starch tests (with 2% iodine alcohol and rice starch) were performed. The drug was diluted with 10 milliliters of normal saline before injection.<sup>5</sup> Employing a standardized scheme (four injections in a 2x2 cm of skin), 15 mouse units (mU) of the drug was intradermally injected<sup>6</sup> into each 4 cm<sup>2</sup> of the palm of the dominant hand and the proximal half of the palm of the other hand. The distal part of the latter was injected with sterile normal saline<sup>5</sup> as control. In order to decrease the pain, patients held an ice bag in their hands 30 minutes before the injection. Using the iodine starch test and the degree of patients' satisfaction (Figure1), the patients were followed-up monthly. Wilcoxon signed rank test was used for comparison of the results.

### Results

Comparing the response to the intervention in the cases and controls, Dysport showed satisfactory results in the treated areas ( $p < 0.007$ ). In 13 (86.7%) patients, the hands remained completely dry and the control areas showed no response. Although iodine starch test showed patchy response in 2 (13.3%) of the remaining cases, patients were not satisfied with the results (Figure 2). The onset of response to Dysport was between 2 and 10 days ( $3.3 \pm 2.5$  days) and the peak of response was seen between 3 and 12 days ( $5 \pm 2.9$  days) after the intervention. The only significant adverse effect was weakness of handgrip which occurred in 13 (86.7%) patients. The onset of weakness was seen between 2 and 17 days ( $6.4 \pm 3.8$  days) after the drug injection. The

Grading	Description
1	Always wet and dripping
2	Always wet dripping during stress
3	Always wet
4	Occasionally wet and dripping
5	Only occasionally wet
6	Dry

patients achieved full muscle power after 14 to 42 days ( $26.1 \pm 2.7$ ).

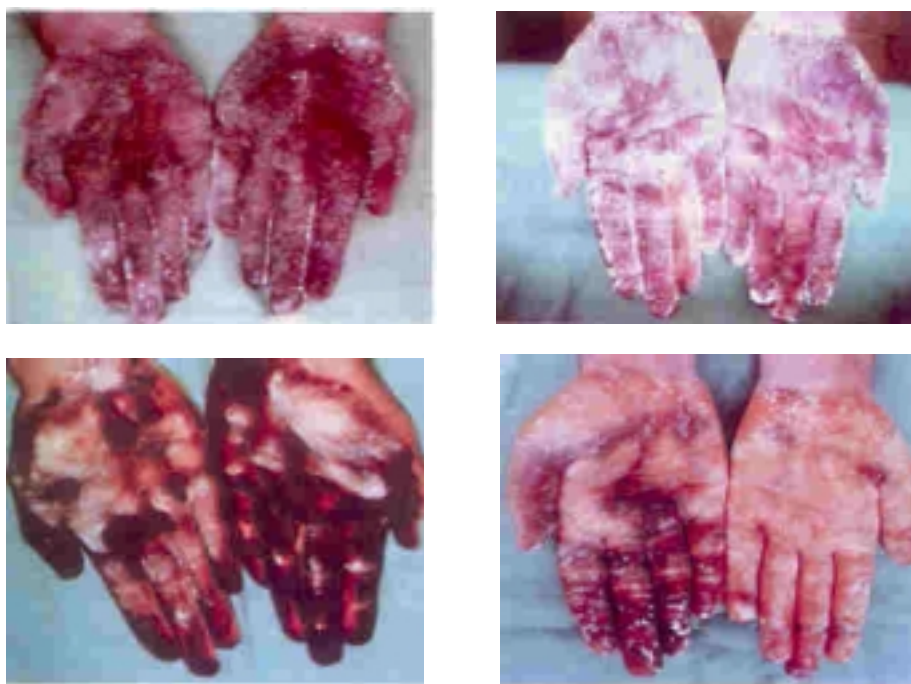
### Discussion

Research on BTX-A in treating hyperhidrosis began in 1997.<sup>7,8</sup> The exact dose of the drug, definite route of injection, extent of adverse effects and recovery time after treatment have not been described in published articles.<sup>1-3</sup> The first trial on 11 patients with palmar hyperhidrosis in 1997, showed no satisfactory response to the injection of 120 mU of Dysport.<sup>7</sup> In other trials, axillary hyperhidrosis was improved after using Dysport.<sup>9-12</sup> The maximum reported dose of injection is 400 mU which has been applied for one axillary area.<sup>12</sup> We used the dose of 500 mU for every dominant hand's palm and a half of the other palms.

The only reported side effect of BTX-A injection is weakness of handgrip, a side effect that was seen in most of our patients. Compared to previous reports, weakness of handgrip was significantly high in our patients. The large dose of injected drug may be a probable cause of such a high-incidence of this adverse effect. In conclusion, we suggest using the Dysport injection in the treatment of severe palmar hyperhidrosis, especially when the other modalities fail to show any satisfactory result. Also, using lower doses of the drug is recommended to decrease the incidence of handgrip weakness.

### Acknowledgment

We would like to thank Dr. Keramatollah Noori, Dr. Seyed-Hasan Tabatabaei-Nejad and Dr. Mostafa Mirshmas-Shahshahani for their invaluable support.



**Figure 2.** Failure (left) and success (right) in treatment in our patients before Dysport injection (above) and one month after (below) using iodine starch test.

## References

- 1 Rook A, Wilkinson DS, Ebling FJG. *Rook/ Wilkinson/ Ebling Textbook of Dermatology*. 6th ed. Oxford: Blackwell Science; 1998: 1992-3.
- 2 Arndt KA. *Cutaneous Medicine and Surgery*. Philadelphia: WB Saunders; 1996: 1314-7.
- 3 Martindale. *The extra pharmacopoeia*. 1996; 2: 1516-8.
- 4 Madalinski M. Botox and Dysport are distinct. *Endoscopy*. 2000; **32**: 502-3.
- 5 Naumann M, Hofman U, Bergmann I, Hamm H, Toyka KV, Reinerr K. Focal hyperhidrosis: effective treatment with intracutaneous botulinum toxin. *Arch Dermatol*. 1998; **134**: 301-2.
- 6 Shelley WB, Talanin NY, Shelley EDE. Botulinum toxin therapy for palmar hyperhidrosis. *Am Acad Dermatol*. 1998; **38**: 222-9.
- 7 Shnider P. Double-blind trial of botulinum A toxin for the treatment of focal hyperhidrosis of the palm. *Br J Dermatol*. 1997; **136**: 548-52.
- 8 Naumann M. Botulinum toxin for palmar hyperhidrosis. *Lancet*. 1997; **349**: 252.
- 9 Madalinski M. Botulinum toxin: a possible new treatment for axillary hyperhidrosis. *Clin Exp Dermatol*. 1996; **21**: 276-8.
- 10 Shnider P, Binder M, Kittler H, et al. A randomized, double-blind, placebo-controlled trial of botulinum A toxin for severe axillary hyperhidrosis. *Br J Dermatol*. 1999; **140**: 677-80.
- 11 Heckmann M, Breit S, Ceballos-Baumann A, Schaller M, Plewig G. Side controlled intradermal injection of botulinum toxin A in recalcitrant hyperhidrosis. *J Am Acad Dermatol*. 1999; **41**: 987-90.
- 12 Heckmann M, Breit S, Ceballos-Baumann A, Schaller M, Plewig G. Axillary hyperhidrosis. *Hautarzt*. 1998; **49**: 101-3.