

Original Article

VALIDATION OF CAROTID DUPLEX AND POWER M-MODE TRANSCRANIAL DOPPLER FOR DETECTION OF INTERNAL CAROTID ARTERY STENOSIS

Kavian Ghandehari MD^{•*}, Maher Saqqur MD^{**}, Ashfaq Shuaib MD^{**}

Background – Carotid duplex ultrasound (CDU) is routinely used for detection of extracranial internal carotid artery (EICA) stenosis in stroke patients. Power M-mode transcranial Doppler (PMD-TCD) is a new technology designed for studying intracranial vessels. This prospective study was performed for validation of CDU versus digital subtraction cerebral angiography (DSA) and PMD-TCD versus CDU in detection of EICA stenosis.

Methods – Part I: Validation of CDU versus DSA in 50 stroke patients (100 carotids) admitted to Walter Mackenzie Center, Canada in 2003. All of the CDUs were performed by a sonographer with an HP Sono 5500 device (USA) and a 13-MHz linear probe. The degree of EICA stenosis was measured using DSA according to North American symptomatic carotid endarterectomy trial (NASCET) method by another neuroradiologist blinded to CDU results.

Part II: Validation of PMD-TCD versus CDU in another group of 50 patients (100 carotids) with stroke. All PMD-TCD studies were performed with a TCDM100 device (Spencer, USA) and a 2-MHz probe by a sonographer blinded to CDU results.

Results – Part I: Compared with DSA, CDU had a sensitivity of 96%, specificity of 100%, positive predictive value (PPV) of 100%, and negative predictive value (NPV) of 82% in detecting EICA stenosis of 50% and over. CDU versus DSA confirmed EICA stenosis of 70% and over with a sensitivity of 88%, specificity of 95%, PPV of 96%, and NPV of 87%.

Part II: Compared with CDU, PMD-TCD had a sensitivity of 45%, specificity of 94%, PPV of 50%, and NPV of 93% for detection of EICA-stenosis of 50% and over. PMD-TCD, when compared with CDU, confirmed EICA-stenosis of 70% and over with a sensitivity of 43%, specificity of 99%, PPV of 75% and NPV of 96%.

Conclusion – In our center, CDU is a highly reliable noninvasive diagnostic tool for detection of EICA stenosis. PMD-TCD of carotid has a moderate sensitivity for detection of EICA stenosis and is not recommended as a screening test for this purpose.

Archives of Iranian Medicine, Volume 7, Number 3, 2004: 182 – 185.

Keywords: Carotid • transcranial Doppler • ultrasound

Introduction

The value of carotid duplex ultrasound (CDU) as a diagnostic tool prior to carotid endarterectomy is well established. In our center (Walter Mackenzie Center, Canada), whenever the results of CDU and

magnetic resonance angiography are congruent, vascular surgeons make decisions about carotid endarterectomy without performing digital subtraction angiography (DSA).¹

Power M-mode transcranial Doppler (PMD-TCD) is a new technology designed for intracranial vessels studies. This technology calculates a PMD flow signal with a single gate TCD spectrogram.² PMD generates intravascular color signals from the reflected echo amplitude depending mainly on the density of the red blood cells. The flow is displayed in the PMD image with red color depicting the flow toward the probe and blue color depicting the flow away from it.² The flows of

Authors affiliations: *Department of Neurology, Birjand University of Medical Sciences, Birjand, Iran, **Department of Neurology, University of Alberta, Edmonton, Canada.

Corresponding author and reprints: Kavian Ghandehari, MD, Neurology Division, Vali-e-Asr Hospital, Ghaffari St., Birjand, Iran. Telefax: +98-561-4430076, E-mail: kavianghandehari@yahoo.com.

multiple vessels simultaneously appear in the PMD image. PMD-TCD has been very useful in correct selection of intracranial arteries. PMD-TCD has served on the diagnosis of intracranial arterial stenosis and vasospasm and the monitoring of microemboli with high accuracy.² Few studies have been conducted on usefulness of PMD-TCD as a screening test for detecting extracranial internal carotid artery (EICA) stenosis.³ This prospective study was performed for validation of CDU versus DSA and PMD-TCD versus CDU in detection of EICA stenosis.

Patients and Methods

This validation study was conducted in Walter Mackenzie Center, Canada in 2003.

Part I

The results of 100 DSAs of 50 consecutive stroke patients who had already undergone CDU were compared with the results of their CDU. All of the CDUs were performed by a sonographer. DSA was performed by selective catheterization of common carotid artery (CCA) to enhance images. Measurements were made on the angiographic images by another neuroradiologist blinded to CDU results. The degree of stenosis was measured from the ratio of the luminal diameter of EICA at the site of maximum stenosis to the luminal diameter of distal EICA according to North American symptomatic carotid endarterectomy trial (NASCET)⁴ method.

All of the CDUs were performed by a sonographer with an HP Sono 5500 device (USA) and a 13-MHz linear probe. The CDU criteria for EICA stenosis of 50% or over were peak systolic velocity (PSV) ≥ 125 cm/s and spectral broadening.⁵ The CDU criteria for EICA stenosis of 70% or over were PSV ≥ 325 cm/s, end diastolic velocity ≥ 110 cm/s, and ICA/CCA PSV ratio ≥ 4 .^{5,6} All of the DSAs were performed during the first 3 days after CDU.

Part II

The results of 100 PMD-TCDs in another group of 50 stroke patients were compared with the results of their CDU. All of the PMD-TCD studies were performed within 1 day of CDU with a TCD100M device (Spencer, USA) and a 2-MHz probe by another sonographer blinded to CDU results. During CCA insonation, the probe was

placed at the lower third of the SCM muscle and aimed superomedially with a depth setting of 25 to 45 mm. The proximal EICA was insonated by holding the probe at the upper level of thyroid cartilage adjacent to the anterior border of SCM muscle and aiming it superomedially.⁷ The probe was placed in the angle of the jaw with superomedial aiming for distal EICA insonation.⁷ The depth was set within the ranges of 25 to 45 mm and 45 to 65 mm for proximal and distal EICA insonation, respectively. PMD has served as a flow signal guide for arterial segment selection in spectral display. A low resistance flow signal with continuous flow during systolic and diastolic phases was characteristic in detection of EICA. A high resistance flow signal with absent diastolic flow was used in identification of external carotid artery and CCA.² Ophthalmic arteries were insonated through transorbital window for direction of the flow at a depth of 40 to 60 mm. Our PMD-TCD criteria for EICA stenosis of 50% and over were PSV ≥ 125 cm/s and proximal EICA/CCA PSV ratio ≥ 1.8 ⁵ while that for EICA stenosis of 70% and over were proximal EICA/CCA PSV ratio ≥ 4 and retrograde flow in the ipsilateral ophthalmic artery.^{8,9} EICA occlusion was considered as an exclusion criterion in parts I and II of the study. Statistical agreement for the degree of EICA stenosis in CDU versus DSA and that in PMD-TCD versus CDU was assessed with Spearman's rank correlation coefficient.⁸

Results

Part I

EICA stenosis was detected in 60% of CDUs and 64% of DSAs. CDU confirmed EICA stenosis of 50% and over with a sensitivity of 96%, specificity of 100%, positive predictive value (PPV) of 100%, and negative predictive value (NPV) of 82% (confidence interval [CI]: 95%). Compared with DSA, CDU detected EICA stenosis of 70% and over with a sensitivity of 88%, specificity of 95%, PPV of 96%, and NPV of 87% (CI: 95%).

Part II

EICA stenosis was detected in 18% of CDU and 14% of PMD-TCD studies. Compared with CDU, PMD-TCD confirmed EICA stenosis of 50% and over with a sensitivity of 45%, specificity of 94%, PPV of 50%, and NPV of 93% (CI: 95%).

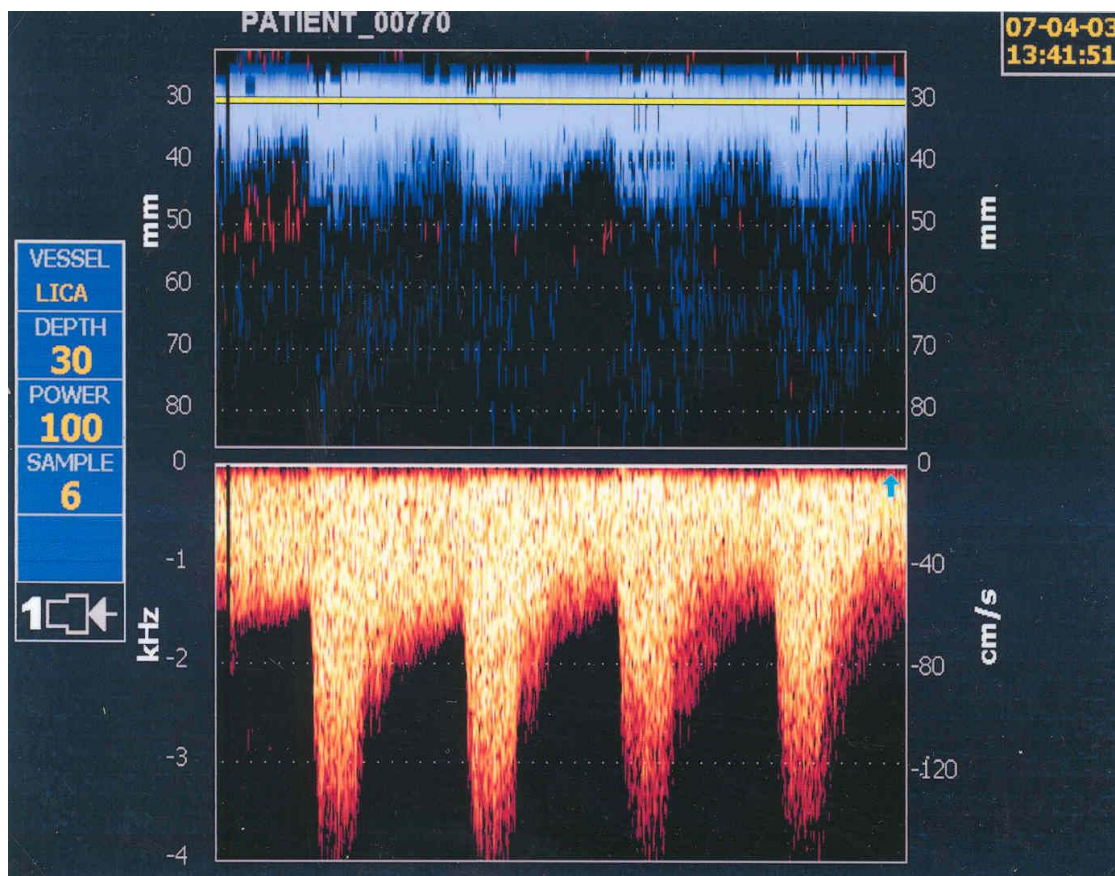


Figure 1. A PMD-TCD signal of EICA with $\geq 70\%$ stenosis.

PMD-TCD, when compared with CDU, detected EICA stenosis of 70% and over with a sensitivity of 43%, specificity of 99%, PPV of 75%, and NPV of 96% (CI: 95%).

Figure 1 shows a PMD-TCD signal from an EICA stenosis of 70% and over.

Discussion

The very high accuracy of CDU in our center in comparison with the gold standard (DSA)¹⁰ is similar to other validation results in North America.^{11, 12} In fact, the CDU criteria for grading EICA stenosis in 10% intervals is reliable and accurate.⁸ This high accuracy was the main reason why we compared PMD-TCD as a screening test with CDU. Part I of the study was carried out in patients in whom DSA was indicated. Therefore, the frequency rate of EICA stenosis in part I was higher than that in part II. The internal picture of the vessel could be observed only by color, color/power, and duplex ultrasound technologies. Since PMD-TCD is not able to show the internal

vascular view, cursor angle correction is not possible at the site of vascular stenosis using this technology.¹³ The modest sensitivity of PMD-TCD in determination of EICA stenosis could be due to the absence of cursor angle correction. Few studies have been conducted on usefulness of PMD-TCD in detection of EICA stenosis. PMD-TCD had a moderate sensitivity in screening of EICA stenosis in one study.³ Since in another study,⁹ the reversed ophthalmic artery flow sign was 100% specific and 79% sensitive for detecting EICA stenosis of 95% and over, it was used as the criterion in our study. Although PMD-TCD had a very high specificity and NPV, it showed a moderate sensitivity and PPV for screening of EICA stenosis. A similar validation study of PMD-TCD versus CDU was performed by Spencer et al using proximal/distal EICA mean flow velocity ratio.¹⁴ The ratios higher than 1.4 and 1.6 were defined as PMD-TCD criteria of EICA stenoses of 40% to 59% and 60% to 79%, respectively. PMD-TCD had a sensitivity of 73% and 94% in detecting EICA stenoses of 40% to 59% and 60% to 79%, respectively. Since

we recorded the proximal and distal EICA mean flow velocities in our study, we also analyzed our data using the above criteria in Spencer's study; however, the sensitivity and PPV of PMD-TCD were not improved.

Conclusion

In our center, CDU has a very high accuracy in detection of EICA stenosis. PMD-TCD has a moderate sensitivity and PPV is not recommended as a screening test for EICA stenosis.

Acknowledgment

This study was funded through a sabbatical grant from the Research Deputy of the Iranian Ministry of Health and Medical Education.

References

- 1 Golledge J, Wright R, Pugh N, Lane IF. Color-coded duplex assessment alone before carotid endarterectomy. *Br J Surg.* 1996; **83**: 1234 – 1237.
- 2 Moehring M, Spencer MP. Transcranial power M-mode Doppler ultrasound for locating blood flow and tracking microemboli. *Stroke.* 2001; **32**: 24 – 28.
- 3 Steinke W, Ries S, Artemis N, Schwartz A, Hennerici M. Power Doppler imaging of carotid artery stenosis. Comparison with color Doppler flow imaging and angiography. *Stroke.* 1997; **28**: 1981 – 1987.
- 4 Barnett HJ, Taylor DW, Eliasziw M, et al. Benefit of carotid endarterectomy in patients with symptomatic moderate or severe stenosis. North American Symptomatic Carotid Endarterectomy Trial Collaborators. *N Engl J Med.* 1998; **339**: 1415 – 1425.
- 5 Alexandrov AV, Vital D, Brodie DS, Hamilton P, Grotta JC. Grading carotid stenosis with ultrasound. An interlaboratory comparison. *Stroke.* 1997; **28**: 1208 – 1210.
- 6 Koga M, Kimura K, Minematsu K, Yamaguchi T. Diagnosis of internal carotid artery stenosis greater than 70% with power Doppler duplex sonography. *AJNR Am J Neuroradiol.* 2001; **22**: 413 – 417.
- 7 Santalucia P, Feldmann E. The basic transcranial Doppler examination technique. In: Babikian VL, Wechsler LR, eds. *Transcranial Doppler Ultrasonography.* 2nd ed. Boston: Butterworth-Heinemann; 1999: 15.
- 8 Filis KA, Arko FR, Johnson BL, et al. Duplex ultrasound criteria for defining the severity of carotid stenosis. *Ann Vasc Surg.* 2002; **16**: 413 – 421.
- 9 Saqqur M, Demchuck A, Schebel M, et al. Reversed ophthalmic artery flow is very specific for critical ICA stenosis or occlusion using power M-mode Doppler. *Stroke.* 2002; **33**: 37 – 40.
- 10 Dean N, Saqqur M, Shuaib A, et al. Does a dedicated stroke ultrasound service improve reliability of Doppler in carotid disease? *J Neuroimaging.* 2003; **13**: 177 – 179.
- 11 Golledge J, Ellis M, Sabharwal T, Sikdar T, Davies AH, Greenhalgh RM. Selection of patients for carotid endarterectomy. *J Vasc Surg.* 1999; **30**: 122 – 130.
- 12 Eliasziw M, Rankin RN, Fox AJ, Haynes RB, Barnett HJ. Accuracy and prognostic consequences of ultrasonography in identifying severe carotid artery stenosis. North American Symptomatic Carotid Endarterectomy Trial (NASCET) Group. *Stroke.* 1995; **26**: 1747 – 1752.
- 13 Claudon M, Waininger D, Briancon S, Pesque P. Power Doppler US: evaluation of the morphology of stenoses with a flow phantom. *Radiology.* 2001; **218**: 109 – 117.
- 14 Spencer M, Popa VN, Lion L. Power M-mode and transcranial Doppler to directly detect internal carotid artery stenosis. *J Neuroimaging.* 2003; **13**: 180 – 185.