

## Original Article

## ND-YAG LASER APPLICATION IN PREMACULAR SUBHYALOID HEMORRHAGE

Mehdi Nili-Ahmadabadi MD\*, Ali-Reza Lashay MD, Reza Karkhaneh MD, Masood-Reza Manaviat MD, Ali Amini MD, Adel Razaghi MD, Zahra Alami MD

**Background** – Premacular subhyaloid hemorrhage is one of the etiologies of sudden visual loss. It may be due to vascular or blood abnormalities or Valsalva retinopathy. Spontaneous absorption of blood may take months and result in macular complications and permanent impairment of vision. Posterior hyaloidotomy by Nd-YAG laser is an outpatient procedure which may obviate the need for more complex surgical interventions. This study evaluates the success of this approach in patients with premacular subhyaloid hemorrhage of different etiologies.

**Methods** – In this interventional case-series study, 12 eyes of 12 patients with premacular subhyaloid hemorrhage were enrolled. All patients had a comprehensive ocular examination before the operation and color fundus photographs were obtained. Fluorescein angiography was performed when necessary. Hyaloidotomy was performed using Nd-YAG laser. Main outcome measures were: success rate in hyaloidotomy (based on release of blood into the vitreous cavity and its subsequent absorption) and improvement in visual acuity and possible complications.

**Results** – Twelve eyes of 12 patients (16.7% males and 83.3% females) with premacular subhyaloid hemorrhage were enrolled. The mean age of the patients was  $48.5 \pm 10.33$  years. The predisposing factor was diabetic retinopathy in eight (66.7%), macroaneurysm (due to hypertension) in one (8.3%), and Valsalva retinopathy in three (25%). Hyaloidotomy was successful in all (100%) of the patients and the trapped blood was released into the vitreous cavity and absorbed within 6 to 16 (average = 9) days. The range of preoperative visual acuity was hand motions to counting fingers at 3 meters which improved from 20/50 to 20/20 postoperatively. Compared with those with vascular pathologies, visual improvement was best in the patients with Valsalva retinopathy. No complications were observed during their average follow-up of 24.5 (range: 8 to 72) months.

**Conclusion** – Nd-YAG laser hyaloidotomy in premacular subhyaloid hemorrhage is a simple, inexpensive outpatient procedure which results in rapid visual recovery and is relatively safe. Further controlled clinical trials are recommended.

*Archives of Iranian Medicine, Volume 7, Number 3, 2004: 206 – 209.*

**Keywords:** Nd-YAG laser • subhyaloid hemorrhage

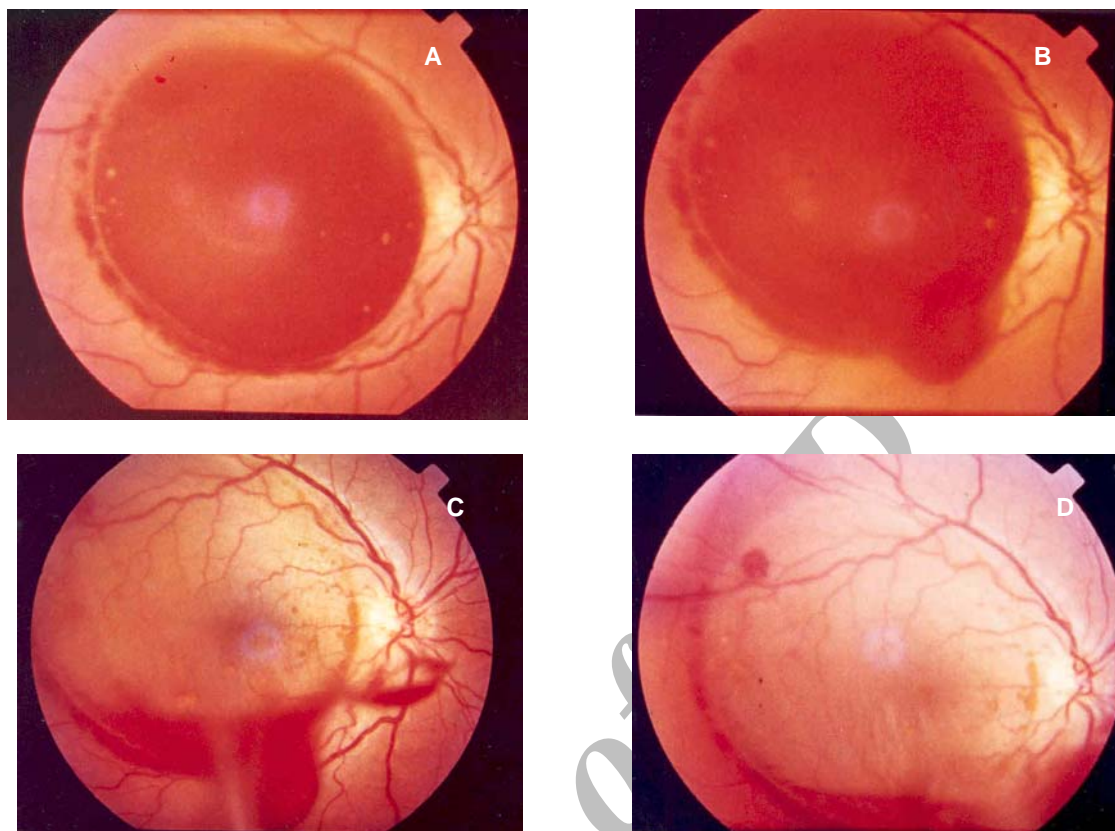
### Introduction

Premacular subhyaloid hemorrhage may occur in retinal vascular disorders such as proliferative diabetic retinopathy, branch retinal vein occlusion, macroaneurysm, and age-related macular degeneration; in hematological disorders such as leukemia and chemotherapy-

induced pancytopenia; following laser *in situ* keratomileusis (LASIK) because of rapid release of the microkeratome vacuum pressure; or after retinal vascular rupture associated with physical exertion (Valsalva retinopathy).<sup>1-6</sup> Sudden rise in intraabdominal or intrathoracic pressure may cause a rapid increase in venous pressure with spontaneous rupture of superficial retinal capillaries. Valsalva retinopathy often occurs in healthy young adults as a result of heavy lifting, straining on toilet, vomiting, coughing, labor, automobile air-bag related trauma, or even vigorous sexual activity.<sup>3,7</sup> Spontaneous resorption

**Authors affiliations:** Department of Ophthalmology, Eye Research Center, Tehran University of Medical Sciences, Tehran, Iran.

•Corresponding author and reprints: Mehdi Nili-Ahmadabadi, MD, Development of Ophthalmology, Farabi Hospital, Tehran, Iran. Fax: +98-21-5409092, E-mail: ma\_nili@yahoo.com.



**Figure 1.** (A) Before laser, (B) four minutes after laser, (C) five days after laser (absorption was incomplete), and (D) nine days after laser.

of the blood entrapped in subhyaloid space may take months and may result in permanent visual impairment due to pigmentary macular changes or formation of epiretinal membranes<sup>8</sup> and toxic damage to the retina due to prolonged contact with hemoglobin and Iron.<sup>4</sup> Different techniques have been used to treat premacular hemorrhage. These include pars plana deep vitrectomy<sup>8-10</sup> and pneumatic displacement of hemorrhage by intravitreal injection of gas and tissue plasminogen activator.<sup>11</sup> Puncturing the posterior hyaloid face with Nd-YAG<sup>12-14</sup> or green argon laser<sup>15</sup> is a safe and easy alternative for releasing the entrapped subhyaloid blood into the vitreous. Consequently, the obscured macular area is cleared and resorption of blood cells is facilitated.<sup>12-14</sup> In this study, we describe 12 patients with premacular subhyaloid hemorrhage who were successfully treated by Nd-YAG laser hyaloidotomy.

### Materials and Methods

This interventional case-series included 12 eyes of 12 patients with premacular subhyaloid

hemorrhage enrolled from 1996 to 2003 in Farabi Eye Hospital, Tehran, Iran. Pretreatment and posttreatment examinations included best corrected visual acuity, slit lamp microscope examination, intraocular pressure, and funduscopy. Fundus photographs were taken to measure the size of the subhyaloid hemorrhage by comparing with optic disc dimensions. After giving enough explanation to the patients and taking their consent. Tropicamide eye drop was applied to dilate the pupil and tetracaine (0.5%) was dropped for topical anesthesia. Nd-YAG laser (coherent 9,900 Nidek YC 1,600) was applied through a slit lamp and a Goldman three-mirror (Volk) lens with an average total energy of 80 mJ (range: 15 to 180 mJ).

Laser was applied to the lowermost dependent part of the blood-containing subhyaloid pocket in order to enhance the blood release process and better protection of the underlying retina. Patients were followed up at 2<sup>nd</sup> day, 1<sup>st</sup> week, 2<sup>nd</sup> week, and at the end of the study.

The main outcome measures including success rate in performing hyaloidotomy, releasing the entrapped blood into the vitreous cavity and its

resorption, postoperative improvement in visual acuity, and postoperative complications were recorded and analyzed.

## Results

Twelve eyes of 12 patients were enrolled. These included 10 females (83.3%) and 2 males (16.7%), with an average age of  $48.5 \pm 10.33$  years (range: 31 to 67 years). Eight (66.7%) had diabetic retinopathy, one (8.3%) had a retinal macroaneurysm due to hypertension, and 3 (25%) were diagnosed with Valsalva retinopathy as the main cause of their premacular hemorrhage. The mean pretreatment hemorrhage measured  $4 \pm 1.7$  disc diameters.

Nd-YAG laser hyaloidotomy was successful in all cases and the trapped blood was released into the vitreous cavity and resorbed after a mean period of 9 (6 to 16) days.

Preoperative visual acuity in the affected eyes of these patients ranged from hand motion to counting fingers at 3 meters, which was improved from 20/50 to 20/20 postoperatively. Patients with the diagnosis of Valsalva retinopathy achieved normal vision after treatment; this improvement was better compared with those with either diabetic or hypertensive retinopathy (Figure 1). Table 1 summarizes patients' characteristics and postoperative results. No special complication including increase in intraocular pressure, retinal and choroidal hemorrhage, macular hole, or retinal break formation was noted during the average follow-up of 24.5 months (range: 8 to 72 months).

## Discussion

Subhyaloid hemorrhage is defined as a localized detachment of vitreous from the retina caused by the accumulation of blood, which can lead to sudden and severe loss of vision when it takes place in the macular area.<sup>1-3</sup> Until recently, the application of Nd-YAG laser in the posterior segment was limited to releasing tractional vitreous bands and other pathologic vitreous attachments, especially in cases with tractional retinal detachment due to diabetic or sickle-cell retinopathy and other complicated retinal detachments.<sup>14, 16, 17</sup> The high levels of energy (up to 1000 mJ) applied to treat these conditions could result in serious complications such as retinal and/or choroidal hemorrhage and retinal perforation.<sup>14, 18</sup> One of the recent indications for the application of Nd-YAG laser in posterior segment is to treat premacular subhyaloid hemorrhage which itself is a consequence of retinal vascular diseases such as diabetic retinopathy, hematological disorders such as leukemia and chemotherapy induced pancytopenia,<sup>5</sup> Valsalva retinopathy,<sup>12-14</sup> or LASIK because of rapid release of the microkeratome vacume pressure.<sup>6</sup>

In this study, we performed posterior hyaloidotomy using Nd-YAG laser in 12 patients with premacular subhyaloid hemorrhage. In all cases, the trapped blood was released into the vitreous and resorbed within 6 to 16 (average: 9) days. All patients had at least 4 lines (Snellen chart) improvement in their visual acuity within 16 days of the operation. Overall, visual improvement

**Table 1.** Summarized patients, characteristics and postoperative results.

Patients	Sex/Age (yr)	OD-OS	Diagnosis	Total energy (mJ)	Duration of hemorrhage (d)	Visual acuity	
						Before treatment	After 2 weeks
1	F/49	OD	PDR	120	18 d	20/400	20/50
2	F/44	OD	PDR	40	15 d	5/200	20/40
3	F/48	OS	PDR	180	3 d	FC 50 cm	20/50
4	M/35	OS	Valsalva retinopathy	25	1d	FC 20 cm	20/20
5	F/60	OD	Macroaneurysm (hypertensive)	30	5 d	FC 30 cm	20/50 (12 d)
6	M/42	OD	PDR	110	6 d	FC 50 cm	20/30
7	F/57	OD	PDR	100	4 d	HM	20/40
8	F/44	OS	Valsalva retinopathy	15	7 d	HM	20/20
9	F/56	OD	PDR	120	5 d	FC 1 m	20/30
10	F/49	OD	PDR	130	3 d	FC 50 cm	20/60
11	F/67	OS	PDR	80	4 d	FC 1 m	20/50
12	F/31	OD	Valsalva retinopathy	20	4 d	HM	20/20

PDR = Proliferative diabetic retinopathy; mJ = millijoule; d = days; OD = right eye; OS = left eye.

was best in the patients with Valsalva retinopathy, compared with those with either diabetic retinopathy or macroaneurysm due to hypertensive vascular disease. Postoperative best corrected visual acuity (BCVA) reached the level of 20/20 in all patients with Valsalva retinopathy which may be explained by the lack of retinal vascular lesions or other macular pathologies.

Ulbig et al studied 21 patients with premacular subhyaloid hemorrhage of different etiologies. Hyaloidotomy was successful in 16 (76.2%) of their patients, with visual improvement in all. Final BCVA was better in patients with Valsalva retinopathy compared with other etiologies and approached normal levels after treatment.<sup>12</sup>

Rennie et al evaluated 10 patients with premacular subhyaloid hemorrhage of different etiologies. Nd-YAG laser hyaloidotomy was performed in 6 patients while 4 patients were managed conservatively. Nd-YAG laser hyaloidotomy achieved rapid resolution of subhyaloid hemorrhage in all cases and no patient had evidence of damage to the retina or choroid due to treatment. Nevertheless, among the conservatively managed cases, 3 had slow resolution of hemorrhage over 3 to 6 months and one with proliferative diabetic retinopathy (PDR), in 18 months.<sup>4</sup>

Gabel et al evaluated 3 patients with premacular subhyaloid hemorrhage. Nd-YAG laser hyaloidotomy was successful in all cases, and one patient with Valsalva retinopathy after military operation gained full vision postoperatively.<sup>14</sup>

Considering the results of this investigation and that of previous studies, we may conclude that Nd-YAG laser hyaloidotomy is a simple, inexpensive outpatient procedure which is relatively safe compared with other more complex operations such as deep vitrectomy and its potentially serious complications. It results in rapid visual recovery and especially very good outcomes in patients with Valsalva retinopathy. This technique can prevent long-term entrapment of blood and its adverse effects on macula including potential permanent loss of vision. Further studies including controlled clinical trials to compare this treatment with other modalities (e.g. deep vitrectomy) or spontaneous absorption of subhyaloid blood are warranted before drawing more definite conclusions.

## References

- 1 Gass JDM. *Stereoscopic Atlas of Macular Diseases*. 3rd ed. St Louis: CV Mosby; 1987.
- 2 Khairallah M, Ladjimi A, Messaoud R, Ben Yahia S, Hmidi K, Jenzeri S. Retinal venous macroaneurysm associated with premacular hemorrhage. *Ophthalmic Surg Lasers*. 1999; **30**: 226 – 228.
- 3 Duane TD. Valsalva hemorrhagic retinopathy. *Trans Am Ophthalmol Soc*. 1972; **70**: 298 – 313.
- 4 Rennie CA, Newman DK, Snead MP, Flanagan DW. Nd-YAG laser treatment for premacular subhyaloid hemorrhage. *Eye*. 2001; **15**: 519 – 524.
- 5 Cheung CM, Benson MT. Postchemotherapy premacular subhyaloid hemorrhage. *Eye*. 2003; **17**: 97 – 99.
- 6 Mansour AM, Ojeimi GK. Premacular subhyaloid hemorrhage following laser *in situ* keratomileusis. *J Refract Surg*. 2000; **16**: 371 – 372.
- 7 Callender D, Beirouty ZA, Saba SN. Valsalva hemorrhagic retinopathy in a pregnant woman. *Eye*. 1995; **9**: 808 – 809.
- 8 O'Hanley GP, Canny CL. Diabetic dense premacular hemorrhage. A possible indication for prompt vitrectomy. *Ophthalmology*. 1985; **92**: 507 – 511.
- 9 Ramsay RC, Knobloch WH, Cantrill HL. Timing of vitrectomy for active proliferative diabetic retinopathy. *Ophthalmology*. 1986; **93**: 283 – 289.
- 10 Zhao P, Hayashi H, Oshima K, Nakagawa N, Ohsato M. Vitrectomy for macular hemorrhage associated with retinal arterial macroaneurysm. *Ophthalmology*. 2000; **107**: 613 – 617.
- 11 Conway MD, Peyman GA, Recasens M. Intravitreal tPA and SF6 promote clearing of premacular subhyaloid hemorrhages in shaken and battered baby syndrome. *Ophthalmic Surg Lasers*. 1999; **30**: 435 – 441.
- 12 Ulbig MW, Mangouritsas G, Rothbacher HH, Hamilton AM, McHugh JD. Long-term results after drainage of premacular subhyaloid hemorrhage into the vitreous with a pulsed Nd-YAG laser. *Arch Ophthalmol*. 1998; **116**: 1465 – 1469.
- 13 Celebi S, Kukner AS. Photodisruptive Nd-YAG laser in the management of premacular subhyaloid hemorrhage. *Eur J Ophthalmol*. 2001; **11**: 281 – 286.
- 14 Gabel VP, Birngruber R, Gunther-Koszka H, Puliafito CA. Nd-YAG laser photodisruption of hemorrhagic detachment of the internal limiting membrane. *Am J Ophthalmol*. 1989; **107**: 33 – 37.
- 15 Fechner PU. Premacular hemorrhage: a new indication for argon-laser-therapy [in German]. *Klin Monatsbl Augenheilkd*. 1980; **177**: 502 – 505.
- 16 Fankhauser F, Kwasniewska S, van der Zypen E. Vitreolysis with the Q-switched laser. *Arch Ophthalmol*. 1985; **103**: 1166 – 1171.
- 17 Brown GC, Benson WE. Treatment of diabetic traction retinal detachment with the pulsed neodymium-YAG laser. *Am J Ophthalmol*. 1985; **99**: 258 – 262.
- 18 Bonner RF, Meyers SM, Gaasterland DE. Threshold for retinal damage associated with the use of high-power neodymium-YAG lasers in the vitreous. *Am J Ophthalmol*. 1983; **96**: 153 – 159.