

---

## Case Report

---

# Heterotopic Neuroglial Tissue Causing Upper Airway Obstruction in A Newborn

Negar Azarpira MD\*, Mohamad-Javad Ashraf MD\*\*, Bijan Khademi MD\*\*\*

---

**Heterotopic neuroglial tissue, composed of differentiated neuroectodermal tissue, represents developmental heterotopia of neuroglial tissue rather than true neoplasm. Herein, we present a patient with nasopharyngeal heterotopic neuroglial tissue who presented with respiratory distress and feeding difficulty in early days after birth. Magnetic resonance imaging showed a cystic lesion measuring about 3 × 1.5 cm in the nasopharynx near the uvula. The lesion was resected and confirmed histologically as a heterotopic neuroglial tissue.**

---

*Archives of Iranian Medicine, Volume 9, Number 4, 2006: 419 – 421.*

---

**Keywords:** Heterotopia • neonate • neuroglial tissue

### Introduction

**H**eterotopic neuroglial tissue (HNT) was first described by Reid in 1852.<sup>1</sup> Composed of differentiated neuroectodermal tissue, these lesions represent developmental heterotopia of neuroglial tissue rather than true neoplasm.<sup>2, 3</sup> Unlike meningoencephaloceles, brain heterotopias lack connection with the subarachnoid space.<sup>4 - 6</sup> Patients usually are initially seen in the newborn period with airway obstruction, feeding difficulty, or a neck mass. The most common location of HNT is the nasal cavity, where it is traditionally but erroneously, termed “nasal glioma.” Less commonly, brain heterotopia have been reported in the scalp, tongue, pharynx, palate, orbit, and neck.<sup>2, 7, 8</sup> The majority of patients with HNT are products of uncomplicated pregnancies. There seems to be a female predominance.<sup>2, 4</sup> No syndromic predisposition or known etiologic factor has so far been identified. Patients might have other craniofacial anomalies such as cleft palate and choanal atresia. Computerized

tomography (CT) and magnetic resonance imaging (MRI) are complementary studies that are necessary in preoperative planning to determine the extent and location of the mass and to exclude intracranial connection.<sup>9</sup> Surgical excision is the treatment of choice; although the time it should be performed is controversial.

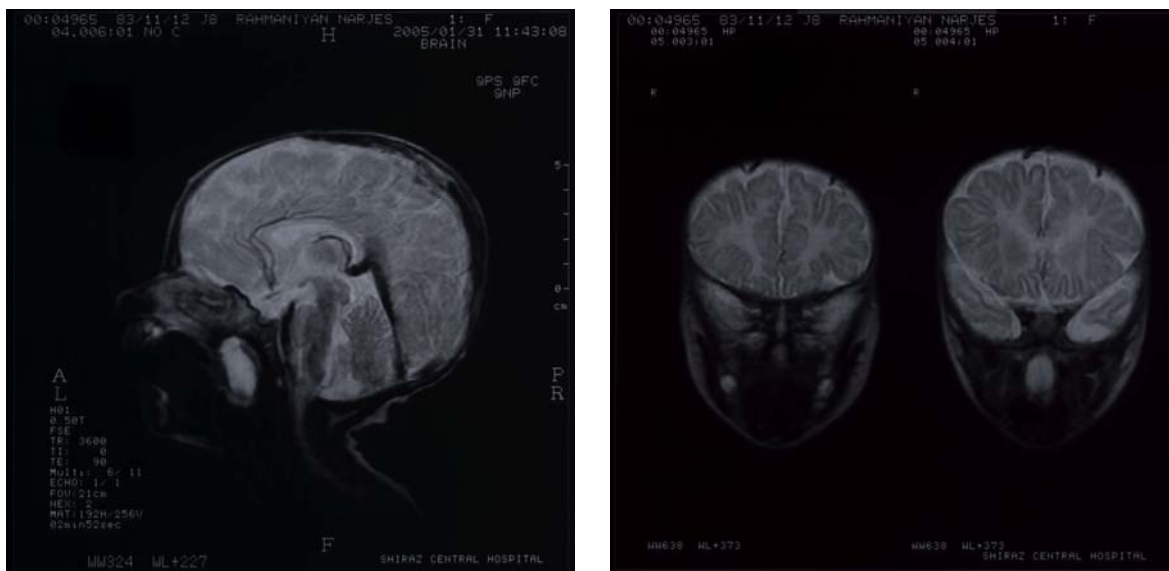### Case Report

A full-term white girl, a product of an uncomplicated pregnancy, developed respiratory distress and feeding difficulty 48 hours after birth. Prenatal history was unremarkable. She experienced snorting, nasal flaring, and inability to feed. Physical examination revealed no gross craniofacial abnormalities. CT scan and MRI showed a cystic lesion measuring about 3 × 1.5 cm in the nasopharynx just in vicinity of the uvula (Figures 1). Under general anesthesia, this area was visualized by direct nasopharyngoscopy. A blue nodule sized approximately 1.5 to 2 cm, firm to palpation was observed near the uvula. The mass was excised and sent for pathologic examination. The tissue was solid and brown in color measuring about 2 × 2 × 1 cm. Microscopic examination showed neuroglial tissue with papillary structures of choroid plexus just beneath the epithelium of the nasopharynx (Figure 2). The patient was followed with serial imaging and had no recurrences.

---

**Authors's affiliations:** \*Department of Pathology, Transplant Research Center, Nemazi Hospital, \*\*Department of Pathology, \*\*\*Department of Otolaryngology, Khalili Hospital, Shiraz University of Medical Sciences, Shiraz, Iran.

**•Corresponding author and reprints:** Negar Azarpira MD, Department of Pathology, Transplant Research Center, Nemazi Hospital, Shiraz University of Medical Sciences, Shiraz, Iran. Telefax: +98-711-627-6211, E-mail: negarazarpira@yahoo.com. Accepted for publication: 28 December 2005



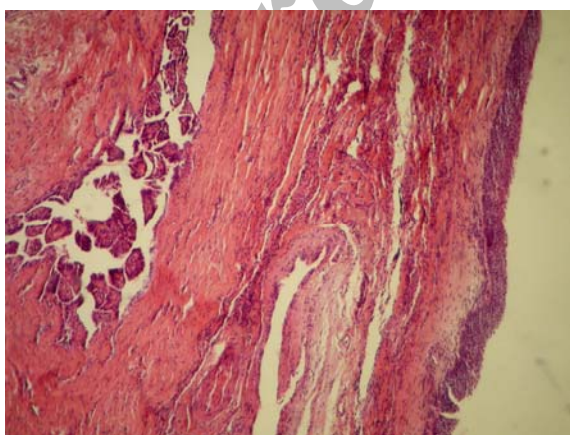
**Figures 1.** Magnetic resonance imaging revealing a cystic lesion in the nasopharynx near the uvula (coronal and sagittal views).

### Discussion

The differential diagnosis of masses in the nose and pharynx causing airway obstruction in the newborn includes glioma, teratoma, cystic hygroma, hemangioma, neurofibroma, ectopic thyroid, brachial anomaly, and heterotopic brain.<sup>10</sup> If the tissue specimen contains mature neural tissue, the differential diagnosis is limited to three entities, namely teratoma, encephalocele, and HNT. Differentiation of these tumors can be made according to clinicopathologic and radiographic correlations.<sup>10</sup>

Brain heterotopias are composed of nests of neural tissue, without mitosis, embedded within

varying amount of fibrovascular stroma. Neurons can be present in up to 10% of cases. Focal calcification might be present. Unlike nasal glioma, heterotopic pharyngeal neuroglial tissue might contain neurons and astrocytes as well as more complex central nervous system elements such as ependymal-lined structures, a functioning choroid plexus, and pigmented cells of retinal differentiation.<sup>1 - 10</sup> HNT is composed solely of ectodermal elements, which distinguishes it from teratoma, which is composed of all three germ layers. Grossly, HNT is solid, firm, and dark brown or red. It might have cystic components containing a cerebrospinal fluid-like clear fluid. Radiographic assessment of pharyngeal HNT is best performed using CT complemented by MRI. Axial and coronal images of the head, neck, and brain delineate the location of the tumor and its relationship to the skull base. Erosion of the floor of the middle cranial fossa is characteristically associated with brain heterotopia in nasopharyngeal space. If skull base erosion is present, MRI will be helpful in discerning an intracranial connection. Magnetic resonance characteristics of HNT resemble normal brain tissue in all pulse sequences.<sup>10</sup> Surgical intervention is necessary in patients with heterotopic nasopharyngeal neuroglial tissue that causes airway distress, dysphasia, or failure to thrive. Patients with airway compromise or failure to thrive might require delayed surgical resection, tracheostomy, or gastrostomy tube insertion.



**Figure 2.** Heterotopic neuroglial tissue with papillary structures of choroid plexus, beneath the nasopharyngeal epithelium (H&E x50).

Tumor resection in the neonatal period might allow early oral feeding and avoidance tracheostomy. Resection should be as complete as possible but without scaring vital structures or compromising functions. Multiple surgical resections might be necessary for complete resection. Early surgical intervention in the neonatal period seems to be beneficial for reasons; first, further growth of neuroglial heterotopia might cause distortion and erosion of bone and results in facial deformity requiring further correction. Second, delay in resection might disturb normal development of swallow function and pharyngeal coordination.<sup>9, 10</sup>

In the literature, most of the patients had presented with respiratory distress just as our patient did. Since heterotopic nasopharyngeal brain tissue is unusual and most of the patients had responded to surgical excision, awareness of this entity is important.

### References

- 1 Kallman JE, Loevner LA, Yousem DM, Chalian AA, Lanza DC, Jin L, et al. Heterotopic brain in the pterygopalatine fossa. *AJNR Am J Neuroradiol*. 1997; **18**: 176 – 179.
- 2 Broniatowski M, Witt WJ, Shah AC, Galloway PG, Abramowsky CR. Glial tissue in the parapharyngeal space. *Arch Otolaryngol*. 1981; **107**: 636 – 641.
- 3 Robbins SH 3rd, Tomaszewski MM, Garcia VF, Egli KD, d'Avis JC. Heterotopic brain presenting as a cystic neck mass with mandibular deformity. *Pediatr Pathol*. 1985; **4**: 341 – 349.
- 4 Madjidi A, Couly G. Heterotopic neuroglial tissue of the face. *Oral Surg Oral Med Oral Pathol*. 1993; **76**: 284 – 288.
- 5 Seibert RW, Seibert JJ, Jimenez JF, Anguaco EJ. Nasopharyngeal brain heterotopia--a cause of upper airway obstruction in infancy. *Laryngoscope*. 1984; **94**: 818 – 819.
- 6 April MM, Seymour BT, Duboys E, Egnor M, Braun A, Katz AE. Massive cystic heterotopic brain tissue. *Int J Pediatr Otorhinolaryngol*. 1994; **28**: 235 – 239.
- 7 Knox R, Pratt M, Garvin AJ, White B. Heterotopic lingual brain in the newborn. *Arch Otolaryngol Head Neck Surg*. 1989; **115**: 630 – 632.
- 8 Pryce DW, Khine M, Verbov JL, van Velzen D. Scalp cyst with heterotopic brain tissue. *Br J Dermatol*. 1993; **129**: 183 – 185.
- 9 Cohen AH, Abt AB. An unusual cause of neonatal respiratory obstruction: heterotopic pharyngeal brain tissue. *J Pediatr*. 1970; **76**: 119 – 122.
- 10 Behar PM, Muller S, Gerber ME, Todd NW. Heterotopic neuroglial tissue causing airway obstruction in the newborn. *Arch Otolaryngol Head Neck Surg*. 2001; **127**: 997 – 1002.