

Case Report

Results of the Repair of Aortic False Aneurysm

Seyed-Hossein Ahmadi MD*, Nader Movahed MD*, Kioumars Abbasi MD*, Hassan Soltaninia MD*, Ali-Reza Amirzadegan MD**, Mehdi Najafi MD*, Shapoor Shirani MD***, Mehrab Marzban MD*, Abbas-Ali Karimi MD*, Seyed-Jalil Mirhoseini MD*, Mehdi Sanatkarfar MD*

Aortic false aneurysm is a rare complication of surgery of the aorta that can occur several months to years after the initial operation. We reviewed our results with false aneurysm repair using deep hypothermia and circulatory arrest.

Three patients were reoperated for false aneurysm of the ascending aorta. Femorofemoral cardiopulmonary bypass with a heparinized system was used in all patients. Hypothermic circulatory arrest at an average temperature of 20°C was instituted in all patients for repair. Two patients had a patch repair with pericardium, and the other one had primary repair of the defect.

All patients had false aneurysms in the ascending aorta at the site of a previous aortotomy. Two patients had proven infection as the cause. The mean cardiopulmonary bypass time was 183 ± 20 minutes, and the mean circulatory arrest time was 35 minutes. Operative mortality was not seen. The mean time for extubation in survivors was 10 – 12 hours, and the average time to discharge was 26 days.

Aortic false aneurysms can be safely approached using femorofemoral cardiopulmonary bypass, hypothermic circulatory arrest, and patch repair with acceptable operative mortality and long-term survival.

Archives of Iranian Medicine, Volume 9, Number 4, 2006: 429 – 432.

Keywords: Ascending thoracic aorta • cardiopulmonary bypass • false aneurysm

Introduction

Aortic false aneurysms are rare complication of surgical manipulation of the aorta occurring in less than 0.5% of the patients undergoing cardiac surgery.¹ Numerous etiologic entities have been associated with this complication such as patch repair of coarctation of the aorta, graft infection or mediastinitis, poor anastomotic techniques, and poor aortic wall tissue.^{1–3} Aortic pseudoaneurysms or false aneurysms are the result of disruption of at least one layer of the wall of the vessel and

contained the remaining vascular layers supported by the surrounding structures of the mediastinum. Pseudoaneurysm of the ascending aorta can present as a pulsatile suprasternal mass, evidence of myocardial ischemia as a result of compression of coronary artery bypass grafts, dysphagia, and stridor. Patients usually present with general symptoms of fatigue and weight loss.

The approach to these patients depends on the site and size of the false aneurysm. Numerous reports have been published about the repair of aortic false aneurysm in the abdominal aorta, but very few studies have reported the successful repair of the thoracic aorta.⁴ We describe our results of surgical repair of false aneurysm of the thoracic aorta using cardiopulmonary bypass (CPB), deep hypothermia, and circulatory arrest.

Case Report

Three patients were retrospectively reviewed for reoperations for false aneurysm of the

Authors' affiliations: *Department of Cardiovascular surgery, **Department of Cardiology, ***Department of Radiology, Tehran Heart Center, Tehran University of Medical Sciences, Tehran, Iran.

Corresponding author and reprints: Mehdi Sanatkarfar MD, Department of Cardiovascular Surgery, Imam Khomeini Hospital, Keshavarz Blvd., Tehran, Iran.

Fax: +98-21-692-9977,

E-mail: a3094@sina.tums.ac.ir.

Accepted for publication: 6 November 2006

Table 1. Patients' characteristics.

No.	Age	Initial surgery	Site of aneurysm	Type of repair	Long-term survival
1	55	Aortic valve replacement	Ascending aorta	Pericardial patch	Yes
2	42	Aortic valve replacement with homograft valve	Ascending aorta	Primary repair	Yes
3	40	Aortic valve replacement	Ascending aorta	Pericardial patch	No

ascending thoracic aorta. Patients' characteristics are described in Table 1. All patients had a preoperative thoracic computerized tomographic (CT) scan to better localize the site of aneurysm formation (Figure 1), and transesophageal echocardiography and catheterization (Figure 2) for detection of aortic valve insufficiency. The cause of false aneurysm formation was previous surgery in all cases. No aneurysms had ruptured before operation. False aneurysms in the ascending aorta arose after infection in 2 cases and after homograft aortic root replacement in one case. The aneurysms were repaired using patch repair with pericardium in two patients, and primary repair in one patient.

All patients underwent a median sternotomy. The common femoral vein and artery were cannulated, CPB and cooling were instituted before the thoracic incision was made. A heparinized membrane oxygenator was used, and heparin (300 IU/kg body weight) was administered to maintain an activated clotting time of at least 750 seconds. The patients were cooled to 18° to 20°C before the circulatory arrest was instituted. During deep cooling, left anterolateral thoracotomy and venting apex were performed for prevention of cardiac distention. Chest was opened and

antegrade cardioplegia was used in these patients. Our anesthesiologists maintained brain hypothermia using ice packs placed around the patients' head. After termination of CPB, heparin was antagonized with protamine sulfate in a 1:1 ratio.

In one case the opening of aneurysm around the left coronary ostia was closed with pledgetted suture. In the other two cases the orifice of false aneurysm on the previous cannulation site was debrided and closed with pericardial patch. After rewarming, CPB restarted and operation completed as usual (Figures 3, 4, and 5).

The average CPB time was 183 ± 20 minutes, and the average time of circulatory arrest was 35 minutes. In infected false aneurysms, prolonged systemic intravenous antibiotic treatment was used. There was no early mortality. None of the patients demonstrated signs of cardiogenic shock and were weaned from CBP after completing of surgical repair with minimal inotropic support. All patients had an uneventful hospitalization and discharged within 3 weeks. There were not any complications after surgery. The mean time for extubation in operative survivors was 10.8 ± 1.8 hours, and the average time to discharge was 26 days. Follow-up

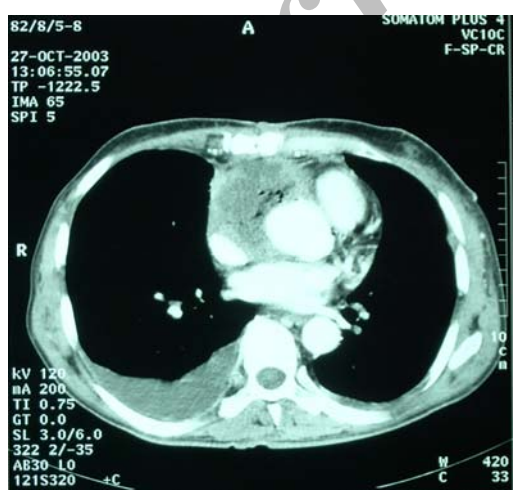


Figure 1. Thoracic computerized tomographic scan showing a large false aneurysm of the ascending aorta.

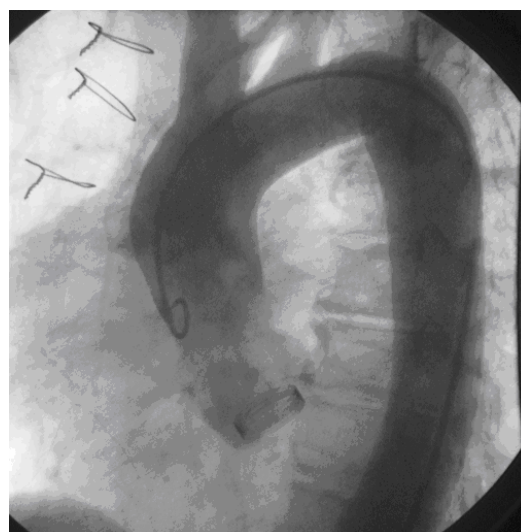


Figure 2. Angiographic evaluation of the aortic false aneurysm demonstrating a false lumen and cavity (arrow).

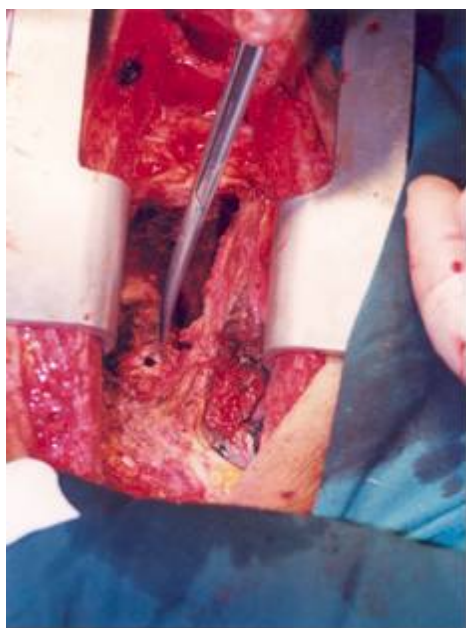


Figure 3. The orifice of false aneurysm of the ascending aorta (arrow).

was 100% complete. The average follow-up period was 13 ± 5 months. One patient died at 2 months postoperatively of undiagnosed pericardial tamponade (found at autopsy). The rest of the operative survivors enjoy a good quality of life and have resumed their everyday activities. They have been followed with either yearly echocardiography or magnetic resonance imaging, and none have shown repeated false aneurysm formation.

Discussion

False aneurysms of the thoracic aorta are rare complications after surgical manipulation. They can appear at the sites of anastomosis or

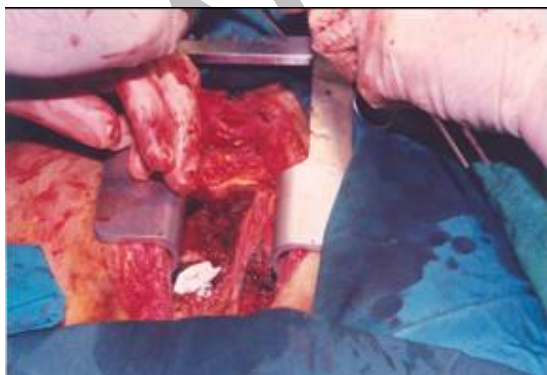


Figure 4. Repair of false aneurysm of the ascending aorta.

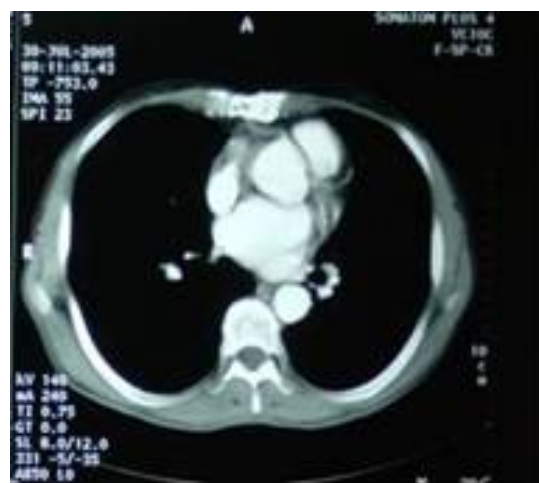

Figure 5. Thoracic computerized tomographic scan after repair of false aneurysm of the ascending aorta.

cannulation, or at the sites of needle puncture for pressure measurements, to purge the aorta of air, or to inject cardioplegic solutions.¹⁻³ CT angiography is the imaging modality of choice for assessment of complications of aortic surgery.⁵ Once the diagnosis is made, the false aneurysms have to be considered as surgical emergencies and must be corrected before rupture. Although false aneurysm of the aorta can result from other causes such as tuberculosis, human immunodeficiency virus, and trauma, the present study focused on those aneurysms related to surgical manipulation of the aorta.^{6, 7} Surgical intervention must be carefully planned because of the inherent risk of rupture at sternotomy. In these circumstances, the use of femorofemoral bypass before sternotomy is a well-known strategy.¹ Nevertheless, rupture during sternal reentry does occur, and it is essential to control the bleeding until adhesions between the heart and the sternum are released. A recent report from Roth and colleagues,⁸ in which 10 patients were reoperated for aneurysm after patch aortoplasty repair of coarctation of the aorta, found that there was no mortality and only two minor neurologic events, using femorofemoral bypass and hypothermic circulatory arrest, happened. Pseudoaneurysms of the ascending aorta carry a much higher morbidity and mortality because of the risk at sternal reentry and the fact that many of these patients have an infectious etiology and are in a septic state at the time of surgery.⁸ We have presented a series of three patients with false aneurysm of the ascending aorta. Two of these

patients presented with signs of infection and dyspnea. The infection was proved by positive blood culture for *Staphylococcus* species. The infection was caused by either direct extension of mediastinitis to the ascending aorta or by hematogenous spread. These results are in concordance with the study reported by Sullivan and colleagues,⁹ who reviewed outcomes of false aneurysm repair in 31 cases. Another study looking at infected abdominal aneurysms⁴ reported sepsis as a leading cause of death and was associated with 40% mortality rate. In the study by Sullivan and colleagues,⁹ the mortality rate during hospitalization was 29%. The Operative survivors had uneventful hospitalization to discharge. One patient had a difficult postoperative course five months after surgery and died.

The use of circulatory arrest is essential in all patients because false aneurysm formation of the ascending aorta preclude clamping and infusion of cardioplegia into the coronary ostia. Deep hypothermia was achieved at temperature of 20°C or lower, which is a safe temperature to minimize neurologic injury during circulatory arrest. Of the operative survivors, none exhibited neurologic deficits in the postoperative period. False aneurysm repair was accomplished using one of the two techniques; patch repair with pericardium, and primary repair. The rest of our cohort enjoyed an uneventful course and were still alive at follow-up. The surgical technique was chosen depending on the size of the false aneurysm lumen and the overall quality of the remaining aorta. If feasible, a patch was used and sutures were anchored in healthy aortic tissue when possible. If the aorta showed uniform fragility and had a tendency for tearing, a Dacron tube graft or homograft replacement associated with pectoral muscle flaps or epiploplasty was the procedure of choice.¹⁰ In

conclusion, aortic false aneurysms have a high mortality and morbidity rate but can be safely managed using femorofemoral CPB, hypothermic circulatory arrest, and patch repair using pericardium with acceptable operative mortality.

References

- 1 Katsumata T, Moorjani N, Vaccari G, Westaby S. Mediastinal false aneurysm after thoracic surgery. *Ann Thorac Surg* 2000; **70**: 547 – 552.
- 2 Stassano P, De Amicis V, Gagliardi C, DiLello F, Spampinato N. False aneurysm from the aortic vent site. *J Cardiovasc Surg (Torino)*. 1982; **23**: 401 – 402.
- 3 Sakashita I, Takeuchi Y, Otani S, Kudo S, Washio M, Asano K. Noninjected false aneurysm of the ascending aorta eight years after aortic valve surgery. *Jpn Heart J*. 1976; **17**: 422 – 427.
- 4 Fillmore AJ, Valentine RJ. Surgical mortality in patients with infected aortic aneurysms. *J Am Coll Surg*. 2003; **196**: 435 – 441.
- 5 Dumont E, Carrier M, Cartier R, Pellerin M, Poirier N, Bouchard D, et al. Repair of aortic false aneurysm using deep hypothermia and circulatory arrest. *Ann Thorac Surg*. 2004; **78**: 117 – 121.
- 6 Talwar S, Choudhary SK. Tuberculous aneurysms of the aorta [Letter]. *J Thorac Cardiovasc Surg*. 2003; **125**: 1184.
- 7 Chello M, Tamburrini S, Mastroberto P, Covino E. Pseudoaneurysm of the thoracic aorta in patients with human immunodeficiency virus infection. *Eur J Cardiothorac Surg*. 2002; **22**: 454 – 456.
- 8 Roth M, Lemke P, Schonburg M, Klovehorn WP, Bauer EP. Aneurysm formation after patch aortoplasty repair (Vosschulte): reoperation in adults with and without hypothermic circulatory arrest. *Ann Thorac Surg*. 2002; **74**: 2047 – 2050.
- 9 Sullivan KL, Steiner RM, Smullens SN, Griska L, Meister SG. Pseudoaneurysm of the ascending aorta following cardiac surgery. *Chest*. 1988; **93**: 138 – 143.
- 10 Carrier M, Perrault LP, Pellerin M, Marchand R, Auger P, Pelletier GB, et al. Sternal wound infection after heart transplantation: incidence and results with aggressive surgical treatment. *Ann Thorac Surg*. 2001; **72**: 719 – 724.