

---

## Brief Report

---

# Clinical Features and Outcome of 83 Adult Patients with Brain Abscess

Mohammad Faraji-Rad MD\*, Fariborz Samini MD\*

Brain abscess continues to be a problem in neurosurgery and associates with morbidity and mortality even in the antibiotics and computed tomography (CT) era. In this study, we tried to recognize the indications of operation, effectiveness of preoperative CT scan, and antibiotic therapy in the diagnosis and treatment of these patients, and to identify the morbidity and mortality rates of adult patients with brain abscess.

In a retrospective study from 1994 through 2004, we reviewed 83 adult patients with brain abscess (aged > 16 years), who had been treated medically or surgically by the authors in neurosurgical centers.

Of 83 patients, 52 (63%) had infection with only *Streptococci viridans*, 13 (16%) had other types of streptococcal infections, and 13 (16%) had infections with other organisms like *Pseudomonas*, *Enterococci*, etc. Three (4%) had anaerobic infection and 2 (3%) had polymicrobial infections. Nineteen patients had paranasal and skull base sinusitis; 32 patients had mastoiditis. Five (6%) patients were treated medically. Others were treated medically and surgically (n = 78; 94%). The mortality rate was 5% (n = 4).

Our data, in accord with the majority of authors, allow the conclusion that an aspiration-type operation must be performed for the diagnosis and therapy in most patients with brain abscess. Parenteral antibiotic therapy should be given for six to eight weeks, depending on the type of operation. Prognosis is favorable with early diagnosis and prompt treatment.

*Archives of Iranian Medicine, Volume 10, Number 3, 2007: 379 – 382.*

---

**Keywords:** Adults • aspiration-type operation • brain abscess • brain CT scan • brain MRI

## Introduction

Brain abscess continues to be a problem in neurosurgery, and associates with morbidity and mortality even in the antibiotics and computed tomography (CT) era. The management of bacterial abscess still remains a controversial subject. In spite of the difficulties, bacterial brain abscess has been proven to be one of the diseases that neurosurgeons can treat most successfully.<sup>1,2</sup>

In this study, we tried to recognize the indications of operation, effectiveness of preoperative CT, and antibiotic therapy in the diagnosis and treatment of these patients, and to

identify the morbidity and mortality rates of adult patients with brain abscess.

## Patients and Methods

Between 1994 and 2004, 83 patients with brain abscess were diagnosed and admitted to our neurosurgical wards.

A diagnosis of brain abscess was considered definite, if:

- The organism was isolated from pus or cerebrospinal fluid (CSF) cultures.
- CT scan showed findings characteristic of brain abscess.
- Classic clinical manifestations occurred including headache, fever, localized neurologic signs, or disturbance of consciousness.

The brain abscesses were characterized as being either nosocomial or community-acquired.

Nosocomial infection was defined as:

---

**Authors' affiliation:** \*Department of Neurosurgery, Mashhad University of Medical Sciences, Mashhad, Iran.

**Corresponding author and reprints:** Mohammad Faraji-Rad MD, Department of Neurosurgery, Ghaem Hospital, Mashhad, Iran.

Tel: +98-511-841-3493, E-mail: farajirad@yahoo.com.

Accepted for publication: 16 July 2006

- A positive bacterial infection that showed clinical evidence of infection no sooner than 48 hours after admission.
- An infection that occurred after discharge but within one month of craniotomy.
- Whenever it was secondary to CSF shunt.

For each patient, present symptoms and signs, underlying source of infection, site of abscess, therapeutic methods, and outcome were retrospectively reviewed.

We used parenteral antibiotic therapy for six to eight weeks, depending on the type of operation performed. Serial CT scans obtained every week during the treatment and then monthly for three to four months or until the contrast-enhanced CT scans showed that the lesion has disappeared.

Surgical treatment consisted of either aspiration or in rare cases, resection. Aspiration consisted of aspirating the contents of the abscess with a catheter via a burr hole and leaving the capsule in place. Aspiration of the abscess and washing inside the abscess with saline and antibiotics may have been performed many times.

We gave corticosteroid only in patients with mass effects and progressive neurologic deficits.

Ultimately, therapeutic outcome was assessed according to the following five grades:

- Good recovery
- Moderate disability
- Severe disability
- Persistent vegetative state
- Death

Clinical and neuroradiologic findings, treatment modalities, and therapeutic outcomes of the patients were summarized and statistical analyses with descriptive methods and  $\chi^2$  test were done.

## Results

Sixty-eight (82%) of 83 patients were males with a mean age of 54 years (range: 16 – 76 years) and 15 cases (18%) were females with a mean age of 23 years (range: 18 – 68 years).

Fifty-four cases (65%) had a spontaneous form; the remaining 29 patients (35%) were affected because of head trauma or neurosurgical procedures.

The predisposing factors to infection included hematogenous spread in 36 (43%) patients, contagious infection in 11 (14%), neurosurgical events in 15 (18%), and unknown in 21 (25%) patients.

From 83 patients in our study, 11 (13%) had

frontal or maxillary sinusitis and 8 (10%) had ethmoidal and skull base sinusitis. In this group, 14 (74%) patients had supratentorial and 5 (26%) had infratentorial abscesses.

Thirty-two (39%) of 83 patients had mastoiditis too. In this group, only 13 cases had otic discharge. Eighteen (56%) of 32 cases had infratentorial abscesses, six (19%) had supratentorial and infratentorial abscesses, and eight (25%) had supratentorial abscesses.

Antibiotic therapy had been started before the diagnosis of brain abscess was made only in 7 of 19 cases with paranasal and skull base involvement and in 13 of 32 patients who had mastoiditis.

Twenty-seven (33%) patients were admitted with disturbed consciousness (18 patients had drowsiness, six cases had light, and three had deep coma). Headache was found in all but 19 (77%) cases. Fever was found in 12 (14%) patients. Concomitant meningitis occurred in three (4%). Other clinical manifestations included convulsion (2%), hemiparesis (4%), neck stiffness (4%), speech disturbance (4%), visual disturbance (1%), nausea (42%), and vomiting (2%).

The interval between the onset of symptoms to diagnosis of brain abscess was between one and 90 days.

Forty-seven (89%) patients had supratentorial abscesses. Some of them had more than one abscess (n = 13; 16%).

The most common sites of the brain abscess were the frontal (53%) and temporoparietal (28%) lobes. The right hemisphere was involved more often than the left; 62.6% on the right (n = 52) vs.; 33% on the left side (n = 27). Four (5%) patients had bilateral abscess.

Of 83 patients, 59 (71%) had good recovery, 15 (18%) developed moderate disability, four (5%) had severe disability, one (1%) had vegetative state, and four (5%) died.

The recurrence rate in was 8%. In these cases, reoperation and antibiotic therapy were essential.

## Discussion

The causative agents of brain abscess vary from time to time: geographic distribution, age and underlying medical condition of the patients, and the way the infection was contracted. Based on the information from serial studies,<sup>1-3</sup> aerobic or microaerophilic streptococci have been isolated in 27% to 73% of brain abscesses. The difference in these percentages is attributable to the frequent

occurrence of mixed infections and the anaerobic culture technique which may be insufficient was not sufficient for these negative cultures.<sup>1,4,5</sup>

In our study, streptococcal infection was found in 65% of brain abscesses.

Streptococci represent a diverse group of organisms whose clinical presentations and underlying conditions vary greatly in streptococcal brain abscesses according to the different species. *Streptococcus viridans*, which accounts for 48 – 68% in different publications, is a normal inhabitant of the oral cavity, gastrointestinal tract, female genital tract, and upper respiratory tract; they are often considered to be contaminants when isolated from blood culture. *Streptococcus pneumoniae* despite being an important cause of community-acquired pneumonia, bacteremia, and bacterial meningitis,<sup>4,6</sup> is rarely isolated from brain abscess.<sup>4,6,7</sup> Group D streptococci is a rare cause of brain abscess,<sup>4,8</sup> as it was in our study.

Brain abscess usually affects adults, with a peak incidence in the second and third decades of life. In our study, most of the patients were males with a mean age of almost 35 years. Brain abscess is almost always secondary to a focus of suppuration elsewhere in the body and may have developed either by a contagious focus of infection, head trauma, or in most cases, through hematogenous spread from a distant focus.

Streptococci are the most frequent isolated organisms in nontraumatic abscess, although these pathogens have been considered as unusual causes of brain abscess after neurosurgical procedures.<sup>5</sup> Underlying conditions are common in different studies, and include penetrating head trauma, neurosurgical procedures, heart disease, oropharyngeal infection, and medical procedures.

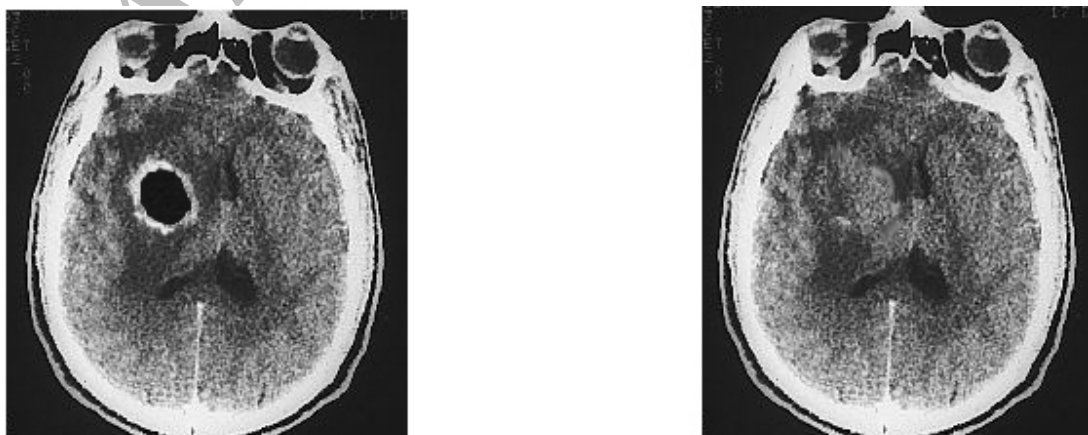
Parameningeal foci because of sinusitis, otitis media, or dental infections account for 22 – 28% of cases; 40 – 50% are secondary to hematogenous spread. In Enting et al study, 19% of cases with bacterial brain abscess had paranasal and skull base sinusitis and 26% of them were accompanied by mastoiditis. The source of infection is frequently obvious, although the definitive cause may remain obscure. The incidence of contagious spreading of infection into the cerebral parenchyma is falling in most parts of the world. Prompt treatment of initial source of infection is the most important factor for this decrease.<sup>5,6,9,10</sup> In our study, the rates were 13.7% and 43.4%, respectively. Twenty to 25 percent of patients have postneurosurgical state or head trauma as the underlying condition.<sup>2,8</sup> In our study, there were observed in 18% of the patients.

Most studies published in the last decade still document high mortality and morbidity in patients with brain abscess. In the Bidzinski and Koszewski's report in 2002; 63% had good recovery, 23% developed moderate disability, 9% had severe disability, and 5% of patients died.<sup>9</sup>

Recurrence rate, in many other studies, was between 7% and 18%. Prompt and suitable treatment of initial infection is the most preventive factor of recurrence.<sup>10</sup> These results are similar to ours.

Our data, in accord with the majority of other authors, allow the conclusion that an aspiration-type operation must be performed for diagnosis and therapy in most patients with brain abscess.

Parenteral antibiotic therapy should be given for six to eight weeks, depending on the type of operation. Serial CT scans should be obtained every week during treatment and then monthly for



**Figure 1.** Brain CT scan of a 53-year-old male patient before and after treatment with antibiotics for six weeks.

three to four months or until contrast-enhanced CT scans show that the lesion has disappeared.

Prognosis is favorable with early diagnosis and prompt treatment.

### References

- 1 Ariza J, Casanova A, Viladrich PF, Linares J, Pallares R, Rufi G, et al. Etiology agent and primary source of infection in 143 cases of focal intracranial suppuration. *J Clin Microbiol.* 1998; **26**: 813 – 835.
- 2 Bernardini GL. Diagnosis and management of brain abscess and subdural empyema. *Curr Neurol Neurosci Rep.* 2004; **4**: 448 – 456.
- 3 Dohrmann PJ, Elrick WL. Observation on brain abscess. *Med J Aust.* 1999; **3**: 78 – 94.
- 4 Beller AJ, Sahar A, Praiss I. Brain abscess: review of 183 cases over a period of 25 years. *J Neurol Neurosurg Psychiatry.* 1995; **32**: 635 – 675.
- 5 Livraghi S, Melancia JP, Antunes JL. The management of brain abscesses. *Adv Tech Stand Neurosurg.* 2003; **28**: 285 – 313.
- 6 Enting RH, de Gans J, Blankevoort JP, Spanjaard L. Meningitis due to viridance streptococci in adult. *J Neurol.* 2003; **211**: 413 – 435.
- 7 Le Moal G, Landron C, Grollier G, Bataille B, Roblot F, Nassans P, et al. Characteristics of brain abscess with isolation of anaerobic bacteria. *Scand J Infect Dis.* 2003; **35**: 318 – 321.
- 8 Mamelak AN, Mampalam TJ, Obana WG, Rosenblum ML. Improved management of multiple brain abscesses: a combined surgical and medical approach. *Neurosurgery.* 1995; **36**: 76 – 86.
- 9 Bidzinski J, Koszewski W. The value of different methods of treatment of brain abscess in CT era. *Acta Neurochir (Wien).* 2002; **102**: 104 – 122.
- 10 Tattevin P, Bruneel F, Clair B, Lellouche F, de Broucker T, Chevret S, et al. Bacterial brain abscesses: a retrospective study of 94 patients admitted to an intensive care unit (1980 to 1999). *Am J Med.* 2003; **115**: 143 – 146.

Archive of SID