
Case Report

Creutzfeldt-Jakob Disease Presenting with Confusion and Visual Disturbance

Masoud Nikanfar MD*, Mehdi Farhoudi MD**, Monireh Halimi MD***, Fereidoon Ashrafiyan-Bonab MD***, Kaveh Mehrvar MD†

Creutzfeldt-Jakob disease is increasingly being reported in the last three decades as a result of increased awareness for the disease. Various studies have reported an annual incidence of 0.5 – 1.5 cases of Creutzfeldt-Jakob disease per million of general population. However, in our country, like other developing countries, the disease is still under-reported. Herewith, we described our clinical experience with an autopsy-proven case of Creutzfeldt-Jakob disease.

Archives of Iranian Medicine, Volume 10, Number 3, 2007: 397 – 400.

Keywords: Confusion • Creutzfeldt-Jakob disease (CJD) • vision

Introduction

Prions can cause neurodegenerative diseases that have long incubation periods and progress inexorably once the clinical symptoms appear. So far, five human prion diseases have been recognized including Kuru, Creutzfeldt-Jakob disease (CJD), variant Creutzfeldt-Jakob disease (vCJD also known as new variant CJD), Gerstmann-Straussler-Scheinker (GSS) syndrome, and fatal familial insomnia (FFI).^{1, 2} Bovine spongiform encephalopathy (BSE), one of prion infections affecting animals, was responsible for a more widespread public attention with its possible link to vCJD.^{3, 4}

These human prion diseases share certain common neuropathologic features including neuronal loss, proliferation of glial cells, absence of an inflammatory response, and the presence of small vacuoles within the neutrophils, which produces a spongiform appearance. The current theory is that prion diseases are associated with the accumulation of an abnormal form of a host cell

protein, the so-called “prion protein” (PrP).⁵

This paper describes the clinical experience with an autopsy-proven case of CJD managed at the Department of Neurology of Razi Hospital, Tabriz, North-West of Iran.

Case Report

A 71-year-old woman referred to our hospital on May 3, 2004 with a one and a half-month history of visual symptoms accompanied by transient confusion and disorientation and dystonic posture in her right arm.

Her family members reported that she had transient attacks of agitation, hallucinations, and confusional state with a duration of about 15 minutes. After each attack, she became normal without any memories of attacks. Gradually, the frequency of these attacks increased. Meanwhile, she complained of transient visual problems such as macropsy, micropsy, blurred vision, and color vision disturbance. She had also transient dystonic posture in her right arm. Before admission, she also developed a mild left-sided hemiparesis. She was visited by a psychiatrist who prescribed haloperidol and clonazepam with no beneficial effect; her condition became worse progressively.

On admission, she had mild confusion, and headache, and vertigo. General examination was normal. In neurologic examination, she had a left hemiparesis, left central hemifacial weakness, no

Authors' affiliations: Department of Neurology, *Razi Hospital, **Imam Hospital, ***Department of Pathology, †Department of Neurology, Imam Hospital, Tabriz University of Medical Sciences, Tabriz, Iran.

Corresponding author and reprints: Mehdi Farhoudi, MD, Department of Neurology, Neurological Sciences Research Center, Imam Hospital, Tabriz, Iran. Telefax: +98-411-334-2889, E-mail: farhoudim@tbzmed.ac.ir

Accepted for publication: 2 August 2006

plantar reflex in the left side, and an action tremor in her right arm.

All biochemical laboratory tests of plasma and urine were normal. Cerebrospinal fluid analysis was normal. In brain computed tomography (CT) and magnetic resonance imaging (MRI), multiple lacunar infarctions and senile atrophy were reported. In her first electroencephalogram (EEG), generalized slow sharp waves appeared in all montages (Figure 1A).

The patient's general condition and level of consciousness progressively deteriorated during hospitalization. After 15 days, she developed myoclonic seizures — first in her right arm and then generalized. In the next EEG, there was progressive slowness and periodic sharp waves. In her last EEG, slow and disorganized background activity that was interrupted by repetitive discharges of large sharp waves in all montages — about one cycle per second — were recorded (Figure 1B, C). She was intubated and finally on June 9, 2004, she died of sepsis.

In pathologic study performed two days after death, the spongiform encephalopathy was documented. Histopathologic examination revealed no Kuru plaque in Congo red and PAS staining. No

inflammatory infiltration was present (Figure 2).

Discussion

CJD, although rare, is the most frequent prion disease of humans. Sporadic (sCJD), familial (fCJD), iatrogenic (iCJD), and recently, variant (vCJD) forms of CJD are all recognized. Approximately, one case of CJD occurs per 1,000,000 population per year with a worldwide distribution. The mean age of onset is 65 years.⁶⁻⁸ Patients with vCJD and iCJD tend to be much younger.

There is no gender predilection for CJD. The vast majority of CJD cases (85 – 95%) are sporadic in whom there is no known infectious source and no evidence of the disease in the prior or subsequent generations of the patient's family.⁹

Rapidly progressive mental deterioration and myoclonic seizures are the two cardinal clinical manifestations of CJD. However, a number of variants or subtypes of the disease have been defined based upon focal neurologic findings. Examples of these include forms with mainly visual, cerebellar, thalamic, and striatal features.¹⁰

Some clinical findings, although compatible

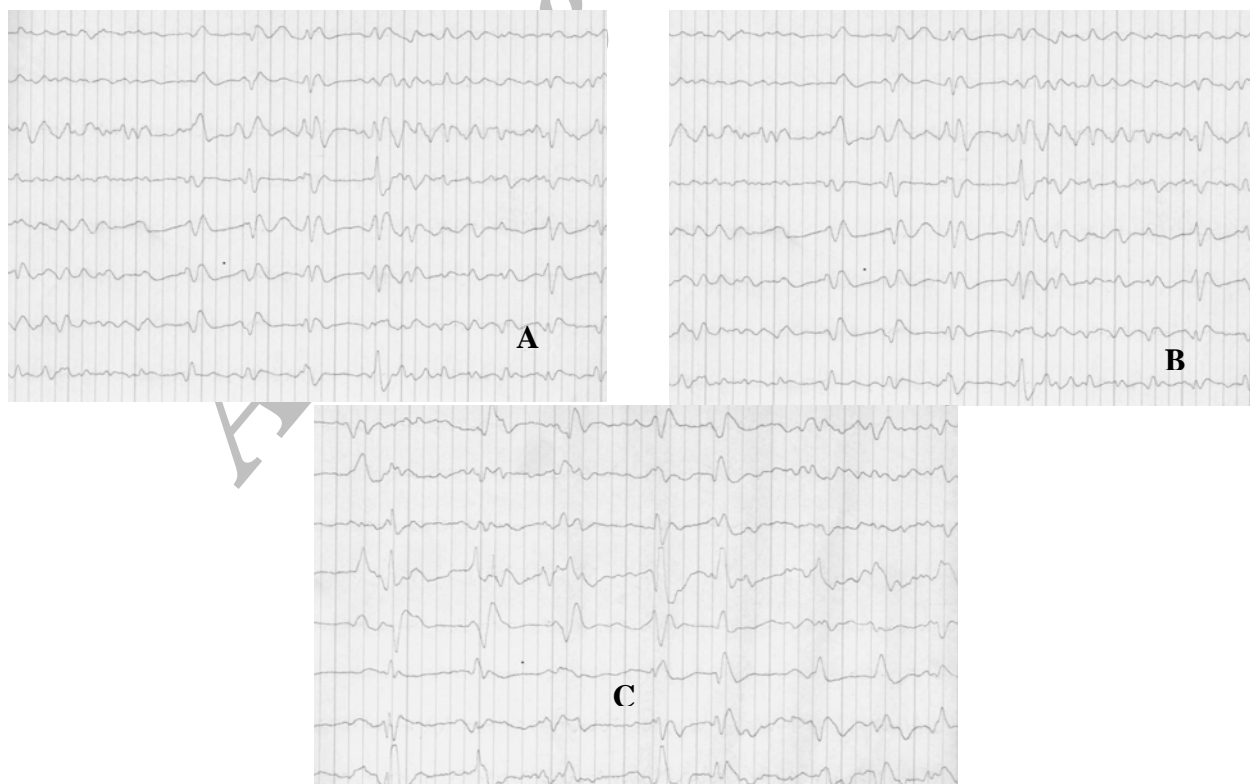


Figure 1. A) Generalized slow sharp waves. B) Progressive slowness and periodic sharp wave; C) Slow and disorganized background activity that interrupted by repetitive discharges of large sharp waves about one cycle per second.

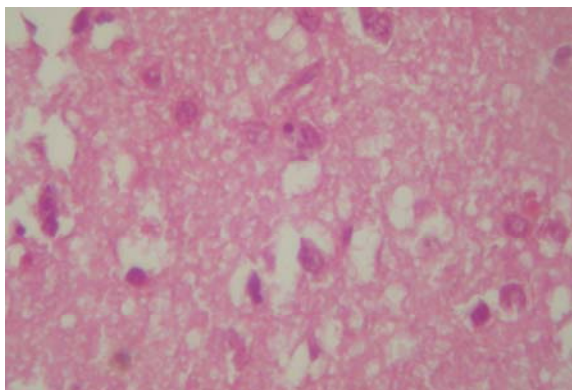


Figure 2. Microscopic examination of cerebral tissue shows variable sized vacuoles within the neutrophils and sometimes in perikaryon of neurons. In some areas, there are neuronal loss and reactive gliosis. No inflammatory infiltration is present.

with CJD, should raise the suspicion of an alternative diagnosis. These include cranial nerve abnormalities, sensory abnormalities, and involvement of the peripheral nervous system.

Five percent of CJD cases are familial. The only clearly established route of transmission is iatrogenic — during transplantation of corneas or dural grafts from infected individuals, after implantation of infected depth electrodes, and injection of human growth hormone or gonadotropins with cadaveric sources. The transmissible agent is resistant to boiling, treatment with formalin and alcohol, and ultraviolet radiation, but can be inactivated by autoclaving at 132 °C and 15 PSI for one hour or by immersion in 5% sodium hypochlorite (household bleach) for one hour.¹¹

The WHO criteria for probable sporadic CJD include progressive dementia, and at least two of the following criteria: myoclonus seizure, visual or cerebellar disturbance, pyramidal/extrapyramidal dysfunction, akinetic mutism, typical EEG, and/or CSF positive for 14-3-3 protein with a clinical duration to death of <2 years; routine investigations should not suggest an alternative diagnosis for definite diagnosis. In addition to the above criteria, one of the two followings should be found: characteristic pathologic changes in brain or positive western blot for confirming the prion protein PrPSC.¹²

The role of MRI and especially diffusion-weighted MRI (DWI) is becoming increasingly important in clinical diagnosis of CJD.

Patients with CJD may have abnormal patterns of hyperintensity in the basal ganglia on MRI or

DWI. DWI is more sensitive than T₂-weighted and flair MRI for the detection of CJD-related lesions, especially in the early weeks of the disease.¹³

A characteristic EEG pattern of periodic synchronous bi- or tri-phasic sharp wave complexes (PSWC) is observed in 67 – 95% of patients with sCJD at sometime in the course of illness. However, the absence of PSWC does not exclude the diagnosis of sCJD. In these cases, serial EEG is recommended.

Abnormal CSF protein, especially the 14-3-3 protein serves as a marker for CJD. The protein 14-3-3 has been advanced as a sensitive and specific diagnostic test for sCJD.¹⁴

Routine laboratory studies are normal in CJD with occasional exceptions of liver function tests.¹⁵ Elevated CSF protein level may occur in about 40% of patients.

In differential diagnosis of CJD, Wipple disease, lithium intoxication, Hashimoto encephalopathy, angiocentric lymphoma, carcinomatous meningitis, major psychosis, unusual form of Alzheimer disease, Lewy-body disease, subacute sclerosing panencephalitis, limbic-brainstem-cerebellar encephalitis, and cerebral lipidosis should be considered.¹¹

A definitive diagnosis of CJD requires brain biopsy or autopsy which can detect the characteristic changes in the brain tissue caused by the disease. Because these procedures are expensive and hazardous, they are usually not performed.

The difficulties of diagnosing CJD might have led to rare reports of the disease. There are only two published case reports from Iran.^{16, 17} Since the disease progresses rapidly, the patient may die before a diagnosis can be made. Furthermore, some physician may not even consider the possibility of CJD because the disease is rare and the clinical symptoms can often be attributed to other ailments. Consequently, CJD may be mistaken for a variety of psychological illnesses because the behavioral changes are seen in 30% of patients at the onset of disease and in 57% of patients in later stages. The disease is fatal within one year in 90% of patients. Our patient had a rapid course and died after two and a half months.

In conclusion, our experience with this patient showed that in any adult patient with psychotic symptoms such as delirium hallucinations, etc., CJD must be considered. In such patients, EEG is an important diagnostic test and must be done.

References

- 1 Haywood AM. Transmissible spongiform encephalopathies. *N Engl J Med.* 1997; **337**: 1821 – 1828.
- 2 Prusiner SB. Shattuck lecture--neurodegenerative diseases and prions. *N Engl J Med.* 2001; **344**: 1516 – 1526.
- 3 O'Brien C. Mad cow disease. *Science.* 1996; **271**: 1798.
- 4 Collinge J. Variant Creutzfeldt-Jakob disease. *Lancet.* 1999; **354**: 317.
- 5 Prusiner SB. The prion hypothesis. In: Prusiner SB, McKinley MP, eds. *Prions.* San Diego: Academic Press; 1987: 17.
- 6 Brown P, Cathala F, Raubertas RF, Gajdusek DC, Castaigne P. The epidemiology of Creutzfeldt-Jakob disease: conclusion of a 15-year investigation in France and review of the world literature. *Neurology.* 1987; **37**: 895 – 904.
- 7 Monreal J, Collins GH, Masters CL, Fisher CM, Kim RC, Gibbs CJJ, et al. Creutzfeldt-Jakob disease in an adolescent. *J Neurol Sci.* 1981; **52**: 341 – 350.
- 8 De Silva R, Findlay C, Awad I, Harries-Jones R, Knight R, Will R. Creutzfeldt-Jakob disease in the elderly. *Postgrad Med J.* 1997; **73**: 557 – 559.
- 9 Brown P, Gibbs CJ Jr, Rodgers-Johnson P, Asher DM, Sulima MP, Bacote A, et al. Human spongiform encephalopathy: the NIH series of 300 cases of experimentally transmitted disease. *Ann Neurol.* 1995; **35**: 513 – 529.
- 10 Kirschbaum WR. *Jakob-Creutzfeldt Disease.* New York: Elsevier; 1968.
- 11 Victor M, Ropper A. *Adams and Victor's Principles of Neurology.* USA: McGraw-Hill; 2001; 814 – 817.
- 12 Global Surveillance. Diagnosis and Therapy of Human Transmissible Spongiform Encephalopathies Report of a WHO Consultation, Geneva, Switzerland; 9 – 11 February 1998, Ref:WHO/EMC/ZDI/98.9.
- 13 Demaerel P, Heiner L, Robberecht W, Sciot R, Wilms G. Diffusion weighted MRI in sporadic Creutzfeldt-Jakob disease. *Neurology.* 1999; **52**: 205.
- 14 Zerr I, Bodemer M, Gefeller O, Otto M, Poser S, Wiltfang J, et al. Detection of 14-3-3 protein in the cerebrospinal fluid supports the diagnosis of Creutzfeldt-Jakob disease. *Ann Neurol.* 1998; **43**: 32 – 40.
- 15 Tanaka M, Iizuka-Yuasa T. Hepatic dysfunction in Creutzfeldt-Jakob disease. *Neurology.* 1992; **42**: 1249.
- 16 Nikanfar M, Halimi M, Mohammadian R, Arami MA. An autopsy-proved case of Creutzfeldt-Jakob disease presenting with depression and catatonia. *Internet J Neurol.* 2004; **3**: 1.
- 17 Masullo C, Brown PW, Macchi G. Creutzfeldt-Jakob disease in an Iranian: the first clinico-pathologically described case. *Clin Neuropathol.* 1996; **15**: 26 – 29.

Archive of SID