
Case Report

Ischemic Intestinal Necrosis in a Five-Year-Old Girl with Diabetic Ketoacidosis

Mahmoud Ashrafi MD*, Mahin Hashemipour MD**, Mohammad-Hassan Moadab MD**,
Masoud Jamshidi MD*, Mehrdad Hosseinpour MD*

Diabetic ketoacidosis is a major source of morbidity and mortality in children and adolescents with type I diabetes mellitus. Although, diabetic ketoacidosis is often associated with dehydration and electrolyte disturbances, cases with gastrointestinal tract complications due to shock remain particularly unusual.

Herein, we reported on a five-year-old girl who had severe diabetic ketoacidosis complicated by hypovolemic shock. Her abdominal pain and acidosis despite vigorous fluid resuscitation and insulin therapy failed to improve. Further investigations showed intestinal problem. At laparotomy gangrenous bowel—about 20 cm long—near the distal ileum was found. Entrectomy and ileo-jejunal anastomosis was done and the child survived.

Archives of Iranian Medicine, Volume 10, Number 4, 2007: 529 – 531.

Keywords: Diabetic ketoacidosis • diabetes mellitus • intestinal mesenteric ischemia • necrosis

Introduction

Twenty to forty percent of children with newly-diagnosed insulin-dependent diabetes mellitus (IDDM) present with diabetic ketoacidosis (DKA).¹⁻³ A common feature of ketoacidosis is acute abdominal pain, which usually improves with resolution of ketonemia after administration of fluids and insulin.

This report describes a five-year-old girl with DKA in whom abdominal pain and acidosis did not resolve with fluid and insulin therapy.

Case Report

A 5-year-old girl with no significant past medical history was referred to our Pediatrics

Emergency Department for evaluation of lethargy, polyuria, and polydipsia. She was well

until two weeks prior to admission, when her parents noted polyuria. Three days before admission, she developed abdominal pain. Just before admission, she developed a tonic generalized convulsion accompanied by muscle rigors and upward gaze that lasted three minutes. She was then brought to a local health center.

On admission, she had a blood pressure of 80/50 mmHg, temperature of 36.5°C, a respiratory rate of 40/min, and a pulse rate of 125/min. Her weight was 13 kg.

In physical examination, we noted sunken eyes, severe dehydration, dry mucosal membranes, and abdominal distention with mild tenderness.

She had a fasting blood sugar (FBS) of 820 mg/dL, an arterial blood pH of 6.82, PaCO₂ of 7 mmHg, PaO₂ of 95 mmHg, bicarbonate of 1.1 mmol/L, base deficit of -33 mEq/L, sodium of 140 mmol/L, and potassium of 3.9 mmol/L. Blood urea nitrogen and creatinine were 13 mg/dL and 0.6 mg/dL, respectively. She also had a white blood cell count of 14.1×10⁹/L with 80% neutrophils and 20% lymphocytes. Her hemoglobin level was 11.4 g/dL, and the platelet count was 282×10⁹/L.

Since her serum osmolality was >340 mosmol/kg, we inserted a central venous catheter for her.

Authors' affiliation: *Department of Pediatric Surgery,
**Department of Pediatric Endocrinology, Alzahra Hospital,
School of Medicine, Isfahan University of Medical Science,
Isfahan, Iran.

•Corresponding author and reprints: Mahmoud Ashrafi MD,
Department of Pediatric Surgery, Alzahra Hospital, Isfahan, Iran.
Telfax: +98-311-673-6514, E-mail: ashrafi@med.mui.ac.ir.

Accepted for publication: 21 July 2007

The patient received 20 mL/kg of normal saline during the first hour followed by insulin infusion started at a rate of 0.1 IU/kg/hr. The volume of intravenous (IV) fluid was based on maintenance and deficit and ongoing loss added to her IV fluid as urine output.

Management of convulsion was started by phenytoin 10 mg/kg as loading dose, followed by 5 mg/kg/24 hr. Due to her condition, we started ceftriaxone 75 mg/kg/24 hr.

After four hours, she had a blood sugar of 1284 mg/dL; sodium of 130 mmol/L; potassium of 2.2 mmol/L, arterial pH of 6.67, bicarbonate of 1.5 mmol/L, and a base deficit of -36 mEq/L.

After 12 hours, despite appropriate management, she was still in DKA (pH 7.13, bicarbonate, 4.3 mmol/L; FBS 461 mg/dL; potassium 3.8 mmol/L).

In physical examination, we noted increased abdominal distension with tenderness. Therefore, a nasogastric (NG) tube was inserted. Some bilious materials were aspirated from the NG tube.

Plain abdominal X-ray showed an obstructive pattern (Figure 1) and abdominopelvic sonography revealed extensive fluid in intestinal loops. After 17 hr of management, laboratory values included a pH of 7.28, bicarbonate of 6.5 mmol/L, and a blood sugar of 430 mg/dL. Her abdominal problems were intensified.

Gradually, we increased the insulin dose to 0.2 IU/kg/hr and prescribed bicarbonate four times. Based on CVP pressure and close heart monitoring, we administered 4.3 L fluid.

Finally, we decided to perform laparotomy for

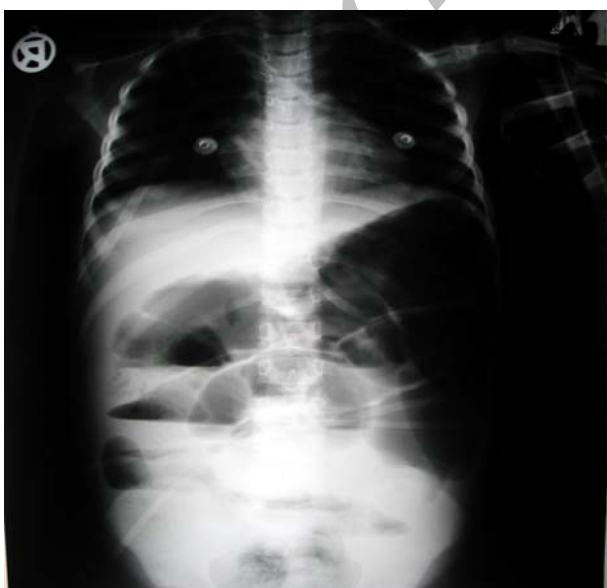

Figure 1. Plain abdominal X-ray of the patient.

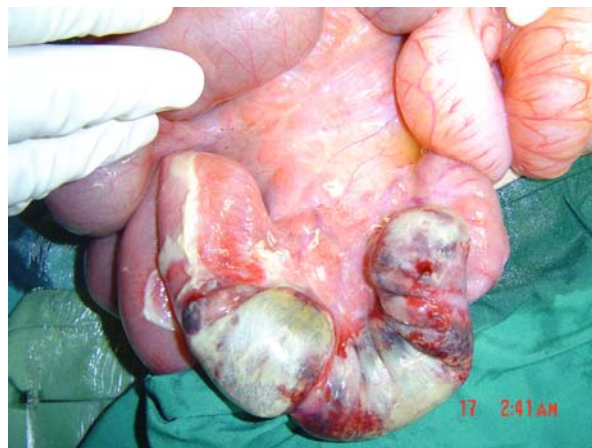

Figure 2. The necrotic bowel segment.

her acute abdomen. Just before operation, she had an arterial blood pH of 7.22, bicarbonate of 7.6 mmol/L; base deficit of -13 mEq/L, and a blood sugar of 290 mg/dL.

Under general anesthesia, midline incision was performed and abdominal wall layers were opened. During the operation, insulin was infused at a rate of 0.17 IU/kg/hr and appropriate IV fluid was also administered. There were some serous fluids in abdomen which were sucked.

During exploration, we found a 20 cm segment of ileum with necrotic changes just 10 cm to ileocecal valve (Figure 2). There was no perforation or fecal contamination in the peritoneal cavity.

The gangrenous portion of the bowel was resected and end-to-end anastomosis was performed. Histologic study showed necrosis of bowel wall (Figure 3).

In postoperation days, she was treated by fluid, insulin, cephazoline, and clindamycine.

On the fifth postoperative day, oral feeding

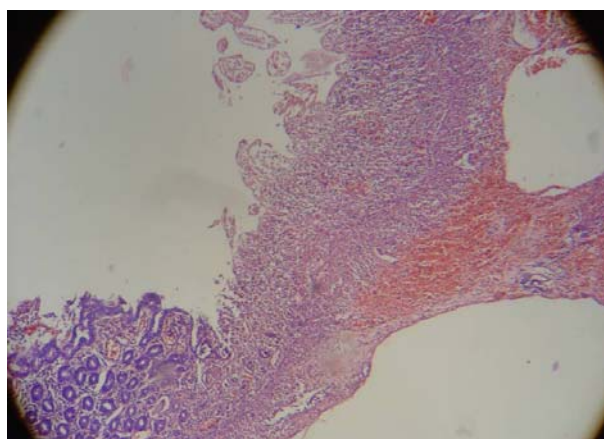


Figure 3. Histological findings of the necrotic bowel (H&E, ×100).

was started. She tolerated feeding well, and thereby she was discharged with a good general condition on the 15th day after operation.

Discussion

DKA is defined as a state of uncontrolled diabetes mellitus in which there is hyperglycemia (usually >300 mg/dL) with a significant acidemia (pH<7.3) and an elevation of total blood ketone body concentration.⁴ The diabetic hyperosmolar state is defined by a serum glucose >600 mg/dL and a serum osmolality >320 mosom/L.⁵ DKA-hyperosmolar is a potentially catastrophic emergency that may be occurs in IDDM.

Some patients exhibit a mixture of ketoacidosis and hyperosmolarity, which suggests that the two conditions may represent variants of a decompensated hyperglycemia that differ only by the magnitude of dehydration and the severity of acidosis. Infection remains the most important precipitating factor in the development of DKA and hyperglycemic hyperosmolarity syndrome (HHS). Other precipitating factors, especially for HHS include silent myocardial infarction, cerebrovascular accident, mesenteric ischemia and pancreatitis.⁶

Common presenting signs include fatigue or weakness, polydipsia, polyuria, nausea, alteration of consciousness, weight loss, vomiting, abdominal pain (only in DKA), dehydration, and finally coma. Presence of abdominal pain and gastric dilatation is associated with a more severe metabolic acidosis, hyperkalemia and ketosis.⁷

Caution needs to be taken with patients, who complain of abdominal pain on presentation, because the symptoms could be the result or an indication of a precipitating cause (particularly in younger patient) of DKA.

Further evaluation is necessary if this complaint dose not resolve with resolution of dehydration and metabolic acidosis.⁸

Many features of DKA and HHS predispose the patient to develop thrombosis. These factors include dehydration and contracted vascular volume, low cardiac output, increased blood viscosity, impairing blood flow, and a number of hemostatic changes.⁹

An acute increase in platelet aggregation and red blood cell rigidity increase in association with elevated blood glucose and decreased blood pH.¹⁰

DKA results in a prothrombotic state and activation of the vascular endothelium, which in turn predispose to cerebrovascular accidents.

The prompt recognition of DKA-hyperosmolar and simple institution of rapid rehydration have continued to reduce the mortality and complications. Bowel ischemia, if not detected and treated early, may result in perforation and eventually death. Therefore, it is important to carefully evaluate the cause of persistent abdominal pain and acidosis, and hemodynamic instability in a diabetic patient, after appropriate fluid and insulin administration, particularly when there is antecedent shock. So we should consider abdominal examination, radiographic evaluation and early surgical evaluation for bowel viability. Persistent acidosis or hemodynamic disturbance should alert the clinician to the possibility of a concomitant illness or complication of the DKA or its management.

References

- 1 Rosenbloom AL, Hanas R. Diabetic ketoacidosis (DKA): treatment guidelines. *Clin Pediatr (Phila)*. 1996; **35**: 261 – 266.
- 2 Felner I, White P. Improving management of diabetic ketoacidosis in children. *Pediatric*. 2001; **108**: 735 – 740.
- 3 Inward C, Chambers T. Fluid management in diabetic ketoacidosis. *Arch Dis Child*. 2002; **86**: 443 – 454.
- 4 George K, Alberti M. Diabetic acidosis. In: Becker L, ed. *Principles and Practice of Endocrinology and Metabolism*. USA: Lippincott, Williams and Wilkins; 2001: 438 – 450.
- 5 Wachtel TJ. Diabetic hyperosmolar state. *Clin Geriatr Med*. 1990; **6**: 797 – 806.
- 6 Chiasson JL, Aris-Jilwan N, Belanger R, Bertrand S, Beauregard H, Ekoe JM, et al. Diagnosis and treatment of diabetic ketoacidosis and the hyperglycemic hyperosmolar state. *CAMJ*. 2003; **168**: 859 – 866.
- 7 Kitabchi AE, Umpierrez GE, Murphy MB, Barrett EJ, Kreisberg RA, Malone JJ, et al. Hyperglycemic crisis in patients with diabetes mellitus. *Diabetic Care*. 2002; **25**: 5100 – 5108.
- 8 Guillermo E, Umpierrez GE, Murphy MB, abbas E, kitabchi AE. Diabetic ketoacidosis and hyperglycemic hyperosmolar syndrome. *Diabetic Spectrum*. 2002; **15**: 28 – 36.
- 9 Worly JM, Fortenberry JD, Hansen I, Chambliss CR, Stockwell J. Deep venous thrombosis in children with diabetic ketoacidosis and femoral central venous catheters. *Pediatrics*. 2004; **113**: 57 – 60.
- 10 Carl GF, Hoffman WH, Passmore GG, Truemper EJ, Lightsey AL, Cornwell PE, Jonah MH. Diabetic ketoacidosis promotes a prothrombotic state. *Endocr Res*. 2003; **29**: 73 – 82.