

## Original Article

## The Impact of Macular Laser Photocoagulation on Contrast Sensitivity Function in Patients with Clinically Significant Macular Edema

Mohammad-Sadegh Farahvash MD\*, Amir-Hossein Mahmoudi MD\*,  
 Mohammad-Mehdi Farahvash MD\*, Ali Tabatabaee MD\*, Mohammad Riazi MD\*,  
 Shiva Mohammadzadeh MD\*, Houshang Faghihi MD\*, Mehdi Nilli-Ahmadabadi MD\*,  
 Ahmad Mirshahi MD\*, Reza Karkhaneh MD\*, Zahra Aalami-Harandi MD\*,  
 Ahmad Javadian MD\*, Ali Abdolahi MD\*, Alireza Lashey MD\*

**Background:** Contrast sensitivity is an important aspect of visual function and is even more important for ordinary daily tasks than visual acuity. Contrast sensitivity function may be deteriorated to a significant level in diabetic retinopathy, especially in diabetic macular edema. The objective of this study was to determine the impact of macular laser photocoagulation—as the standard treatment of clinically significant macular edema—on contrast sensitivity function.

**Methods:** In a prospective noncomparative interventional case series, 17 patients with clinically significant bilateral macular edema and no history of prior macular laser photocoagulation were enrolled. Baseline visual acuity, contrast sensitivity function, and fluorescein angiography were obtained and reassessed three months after macular laser photocoagulation.

**Results:** Clinically significant macular edema resolved in 22 (65%) of 34 eyes, three months after their first session of macular laser photocoagulation. The mean pretreatment visual acuity was 24.5/40 (0.21 logMAR)  $\pm$ 10.3/40. Three months after macular photocoagulation, visual acuity remained stable in 19 eyes, decreased in 12 eyes, and increased in three eyes. The mean post-treatment visual acuity was 24/40 (0.24 logMAR)  $\pm$ 10.8/40. There was a statistically significant ( $P = 0.02$ ) decrease in visual acuity following laser therapy. In subgroup analysis, this decrease in visual acuity was only observed in those with unresolved clinically significant macular edema. The mean contrast sensitivity threshold increased in all spatial frequencies by three months after macular photocoagulation. The maximum rise was observed in the frequency of 6.4 cycles per degree in the mid range of frequencies, with a pretreatment mean of 9.41 dB and a post-treatment mean of 11.50 dB ( $P < 0.05$ ).

**Conclusion:** Contrast sensitivity function improved after macular laser photocoagulation in clinically significant macular edema patients.

*Archives of Iranian Medicine, Volume 11, Number 2, 2008: 143 – 147.*

**Keywords:** Clinically significant macular edema • contrast sensitivity function • diabetic retinopathy • macular photocoagulation

### Introduction

Contrast sensitivity determines the lowest contrast level which can be detected by a person for a given size target. Fourier

in 1822 showed that any visual scene can be described as the sum of elementary gratings each characterized by a spatial frequency, a contrast, an orientation, and a position or phase. The highest spatial frequency which can be perceived is in the order of 30 cycles per degree (cpd) which corresponds roughly to a visual acuity of 20/20.

Contrast sensitivity measures the two variables of size and contrast, while visual acuity measures only size. New data are now available which suggest that visual loss related to early vascular

**Authors' affiliation:** \*Department of Ophthalmology, Tehran University of Medical Sciences, Tehran, Iran.

**Corresponding author and reprints:** Mohammad-Sadegh Farahvash MD, No. 43, 5<sup>th</sup> Alley, Chehelsoton St., Fatemi Sq., Tehran 14316, Iran. E-mail: Farahva@yahoo.com.

Accepted for publication: 30 May 2007

damage in the eyes of diabetic patients can be detected by evaluation of contrast sensitivity.<sup>1,2</sup> Loss of contrast sensitivity may precede any clinically observable diabetic retinopathy.

Macular edema is a microvascular complication of diabetes mellitus defined as retinal thickening resulting from the accumulation of fluid in the retina. When it is associated with hard exudates, both retinal damage and permanent visual loss will occur.

The mechanism of loss of contrast sensitivity in diabetic macular edema is still not known well, although hyperglycemia-related changes of the retina, which result in accumulation of abnormal fluid, have been suggested.<sup>3-7</sup> Arend et al.<sup>8</sup> found that loss of contrast sensitivity correlates with enlargement of the foveal avascular zone.

According to the Early Treatment of Diabetic Retinopathy Study (ETDRS), macular photocoagulation (MPC) of the leaking microaneurysms and diffuse leaking areas responsible for the development of clinically significant macular edema (CSME) reduces the risk of moderate visual loss.<sup>9</sup> Moderate visual loss is defined as a doubling of the visual angle (e.g., a drop from 20/50 to 20/100), a drop of 15 or more letters on ETDRS visual acuity charts, or a drop of three or more lines of Snellen equivalent. These findings were shown during the first two years of the ETDRS study.

For the first time in Iran, we evaluated the influence of MPC on contrast sensitivity thresholds of patients with CSME and their sensitivity in the monitoring of the response to the treatment, at Farabi Eye Hospital.

## Patients and Methods

A total of 34 eyes of 17 patients with type II diabetes mellitus who had CSME and no history of prior MPC were enrolled into this study. All patients had nonproliferate diabetic retinopathy during the study. After taking baseline fluorescein angiograms, contrast sensitivity thresholds of patients were determined using Metrovision® with a high resolution cathodic ray tube (CRT) stimulator, a monitor 40 cm in diagonal length, and a spatial resolution of 1024×768 pixels. The stimulation field covered only one third of the surface area of the screen and was surrounded by a progressive transition area between the stimulation and the background to avoid border effects. Six

values of spatial frequencies for an examination distance of 350 cm were assessed; 25.6, 12.8, 6.4, 3.2, 1.6, and 0.8 cpd. We used the dynamic procedure with temporal modulation frequencies of 10 Hz. The average luminance was 80 – 90 cd/m<sup>2</sup> and was maintained constant except for very high contrast levels (>50%). Measures of contrast sensitivity were given in decibels (dB) where the 100% corresponded to 0 dB and the 0.1% contrast was considered equivalent to 30 dB—the lowest discernible contrast that corresponds to 20/20 visual acuity.

Contrast thresholds were measured with an ascending limit technique from a nonseen grating contrast level up to the patient's threshold of recognition. Contrast was increased progressively in 0.25 dB increments to avoid responses elicited by abrupt contrast changes. At first, presentation was made for each test without recording the response, allowing for patient training. Each measurement was repeated several times to evaluate the reproducibility of responses. The final graph indicated all the responses obtained for each stimulation. A curve which linked the average responses was generated for each spatial frequency.

The rationale for treating macular edema with laser photocoagulation was explained to the patients. After obtaining an informed consent, all patients underwent MPC. The leaking microaneurysms and areas of diffuse leakage were treated with focal and/or grid MPC patterns using frequency doubled Nd:YAG (532 nm) laser. Visual acuity, contrast sensitivity function, and fluorescein angiograms were reassessed three months after the first MPC treatment session.

## Results

Of the 34 eyes with CSME, 26 had diffuse macular edema and the remaining eight eyes had focal CSME. Three months after MPC, the edema resolved in 20 eyes; 14 eyes of the diffuse CSME cases and six of focal CSME.

The pretreatment mean±SD visual acuity was 24.5/40 (0.21 logMAR) ±10.3/40. Three months after MPC, visual acuity had remained stable in 19 eyes, decreased in 12, and increased in three eyes. The post-treatment mean±SD visual acuity was 24/40 (0.24 logMAR) ±10.8/40. Two-tailed Wilcoxon signed ranks test revealed a statistically significant decrease in visual acuity following

**Table 1.** Visual acuity and contrast sensitivity function thresholds before and after macular photocoagulation (MPC) in 34 eyes with clinically significant macular edema.

	Mean visual acuity (logMAR)	Mean contrast threshold, cycle per degree (dB)					
		0.8	1.6	3.2	6.4	12.8	25.6
Pre-MPC	24.5/40 (0.21)	(18.6)	(17.8)	(13.9)	(9.4)	(5.6)	(4.3)
Post-MPC	24/40 (0.24)	(19.4)	(17.9)	(15.1)	(11.5)	(6.2)	(5.4)

MPC ( $P=0.02$ ) (Table 1). When we analyzed the resolved and unresolved CSME cases separately, in the resolved CSME group, 12 eyes showed no change in visual acuity, five eyes had decreased visual acuity, and three eyes had improvements after MPC. Among the unresolved CSME patients, seven eyes showed no change in visual acuity, and in the remaining seven eyes, the visual acuity was decreased after MPC. The decrease in visual acuity was statistically significant only in the unresolved CSME group ( $P=0.16$ , Wilcoxon signed ranks test) (Table 2).

The mean contrast sensitivity threshold had increased in all frequencies three months after MPC. The maximum rise was observed in the frequency of 6.4 cpd (mid- range of frequencies), with a pre- and post-treatment mean of 9.41 dB and 11.50 dB, respectively. Analysis of contrast sensitivity by Wilcoxon signed ranks test revealed a statistically significant increase only in this frequency ( $P=0.041$ ). In subgroup analysis of resolved CSME patients, the maximum rise in contrast sensitivity threshold was around the frequency of 6.4 cpd (pre- and post-treatment mean of 9.85 dB and 12.40 dB, respectively). Wilcoxon signed ranks test showed a significant improvement in this frequency ( $P=0.024$ ) (Table 3 and Figure 1). Contrast sensitivity threshold had increased in all other frequencies, but the improvements were not statistically significant. In the unresolved CSME subgroup, increased mean contrast sensitivity threshold was seen in frequencies of 0.8, 3.2, 6.4, and 25.6 cpd; these changes were not statistically significant though.

In Figure 2, an abnormal contrast sensitivity function curve is compared with a near normal person. There was a severe generalized depression of contrast thresholds especially in mid-frequencies on three successive tests.

**Table 2.** Visual acuity and contrast sensitivity function thresholds before and after macular photocoagulation (MPC) in patients with unresolved clinically significant macular edema.

	Mean visual acuity (logMAR)	Mean contrast threshold, cycle per degree (dB)					
		0.8	1.6	3.2	6.4	12.8	25.6
Pre-MPC	26.5/40 (0.18)	(16.7)	(15.3)	(11.9)	(8.8)	(5.9)	(3.9)
Post-MPC	23.7/40 (0.23)	(16.9)	(14.6)	(12.9)	(10.2)	(4.8)	(6.5)

## Discussion

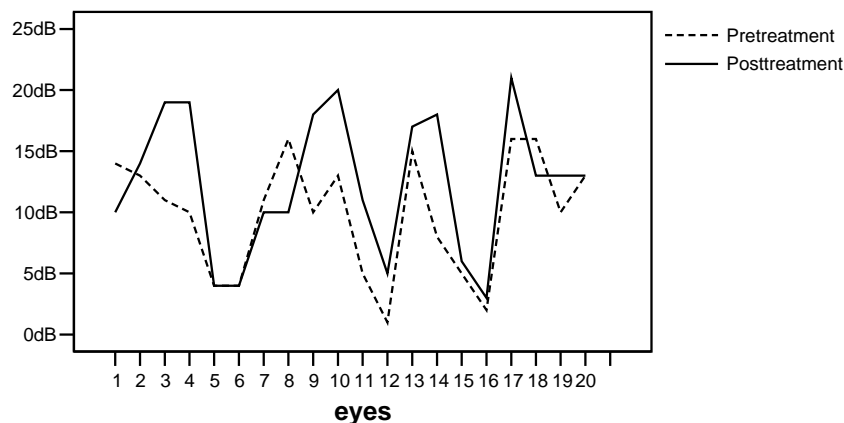
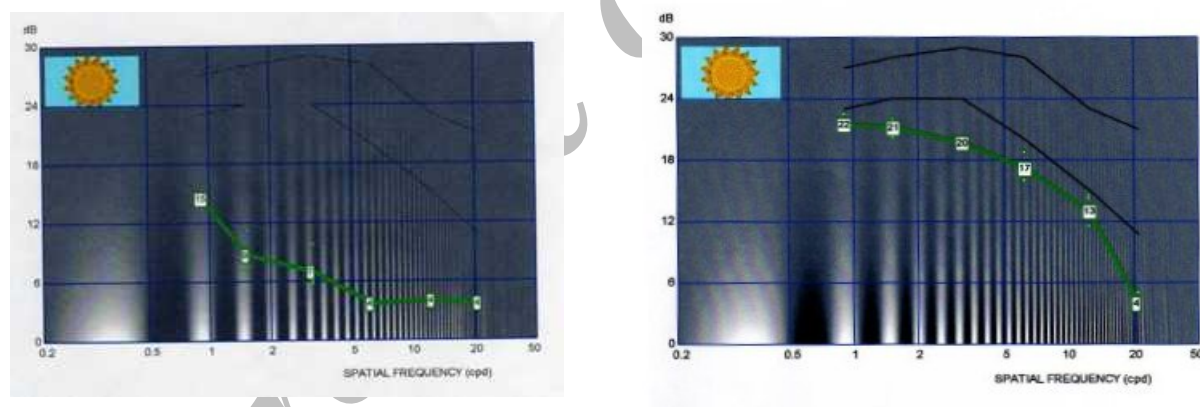
For the first time in Iran, we embarked on evaluating contrast sensitivity function after MPC in CSME diabetic patients. MPC is the standard treatment of CSME in diabetic patients. If applied appropriately, it usually leads to the resolution of edema and prevents moderate visual loss. Under certain circumstances, it increases the chance of visual improvement.

Patients who have undergone MPC, occasionally complain of blurred vision following MPC, although on examination, they continue to maintain their pretreatment visual acuity. The reverse situation can also happen. Sometimes, patients who have undergone MPC claim an improvement in their vision, despite the absence of a recordable change in their visual acuity.<sup>10</sup> These improvements have been disregarded as being subjective due to our inability to document any improvement or deterioration in the visual function. However, it is evident that visual acuity constitutes only a small part at the higher end of the spectrum of visual function and evaluates the ability to resolve fine details of high (100%) contrast. It does not adequately describe a person's ability to see large, low contrast objects such as faces. In daily activities, the vision in the low contrast domain is as important as that in the high contrast domain. So, assessment of contrast sensitivity is relevant for a more complete analysis of visual performance and is complementary to the evaluation of visual acuity.

Hellstedt et al.<sup>7</sup> suggested that contrast sensitivity is a sensitive indicator of changes in diabetic retinopathy and macular edema, especially at low- to mid- range spatial frequencies. Contrast sensitivity function may be changed after MPC for diabetic retinopathy. Midena et al.<sup>11</sup> studied the

**Table 3.** Results of visual acuity and contrast sensitivity function thresholds before and after macular photocoagulation (MPC) in patients with resolved clinically significant macular edema.

	Mean visual acuity (logMAR)	Mean contrast threshold, cycle per degree (dB)					
		0.8	1.6	3.2	6.4	12.8	25.6
Pre-MPC	25/40 (0.20)	(20)	(18.7)	(15.3)	(9.9)	(5.8)	(4.9)
Post-MPC	24.5/40 (0.21)	(21.2)	(20.2)	(16.7)	(12.4)	(7.5)	(4.7)

**Figure 1.** Changes in contrast sensitivity thresholds at a spatial frequency of 6.4 cycles per degree before and after macular photocoagulation in resolved clinically significant macular edema group.**Figure 2.** Abnormal contrast thresholds of the right eye of a 52-year-old patient with clinically significant macular edema (left). A near normal contrast sensitivity graph (right).

effect of both focal and grid laser therapy on the contrast sensitivity of patients with diabetic macular edema and found that contrast sensitivity was improved at the last follow-up but never normalized. The same finding was reported by Talwar et al.<sup>10</sup> in a prospective noncomparative interventional study of 14 eyes with CSME. They concluded that focal argon laser photocoagulation in CSME in diabetics helped improve contrast sensitivity and stabilized the visual acuity. They also stated that the changes in contrast sensitivity and visual acuity were independent of each other. Our findings in this study, regarding the change in

contrast sensitivity function, are similar to those reported by Midena et al. and Talwar et al. Compared with those studies, we evaluated the effect of both focal and grid MPC on contrast sensitivity thresholds; we also studied more patients. The greatest benefit of MPC on contrast sensitivity threshold was observed in mid - frequencies of 6.4 cpd in which the neurosensory system is the most sensitive. This benefit appeared only in resolved CSME patients, i.e., in those who responded to treatment with MPC. The overall visual acuity deteriorated after MPC, but this change was statistically significant only in those

with unresolved CSME, i.e., the patients who did not respond to MPC. If we analyze the slope of visual loss in patients with CSME according to the ETDRS, it is evident that the MPC had indeed a protective effect on main-training visual acuity, and if we had a control group, this effect could have been detected more clearly.

The most important finding of this study was that, although the follow-up time was limited to almost three months, contrast sensitivity function began to improve during this short period. This may indicate that contrast sensitivity function is probably a more sensitive parameter than visual acuity for early monitoring of macular edema after MPC in diabetic patients. For a better evaluation of changes in contrast sensitivity during follow-up of patients with CSME, larger studies with longer follow-ups are recommended.

### Acknowledgment

*The study was supported by grants from the Deputy of Research of Tehran University of Medical Sciences and the Eye Research Center.*

### References

- 1 Khosla PK, Talwar D, Tewari HK. Contrast sensitivity changes in background retinopathy. *Diabetes Care*.1991; **13**: 34 – 40.
- 2 Di Leo MAS, Caputo S, Falsini B. Nonselective loss of contrast sensitivity in visual system testing in early type I diabetes. *Diabetes Care*.1992; **15**: 620 – 625.
- 3 Bresnick GH. Diabetic maculopathy: a critical review highlighting diffuse macular edema. *Ophthalmology*. 1983; **90**: 1301 – 1317
- 4 Dosso AA, Bonvin ER, Morel Y. Risk factors associated with contrast sensitivity loss in diabetic patients. *Graefe's Arch Clin Exp Ophthalmol*. 1996; **234**: 300 – 305.
- 5 Ghafour IM, Foulds WS, Allan D. Contrast sensitivity in diabetic subjects with and without retinopathy. *Br J Ophthalmol*. 1982; **66**: 492 – 495.
- 6 Sala SD, Bertoni G, Somazzi L. Impaired contrast sensitivity with and without retinopathy: a new technique for rapid assessment. *Br J Ophthalmol*. 1985; **69**: 136 – 142.
- 7 Hellstedt T, Kaaja R, Teramo K. Contrast sensitivity in diabetic pregnancy. *Graefe's Arch Clin Exp Ophthalmol*. 1997; **235**: 70 – 75.
- 8 Arend O, Remky A, Evans D. Contrast sensitivity loss is coupled with capillary dropout in patients with diabetes. *Invest Ophthalmol Vis Sci*. 1997; **38**: 1819 – 1824.
- 9 Early Treatment Diabetic Retinopathy Study Research Group. Focal photocoagulation treatment of diabetic macular edema. Relationship of treatment to fluorescein angiographic and other retinal characteristics at baseline: ETDRS Report 19. *Arch Ophthalmol*. 1995; **113**: 1144 – 1155.
- 10 Talwar D, Sharma N, Pai A, Azad RV, Kohli A, Virdi PS. Contrast sensitivity following focal laser photocoagulation in clinically significant macular edema due to diabetic retinopathy. *Clin Exp Ophthalmol*. 2001; **29**: 17 – 21.
- 11 Midena E, Segato T, Bottin G, Piermarocchi S, Fregona I. The effect on the macular function of laser photocoagulation for diabetic macular edema. *Graefe's Arch Clin Exp Ophthalmol*. 1992; **230**: 162 – 165.