
Brief Report

Intraoperative Findings in Revision Chronic Otitis Media Surgery

Abolhassan Faramarzi MD*, Masoud Motasaddi-Zarandy MD**,
 Mohammad-Taghi Khorsandi MD**

In this study, we reviewed the surgical findings in a series of revision tympanomastoidectomy to determine the most common causes of failure in chronic otitis media surgery.

The intraoperative findings at revision mastoidectomy with tympanoplasty of 116 patients were analyzed. The most common sites of pathologic tissue at revision surgery (with cholesteatoma and/ or granulation tissue) were unexenterated cells of the sinodural angle. The most common mechanical cause of retention of debris in canal wall down procedures was facial ridge.

Archives of Iranian Medicine, Volume 11, Number 2, 2008:196 -199.

Keywords: Chronic otitis media • mastoidectomy • tympanomastoidectomy • tympanoplasty

Introduction

In developing countries the largest and most widely varied domain within otology is the treatment of chronic otitis media.

Chronic otitis media ranges from limited foci in the tympanic cavity to extensive involvement of the temporal bone with its various complications.

Literature is replete with reports on the merits of the two major surgical procedures that address these problems: the canal wall down (open-cavity) and the canal wall up (closed-cavity) techniques, with or without second-look surgery.¹

In this study, we reviewed the surgical findings in a series of revision tympanomastoidectomy to determine the most common causes of failure in chronic otitis media surgery.

Patients and Methods

We conducted a cross-sectional study on 116 ears of 116 patients who had been referred and

admitted at the Department Otolaryngology, Head, and Neck Surgery, Amiralam Hospital affiliated to Tehran University of Medical Sciences, Tehran, Iran. The patients were diagnosed as having recurrent chronic otitis media and were referred for revision mastoidectomy. The operations were performed between June 2000 and March 2006. First, 66 patients were identified through a retrospective chart review. These cases were operated between June 2000 and March 2004. Of these patients' charts, nine were omitted because of incomplete information. Then, 59 patients were reviewed prospectively. They were operated between April 2004 and March 2006. Finally, our series consisted of 116 patients. The follow-up period was 12 months in 26 patients (22.41%), 18 months in seven patients (6.01%), and 24 months in 83 patients (71.55%). The intraoperative findings at revision mastoidectomy with tympanoplasty of all 116 patients were analyzed.

All revision procedures were performed by attending surgeons of the ENT Department of Amiralam Hospital and otology fellows at this referral center.

Fifty-eight cases (50%) had undergone primary previous surgeries at this center. The surgical procedures were performed based on the basic principles of otologic surgery. Assessment of statistical significance was done using the χ^2 and Fisher's exact test.

Authors' affiliations: *Department of Otolaryngology, Shiraz University of Medical Sciences, Shiraz, **Department of Otolaryngology, Department of Otolaryngology, Tehran University of Medical Sciences, Tehran, Iran.

•Corresponding author and reprints: Masoud Motasaddi-Zarandy MD, Department of Otolaryngology, ENT Research Center, Amiralam Hospital, Sadi Ave., Tehran, Iran.

Tel: +98-216-670-3037, Fax: +98-216-672-9672,
 E-mail: motesadi@sina.tums.ac.ir

Accepted for publication: 27 December 2006

Results

The age of the patients ranged from 10 to 73 years with a mean of 29.69 years (± 12.46). There were 59 men and 57 women. Male to female ratio was 1.03. There were 68 right ears (58.62%) and 48 left ears (41.37%). The number of previous operations was one in 98 patients (84.5%), two operations in 10 patients (8.6%), three in six patients (5.2%), and four operations in two patients (1.7%).

The types of previous operations included canal wall up in 57 ears (49.13%), canal wall down in 55 ears (47.4%), and radical mastoidectomy in four ears (3.44%). The ratio of canal wall down to canal wall up was 0.96. In those patients who were originally treated with an intact canal wall technique (n=57), approximately 28 ears (49.12%) were turned into a canal wall down technique because of residual or recurrent cholesteatoma.

The type of revision procedure was canal wall up in 28 ears (24.13%), canal wall down in 81 ears (69.83%), and radical mastoidectomy in seven ears (6.04%). The ratio of canal wall down to canal wall up procedures was 2.89.

In these 116 cases of revision surgery, 17 ears (14.85%) had only tympanic membrane perforation, normal or only mildly hypertrophic mucosa of the middle ear and mastoid cavity. Cholesteatoma was detected in 71 ears (61.20%) and granulation tissue (without cholesteatoma) in 28 ears (24.13%).

The most common type of pathologic tissue was cholesteatoma in both previous canal wall up and canal wall down groups (including radical mastoidectomy). Cholesteatoma was found in

about 71% of the canal wall down (including radical procedures) and 49% of canal wall up procedures requiring revision surgery.

Potential predisposing conditions and sites of pathology found intraoperatively in the remaining 99 ears are shown in Table 1.

In both previous canal wall up and canal wall down procedures, the most common site of pathologic tissue at revision surgery (with cholesteatoma and/or granulation tissue) was unexenterated cells of the sinodural angle (28.28%). Other frequent sites for pathologic tissue were the attic (about 23%), antrum, anterior attic recess, tip of the mastoid (about 13% each), sinus tympani (about 10%), and hypotympanum (about 5%). The most common mechanical cause of debris retention in canal wall down procedures was high facial ridge. It was present in about 53% of all canal wall down operations (including radical procedures).

Inadequate canaloplasty and/or meatoplasty were predisposing mechanical causes for retention of debris in 23 ears (about 23%). Canaloplasty was inadequate in seven out of the 46 ears (about 15%) with previous canal wall up procedures associated with pathologic tissue. Overall, inadequate meatoplasty was seen in 16 out of 53 ears (about 30%) with previous canal wall down procedures.

Discussion

The most common anatomical site of pathologic tissue was the sinodural angle in both canal wall up and canal wall down procedures. Other frequent sites of unexenterated cells were the attic, anterior attic recess, antrum, and tip of mastoid and sinus tympani. High facial ridge was

Table 1. Percentage of the potential predisposing factors and sites of pathology found intraoperatively (n= 99 ears).

	Revision operative findings	Sinodural angle	High facial ridge	Attic	Erosion of posterior canal wall	Mastoid Tip	Anterior attic recess	Antrum	Sinus tympani	Erosion of mastoid cortex	Dehiscent dural plate	Hypotympanum	Dehiscent sigmoid sinus plate
Type of previous operations	*CWU (n=46)	10 21.73	—	17 37	15 32.6	2 4.3	5 10.9	9 19.6	2 4.3	5 10.9	5 10.9	4 8.7	2 4.3
	**CWD (n=53)	18 33.96	26 49.1	6 11.3	—	11 9.5	8 15.1	4 3.44	8 15.1	4 3.44	4 3.44	1 0.86	1 0.86
	Total (n=99)	28†	26	23	15	13	13	13	10	9	9	5	3

*CWU = canal wall up; **CWD = canal wall down (including 3 cases with radical procedure); †percentages nearly equal the above numbers.

present in about half of the cases with previously canal wall down procedures. Some authors believe that high facial ridge is the most common reason for revision mastoid surgery in chronic otitis media and is known as a “beginner hump”.²

In a review of 34 patients who required revision radical mastoidectomy, based on Nodol’s article, Ohrt found the principal causes of recurrent drainage without cholesteatoma were high facial ridge and inadequate meatoplasty. Schuknecht and Rambo also stressed the need to remove cells of tegmental, and perisinal areas of the temporal bone. Cheesman found that the principal causes of failure to achieve a dry ear in mastoidectomy as performed by trainees were inadequate meatoplasty, high facial ridge, and inadequate removal of air cells that did not open into the middle ear, especially cells of the sinodural angle and tip. In Nadol’s study, in both canal wall up and canal wall down procedures, the most common sites for granulation tissue were unexenterated cells of the tegmen and sinodural angle.³

Figure 1 shows the sites of the disease in the mastoid as found during revision mastoidectomy by Veldman and Braunius.⁴ The disease was found in the retrofacial region in 62% of cases, the labyrinthine region in 46%, the tegmen in 48%, the sigmoid sinus region in 61%, the mastoid tip in 50%, and the sinodural angle in 38%.

Bhatia and co-workers⁵ reviewed patients referred for revision canal wall down mastoidectomy. The facial ridge was inadequately low in 67%, the external canal/meatus was stenotic in 64%, and there was a bony overhang in 29%, and inadequate meatoplasty in 59% of the cases.

In this study, about 49.12% of the previous intact canal wall procedures were turned into the canal wall down technique at revision surgery. In Veldman and Braunius’ study,⁴ 30% of the previous canal wall up procedures turned into canal wall down at revision surgery. We agree with O’Leary and Veldman⁶ who concluded that in revision surgery, the surgical technique appears to be a greater determinant of postoperative success than the type of procedure or the disease itself. Cholesteatoma seen at revision (residual or recurrent) can be controlled by either intact canal wall or canal wall down procedures although it is important to note that an intact canal wall revision may present with cholesteatoma at a later time.^{5,6} We found cholesteatoma in about 61% of cases.

Therefore, in our study the higher incidence of

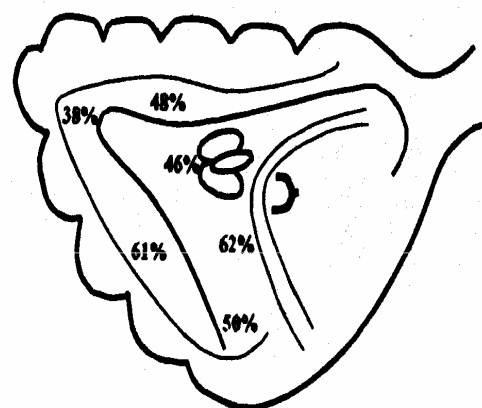


Figure 1. Site of disease in the mastoid as found during revision mastoidectomy by Veldman and Braunius.⁴

cholesteatoma in general, and the higher incidence of cholesteatoma in previous canal wall down procedures, is probably related to residual cholesteatoma because of persistent pathologic processes in unexenterated cells and ignoring the importance of second look operations.

The incidence of previous canal wall up and canal wall down procedures was nearly equal, but in the total of 116 revision surgeries, canal wall down procedures were performed about three times more frequently than canal wall up procedures. In other centers such as Erasmus University Medical Center in Rotterdam, radical revision mastoidectomy has been performed since 1991 for treating chronically draining ears after revision mastoid surgery for chronic otitis media.⁷ Others believe that canal wall up is technically more demanding and the modified radical mastoidectomy is recommended for the occasion of confronting a cholesteatoma extending into the attic, antrum, or mastoid process.⁷ We agree that canal wall up and canal wall down mastoidectomy are the most commonly performed procedures in the setting of chronic otitis media surgery, and other techniques such as radical mastoidectomy and modified radical mastoidectomy are applied more rarely.

In conclusion, we believe that in revision chronic otitis media surgery, the judgment and technical ability of a well-trained experienced surgeon are major factors affecting the outcome, because the most important single factor for the failure of the surgery in chronic otitis media is inadequate removal of cell tracts meticulously, especially those of the sinodural angle.

References

- 1 Megerian CA, Cosenza MJ, Meyer SE. Revision tympanomastoid surgery. *Ear Nose Throat J.* 2002; **81**: 718 – 720, 722, 725 – 726.
- 2 Kriskovich M, Shelton C. Surgical treatment of chronic otitis media and cholesteatoma. In: Canalis RF, Lambert PR. *The Ear: Comprehensive Otology*. Philadelphia: Lippincott Williams and Wilkins; 2000: 447 – 465.
- 3 Nadol JR JB. Causes of failure of mastoidectomy for chronic otitis media. *Laryngoscope.* 1985; **95**: 410 – 413.
- 4 Veldman JE, Braunius WW. Revision surgery for chronic otitis media: a learning experience. Report on 389 cases with a long-term follow-up. *Ann Otol Rhinol Laryngol.* 1998; **107**: 486 – 491.
- 5 Bhatia S, Karmarkar S, DeDonato G, Mutlu C, Taibah A, Russo A, et al. Canal wall down mastoidectomy: causes of failure; pitfalls and their management. *J Laryngol Otol.* 1995; **109**: 583 – 589.
- 6 O'Leary S, Veldman E. Revision surgery for chronic otitis media: recurrent-residual disease and hearing. *J Laryngol Otol.* 2002; **116**: 996 – 1000.
- 7 Kveton JF. Open cavity mastoid operations. In: Glasscock III ME, Gulya AG, eds. *Glasscock-Shambangh Surgery of the Ear*. 5th ed. Hamilton, Ont.; New York: BC Decker; 2003: 499 – 516.

Archive of SID