

---

## Case Report

---

# Squamous Cell Carcinoma of the Tongue in a 13-Year-Old Boy

Maryam Seyedmajidi DMD\*, Maryam Faizabadi DMD\*

**Squamous cell carcinoma of the tongue is uncommon among children and teenagers. Most commonly, squamous cell carcinoma of the head and neck presents during the fifth and sixth decades of life in patients with a long history of tobacco and alcohol use. The rarity of this lesion in young patients implies that clinicians might not include it in the differential diagnoses. In general, carcinoma of the oral cavity in young people is reported to be particularly aggressive and carry a poor prognosis. A case of carcinoma of the tongue in a 13-year-old boy is presented in this report.**

*Archives of Iranian Medicine, Volume 11, Number 3, 2008: 341 – 343.*

**Keywords:** Carcinoma • squamous cell • tongue neoplasms

### Introduction

**S**quamous cell carcinoma (SCC) represents about 90 – 95% of all malignant neoplasms of the oral cavity. It is located mainly in the tongue, especially in the lateral posterior border. It generally affects men over the age of 50, mostly with a history of high tobacco and alcohol consumption.<sup>1,2</sup> SCC rarely occurs in the young or under the age of 40. In this group, the real influence of carcinogenic factors, mainly alcohol and tobacco, is widely debated. Some authors argue that these substances, recognized as carcinogenic in older patients, may also be related to the etiology of SCC in youngsters.<sup>2,3</sup> Others, however, report that many of these patients never smoked or drank alcoholic beverages, or the duration of exposure to these agents would be too short to induce malignant transformation.<sup>4,5</sup>

Locoregional recurrences and prognosis of SCC in youngsters are also controversial matters. Patients belonging to younger age ranges are considered to have more aggressive diseases compared to patients in the older age ranges.<sup>3,6,7</sup>

Other investigators, nevertheless, have found a similar prognosis for both evaluated age ranges.<sup>1,8</sup>

The clinical aspect of SCC of the oral mucosa seems not to present distinguishing features for any age range. The classical feature of the lesion is a persistent ulceration with hardening and peripheral infiltration, with or without vegetations and red or whitish staining. The predominant location is the lateral border of the tongue or oral floor.

The importance of this report lies in the rarity of SCC in young patients and in the study of etiologic and differential diagnosis of such a disease in this age group.

### Case Report

A 13-year-old boy, from Amol (North of Iran), was referred to the Oral and Maxillofacial Surgery Clinic, affiliated to Babol University of Medical Sciences in February 2005 with an exophytic pink-to red-colored soft tissue lesion at the tip of his tongue. The lesion had appeared about two months earlier without any pain or neurosensory complaints. He had used antibiotics and mouthwash for a week but the lesion had enlarged. One month before admission, an incisional biopsy had been carried out by an otorhinolaryngologist, which was suggestive of a SCC-like lesion. The patient had facial hyperpigmentation but no cervical lymph node enlargement was detected. Medical history of the patient had no important points and he denied any history of smoking,

---

**Authors' affiliation:** \*Department of Oral and Maxillofacial Pathology, Dental Faculty, Babol University of Medical Sciences, Babol, Mazandaran, Iran.

**Corresponding author and reprints:** Maryam Seyedmajidi DMD, Department of Oral and Maxillofacial Pathology, Dental Faculty, Babol University of Medical Sciences, Babol, Mazandaran, Iran.

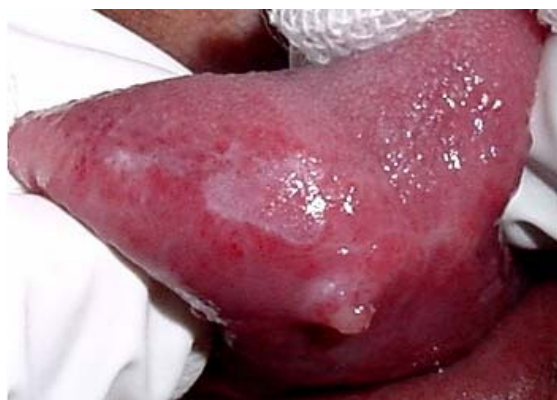Tel: +98-111-229-1408 Ext: 116, Fax: +98-111-229-1093,  
E-mail: ms\_majidi79@yahoo.com

Accepted for publication: 16 May 2007

alcohol consumption, or any other harmful habits such as tobacco chewing. Differential diagnoses were papilloma and pyogenic granuloma. He was referred to the Dental Faculty of Babol University of Medical Sciences and on clinical examination, a pink- to red- colored exophytic lesion, 0.5 cm in diameter and surrounded by a leukoplakic area and white striae, was observed at the tip of the tongue (Figure 1).

A biopsy carried out by an oral and maxillofacial surgeon showed a moderate dysplasia with free margins (Figure 2). Then, the first biopsy was reviewed by an oral and maxillofacial pathologist, which showed a moderate- to well-differentiated SCC (Figure 3).

After the second biopsy, the patient was referred to a genetic specialist and an oncologist



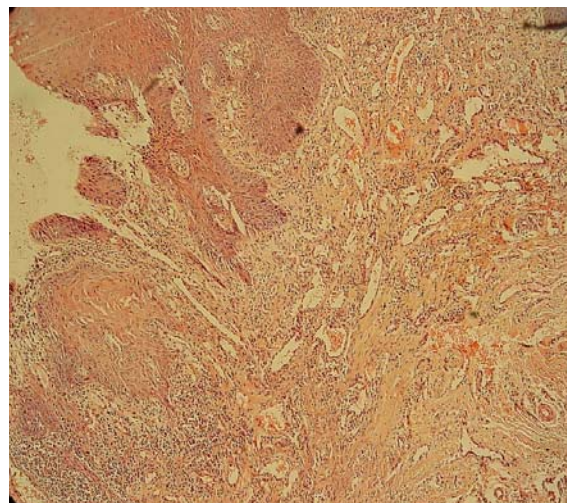
**Figure 1.** Pink- to red-colored exophytic lesion, 0.5 cm in the largest diameter, surrounded by a leukoplakic area and white striae, observed at the tip of the tongue.

for evaluation and treatment. Immunologic and genetic analyses for xeroderma pigmentosum, keratitis-ichthyosis-deafness (KID) syndrome, and Fanconi anemia were negative and there was no specific family history for such diseases.

Ten months later, the tumor recurred, so it was resected with enough safe margins and after five months the patient had a normal life without pain and lymphadenopathy (Figure 4).

## Discussion

SCC is not a frequent event in young patients. Only 1 – 6% of patients with SCC are under the age of 40. The occurrence in children and adolescents is rare.<sup>2,5,7</sup> Characterization of young patients with SCC of head and neck is arbitrary. Most authors consider young patients with SCC as those under 40-year-old,<sup>1,5,6</sup> however, others use

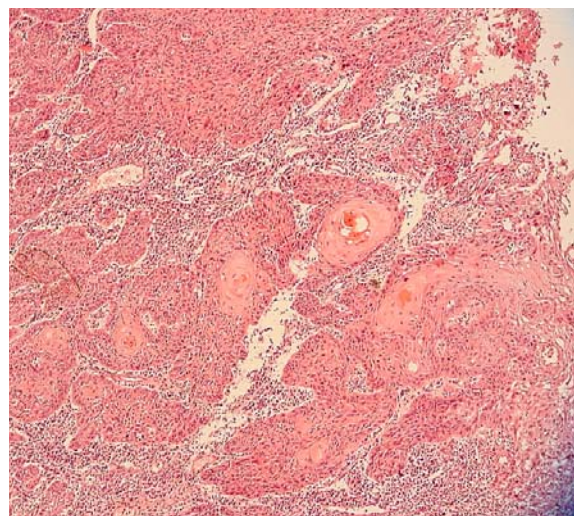


**Figure 2.** Moderate dysplasia (second biopsy) (H&E staining  $\times 100$ ).

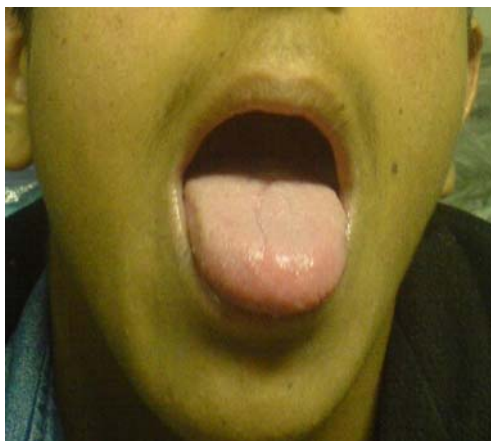under 20 or 30 years as the reference ages.<sup>3,4</sup> The average age of cases presented in the literature as young bearers of SCC ranges from 30.8 to 34.2 years, with a male predominance.<sup>1,5,8</sup>

The tongue is the most common site for oral cancers in patients under 40, which is similar to that observed in older patients.<sup>5</sup> The clinical manifestation of SCC in young patients has no distinguishing features from that of the older patients; nevertheless, many clinicians tend not to include SCC as a diagnosis in young patients, simply because such a disease is not compatible with their age range.<sup>7</sup> Reports in the literature about tongue carcinoma in childhood or adolescence are rare, and the prognosis is poor.<sup>7</sup> We found only 18 cases aged 20 years or younger.

Generally the tumor is on the lateral border of



**Figure 3.** Moderately- to well-differentiated squamous cell carcinoma (first biopsy) (H&E staining  $\times 100$ ).



**Figure 4.** The patient's tongue after the last surgery.

the tongue but in our case, the tumor was at the tip of the tongue. There is no significant statistical difference in gender.

The etiologic factors of SCC in young patients have been widely debated. The possibility of the existence of a carcinogenic effect of tobacco and alcohol in young patients is low, because in this group the exposure time would be relatively short for establishment of a cause-effect relation. Thus, other factors should be investigated in order to explain the etiology of SCC in young patients. These factors include a genetic predisposition, previous viral infections, feeding habits, immunodeficiency states, occupational exposure to carcinogenic elements, socioeconomic status, and oral hygiene.<sup>2</sup>

In the present report, the patient was very young and did not report any smoking or drinking habits. His medical history was not significant either. In this case, immunologic and genetic analyses were negative and there was no specific family history.

There is still controversy regarding the prognosis of SCC in young patients. Some authors consider the lesion to be particularly aggressive in the young, thus with a worse prognosis compared with that of older patients.<sup>6,7</sup> Some studies have shown that young patients present a greater

locoregional recurrence rate and a lower survival rate,<sup>6,7</sup> whereas others have described a similar prognosis for both age ranges.<sup>1,8</sup> Therefore, some authors have indicated a more aggressive treatment for SCC in young patients,<sup>6,7</sup> while others recommend that the treatment should be instituted in a similar fashion to those with older age.<sup>9</sup>

Oral SCC is rare in young patients, and observation of such cases warrants careful clinical study along with an analysis of etiologic factors. Proper treatment is also equally important in the care of these patients.

## References

- 1 Friedlander PL, Schantz SP, Shaha AR, Yu G, Shah JP. Squamous cell carcinoma of the tongue in young patients: a matched-pair analysis. *Head Neck*. 1998; **20**: 363 – 368.
- 2 Llewellyn CD, Johnson NW, Warnakulasuriya KAAS. Risk factors for squamous cell carcinoma of the oral cavity in young people—a comprehensive literature review. *Oral Oncol*. 2001; **37**: 401 – 418.
- 3 Oliver RJ, Dearing J, Hindle I. Oral cancer in young adults: report of three cases and review of the literature. *Br Dent J*. 2000; **188**: 362 – 365.
- 4 Sankaranarayanan R, Najeeb-Mohideen M, Krishnan-Nair M, Padmanabhan TK. Aetiology of oral cancer in patients <30 years of age. *Br J Cancer*. 1989; **59**: 439 – 440.
- 5 Burzynski NJ, Flynn MB, Faller NM, Ragsdale TL. Squamous cell carcinoma of the upper aerodigestive tract in patients 40 years of age and younger. *Oral Surg Oral Med Oral Pathol*. 1992; **74**: 404 – 408.
- 6 Sarkaria JN, Harari PM. Oral tongue cancer in young adults less than 40 years of age: rationale for aggressive therapy. *Head Neck*. 1994; **16**: 107 – 111.
- 7 Torossian JM, Baziat JL, Philip T, Bejui FT. Squamous cell carcinoma of the tongue in a 13-years-old boy. *J Oral Maxillofac Surg*. 2000; **58**: 1407 – 1410.
- 8 Schantz SP, Byers RM, Goepfert H, Shallenberger RC, Beddingfield N. The implication of tobacco use in the young adult with head and neck cancer. *Cancer*. 1988; **62**: 1374 – 1380.
- 9 Pitman KT, Johnson JT, Wagner RL, Myers EN. Cancer of the tongue in patients less than forty. *Head Neck*. 2000; **22**: 297 – 302.