
Case Report

Wide Spectrum of Clinical Features in a Case of Arthrogryposis-Renal Tubular Dysfunction-Cholestasis Syndrome

Firouzeh Nili MD*, Parvin Akbari-Asbaghe MD**,
Zohreh Oloomi-Yazdi MD***, Niloofar Hadjizadeh MD†,
Fatemeh Nayeri MD*, Elaheh Amini MD*, Shahla Bahremand MD‡,

Arthrogryposis-renal tubular dysfunction-cholestasis syndrome is a rare multisystem disorder, originally described in 1973 and to date only 62 patients have been reported. Herein, we reported on a neonate with arthrogryposis-renal tubular dysfunction-cholestasis syndrome presenting very early after birth. Recurrent febrile illnesses, failure to thrive, ichthyosis, hypothyroidism, and bilateral hearing loss were among other associated findings. Blood films revealed abnormally large platelets. Polyhydramnios, hybrid type of renal tubular acidosis and hypothyroidism found in this case are not usually seen. We propose to expand the acronym of this syndrome and name it as arthrogryposis-renal dysfunction-cholestasis-hypothyroidism-ichthyosis-deafness or dysmorphic features syndrome.

Archives of Iranian Medicine, Volume 11, Number 5, 2008: 569 – 572.

Keywords: Arthrogryposis • cholestasis • renal tubular acidosis • syndrome

Introduction

Arthrogryposis-renal tubular dysfunction-cholestasis (ARC) syndrome (OMIM 208085) is a rare multisystem disorder and to date only 62 patients have been reported. Almost half of the patients who underwent diagnostic organ biopsy developed life-threatening hemorrhage.¹ Although, the pedigrees of patients supported an autosomal recessive pattern of inheritance, the genetic basis for this syndrome is still unknown.² Gissen et al. recently identified a mutation in VPS33B on chromosome 15q26.1 which involves intracellular protein trafficking.¹

Herein, we reported on the first case of ARC syndrome diagnosed in Iran.

Case Report

A female neonate, weighing 3600 g, was born at 37 weeks of gestation by cesarean section for breech presentation. The parents were first-degree cousins of Persian origin. The family had several consanguineous marriages and two cousins had died in the neonatal period of an unknown etiology. The pregnancy was complicated by polyhydramnios and prolonged rupture of membranes. The neonate was admitted right after the birth with generalized hypotonia, poor feeding, and tachypnea. The baby had a high arched palate, redundant posterior skin folds in the neck, prominent occiput, and rocker bottom feet. There was generalized hypotonia, hepatomegaly, and multiple contractures including talipes calcaneovalgus, dislocated hips, and radial deviation of the wrist (Figures 1 and 2). Within 72 hours, the neonate developed fever, dehydration, and hyperchloremic metabolic acidosis with slightly elevated blood urea nitrogen and creatinine levels. Serum anion gap was within the normal ranges and investigations disclosed concomitant types 1 and 2 renal tubular acidosis. Although she was not a collodion baby at birth, she had unusual

Authors' affiliations: *Division of Neonatology, **Division of Pediatric Cardiology, ***Division of Pediatric Hematology, †Division of Pediatric Nephrology, ‡Division of Pediatric Gastroenterology, Department of Pediatrics, Vali-e-Asr Hospital, Tehran, Iran..

•Corresponding author and reprints: Zohreh Oloomi MD, Division of Pediatric Nephrology, Department of Pediatrics, Vali-e-Asr Hospital, Tehran, Iran.

Tel: +98-212-283-2200, Fax: +98-216-692-9977,

E-mail: z.oloomi@yahoo.com,

Accepted for publication: 9 June 2007

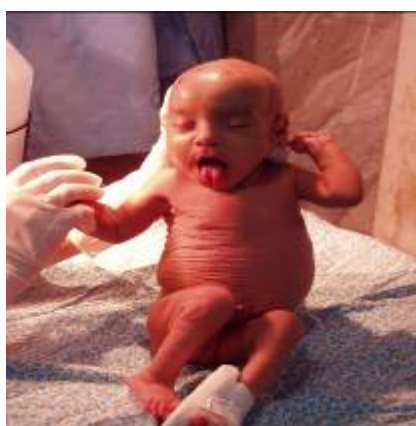

Figure 1. General appearance of the patient with ARC syndrome.

signs, including extreme dryness and development of scaly lesions within a few days of birth compatible with ichthyosis (Figure 2C). Conjugated hyperbilirubinemia was noted by the age of seven days with serum total and direct bilirubin levels of 7 and 4 mg/dL, respectively. The serum alkaline phosphatase level was 707 U/L (164 ± 68) while serum gamma-glutamyl transferase (GGT), liver transaminase levels, serum albumin, prothrombin time, and partial thromboplastin time were normal. Thyroid function test revealed a thyroid stimulating hormone (TSH) level of 50 mU/L (<10 mU/L), thyroxine level of $8.7 \mu\text{g/dL}$ (11.9 ± 0.4), and total tri-iodothyronine of 74 ng/dL (50.5 ± 3.6) compatible with hypothyroidism. A complete blood count was normal but the platelets were large (Figure 2D). Both toxoplasmosis, other (congenital syphilis and viruses), rubella, cytomegalovirus, and herpes simplex virus (TORCH) and metabolic screens were negative. Chromosomal analysis showed a normal karyotype of 46-XX.

Cranial computed tomography and radio-nucleotide scan of the biliary system (HIDA) as well as echocardiogram were almost normal. Electromyography showed neurogenic changes with reduced compound muscle action potential. Arthrogryposis, presented as talipes equinovarus, radial deviation of the wrists, flexion contracture of

limbs, clubfeet, and dislocation of the hips in this patient, was thought to be secondary to neurogenic muscle atrophy. Audiometry disclosed features of sensorineural hearing loss.

Because of the risk of lethal hemorrhage, permissions for liver, kidney, and skin biopsies were refused. She was not thriving despite adequate feeding and treatment with phenobarbital, ursodeoxycholic acid, fat soluble vitamins, medium chain triglyceride-based formula, L-thyroxine, and Stohl's solution.

Discussion

Polyhydramnios, hybrid type of renal tubular acidosis, and hypothyroidism manifested in our patient are not common. Cases may left undiagnosed as not all patients present with the three cardinal features.³ The clinical features cover abnormal morphology, recurrent fevers, diarrhea, diabetes insipidus, cerebral anomalies, deafness, abnormal platelets as well as the classic pictures of arthrogryposis, renal tubular acidosis, and cholestasis.⁴ Almost half of the patients who underwent diagnostic organ biopsy developed life-threatening hemorrhage.² Most of the reported cases were immigrants from Pakistan, but there are also reports from Turkey, Saudi Arabia, Oman, Italy, North Africa, Asia, and Portugal.⁵ The origin of our case was Persian and there is no other report from this region.

The central nervous system manifestations and global developmental delay were described in all reported cases. Other features included sensorineural hearing loss and absence or hypoplasia of the corpus callosum.⁶

Arthrogryposis is known to be a phenomenon secondary to decreased fetal movement, which is caused by degeneration of the anterior motor neuron cells. As a result, many of these patients are hypotonic. In addition, clubfoot and dislocation of the hip joint are frequently observed.¹ Hypothyroidism could also intensify hypotonia in these patients as found in our case.

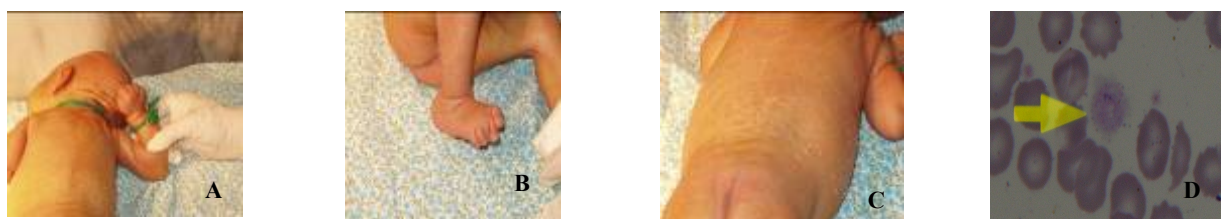


Figure 2. A) Redundant posterior skin folds in the neck, cholestatic jaundice, and radial deviation of the wrist; B) rocker bottom feet; C) Ichthyosis; D) giant platelets.

Renal tubular dysfunction has generally been the most striking clinical abnormality and may present in the first few days of life or later around the age of two to three months. Renal tubular dysfunction ranges from isolated renal tubular acidosis to complete Fanconi syndrome. Few patients were found to have diabetes insipidus unresponsive to desmopressin.⁵ In our patient, the first cardinal sign presenting at 72 hours of life was concomitant type 1 and 2 renal tubular acidosis which has been reported in at least one case.⁷ Kidney ultrasound may show nephrocalcinosis or small dysplastic kidneys.⁵ Although nephrocalcinosis was not demonstrated early in our case, but was found later when she was almost two months old.

Conjugated hyperbilirubinemia with normal or mildly elevated transaminases is a constant and early feature of ARC syndrome. These patients have normal GGT enzyme levels despite elevated conjugated bilirubin and alkaline phosphatase enzyme levels. However, a few patients had mildly elevated GGT.⁵

Ichthyosis has also been reported in association with ARC syndrome in half of the reported instances. It is suspected that the defective lamellar body secretion mediated by the soluble N-ethylmaleimide-sensitive factor attachment protein receptor or SNARE protein pathway in the epidermis might result in the ichthyosiform phenotype.¹

Variable dysmorphic features have been described in association with this syndrome including prominent occiput, posteriorly angulated and low set ears, flattened nasal bridge, up-slanting palpebral fissures, simian crease, high arched palate, beaked nose, small anterior fontanel, lax skin, low implantation of the thumb, and cryptorchidism.⁸

A congenital platelet defect similar to the gray platelet syndrome should be suspected in infants and children presenting with a diagnosis or a suspicion of ARC syndrome and platelet morphology should be studied before procedures that may be complicated by significant bleeding.⁷ A bleeding tendency was reported in a few cases despite normal clotting studies and platelet count; some patients bled after kidney and liver biopsy, and others had cerebral and gastrointestinal bleeding.¹

Hypothyroidism was previously reported in three patients with ARC syndrome.^{5,8} Like other

three patients, our case had an elevated TSH level with a normal T₄ concentration.

Pregnancy-related complications such as oligohydramnios, reduced fetal movements, and breech presentations are also common.⁵ In our case, polyhydramnios was noted. Congenital cardiac defects such as ventricular septal defect and atrial septal defect are seen occasionally.^{4,9}

Failure to thrive could be secondarily to increased caloric demand because of recurrent episodes of dehydration and sepsis in addition to chronic diarrhea due to fat malabsorption secondary to cholestasis.⁷

Regarding immunologic work-up, in one study a defect in polymorphonuclear cell migration and intracellular killing was demonstrated.¹⁰

Death occurs in most of the cases in the first year of life secondary to sepsis, severe dehydration, and acidosis, although one patient survived until the age of three years.¹

ARC syndrome is a rare inherited disorder which is not uncommon in societies with high rates of consanguineous marriage. There is no specific treatment for this syndrome and most patients do not live longer than seven months after birth despite supportive care for metabolic acidosis and cholestasis.

Many major manifestations of this syndrome have not been appreciated and we propose that the acronym of ARC syndrome be expanded to arthrogryposis-renal dysfunction-cholestasis-hypothyroidism-ichthyosis-deafness or dysmorphic features (ARCHID) syndrome so as to encompass other additional aspects of the disorder.

References

- 1 Choi HJ, Lee MW, Choi JH, Moon KC, Koh JK. Ichthyosis associated with ARC syndrome: ARC syndrome is one of the differential diagnosis of ichthyosis. *Pediatr Dermatol*. 2005; **23**: 539 – 543.
- 2 Gissen P, Tee L, Johnson CA, Genlin E, Caliebe A, Chitayat D, et al. Clinical and molecular genetic feature of ARC syndrome. *Hum Genet*. 2006; **120**: 396 – 409.
- 3 Bull LN, Mahmoodi V, Baker AJ, Jones R, Strautnieks SS, Thompson RJ, et al. VPS33B mutation with ichthyosis, cholestasis, and renal dysfunction but without arthrogryposis: incomplete ARC syndrome phenotype. *J Pediatr*. 2006; **148**: 269 – 271.
- 4 Coleman RA, van Hove JL, Morris R, Rhods JM, Summar ML. Cerebral defects and nephrogenic diabetes insipidus with the ARC syndrome: additional findings or a new syndrome (ARCC-NDI). *Am J Med Genetics*. 1997; **72**: 335 – 338.
- 5 Abu-Sa'da O, Barbar M, Al-Harbi N, Taha D. Arthrogryposis, renal tubular acidosis, and cholestasis

- (ARC) syndrome: two new cases and review. *Clin Dysmorphol*. 2005; **14**: 191 – 196.
- 6 Abdullah MA, Al-Hasnan Z, Okamoto E, Abomelha AM. Arthrogryposis, renal dysfunction, and cholestasis syndrome. *Saudi Med J*. 2000; **21**: 297 – 299.
 - 7 Hayes JA, Kahr WH, Lo B, Macpherson BA. Liver biopsy complicated by hemorrhage in a patient with ARC syndrome. *Paediatr Anaesth*. 2004; **4**: 960 – 963.
 - 8 Eastham KM, McKiernan PJ, Milford DV, Ramani P, Wyllie J, van't Hoff W, et al. ARC syndrome: an expanding range of phenotypes. *Arch Dis Child*. 2001; **85**: 415 – 420.
 - 9 Horslen SP, Quarrell OW, Tanner MS. Liver histology in the arthrogryposis multiplex congenita, renal dysfunction, and cholestasis (ARC) syndrome: report of three new cases and review. *J Med Genet*. 1994; **31**: 62 – 64.
 - 10 Mikati MA, Barakat AY, Sulh HB, Der Kaloustian VM. Renal tubular insufficiency, cholestatic jaundice, and multiple congenital anomalies—a new multisystem syndrome. *Helv Paediatr Acta*. 1984; **39**: 463 – 471.

Archive of SID