

---

## Case Report

---

# Work-Related Penetrating Head Trauma Caused by Industrial Grinder Tool

Ali Abdoli MD\*, Abbass Amirjamshidi MD MPH\*

---

**Nonmissile low-velocity penetrating brain injuries are unusual among civilian population. Work-related penetrating head wounds are rarer among this group.**

**Here, we report two rare cases of penetrating head wounds caused by industrial grinder tool. The patients (both men) were struck to the head by detached blades of the grinder tool. Depressed fractures, penetrated bone fragments, and dural lacerations were all treated by the routine fashion. Paranasal sinus damage and further cerebrospinal fluid leakage were also treated conservatively.**

**The reported cases are unexpected variants of injuries that neurosurgeons may come across and their management is still beyond the scope of textbooks. Skill and experience of the general neurosurgeons can handle the cases properly but prevention of such incidents using safer and guarded instruments should be stressed to manufacturers.**

---

*Archives of Iranian Medicine, Volume 12, Number 5, 2009: 496 – 498.*

---

**Keywords:** Industrial grinder tool • penetrating head injuries • traumatic brain injury

## Introduction

According to Schlep,<sup>1</sup> a work-related injury, is an injury that has occurred at a work place, either as a part of the job or on a work-related assignment. Here, we report two cases of very rare work-related penetrating head traumas.

## Case Reports

### Case 1

A 24-year-old man was hit on his head by the broken blade or wheel of an industrial grinder while he was working with the tool. He was transferred to the emergency room with Glasgow Coma Scale (GCS) = 14 because of penetrating brain injury.

The scalp laceration was 8 cm in length and 8 mm in width and the brain was exposed. The

regular industrial grinder and the position of the worker using the instrument at work is seen in Figures 1A and B.

Brain computed tomography (CT) revealed contusion of left frontal lobe underneath the depressed fracture of the frontal bone and frontal sinus (Figure 1C). The patient underwent craniotomy and debridement of the bone fragments and repair of the dura. The postoperative course was uneventful even though he developed rhinorrhea in the first day after operation, which disappeared after lumbar puncture. Antibiotic therapy was continued for ten days and the patient was discharged without neurologic deficit and infection.

### Case 2

A 27-year-old man was hit in the corner of his right eye by the broken wheel of the industrial grinder while he was working with the tool (Figure 2A). He was admitted to the emergency room with GCS= 15.

Brain CT revealed foreign body in the orbit (Figures 2B and C). He was transferred to the ophthalmic surgery department and underwent a subscleral approach and the blade was removed without further damage to the globe or optic nerve.

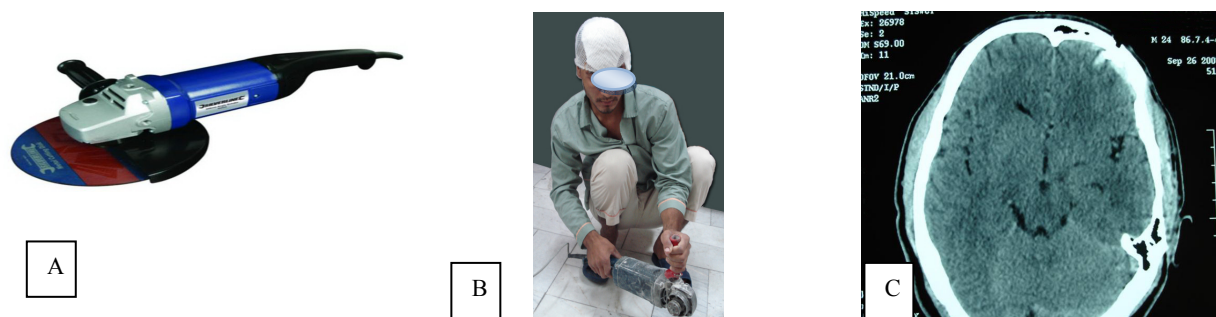
---

**Authors' affiliation:** \*Department of Neurosurgery, Sina Hospital, Tehran University of Medical Sciences (TUMS), Tehran, Iran.

**•Corresponding author and reprints:** Abbass Amirjamshidi MD MPH, Department of Neurosurgery, Sina Hospital, Tehran University of Medical Sciences (TUMS), Tehran, Iran. P.O. Box: 19585-678

E-mail: abamirjamshidi@yahoo.com

Accepted for publication: 25 September 2008



**Figure 1.** **A)** The industrial grinder available in the market; **B)** The usual position of the workers handling industrial grinder at work; **C)** Tomography showing depressed skull fracture caused by grinder blade hitting the head.

## Discussion

Civilian penetrating head trauma by bullets and pellets,<sup>2,3</sup> are rare but not anecdotal reports. Those rarely reported cases have been caused by fishing harpoon,<sup>4</sup> electrical plug,<sup>5</sup> plastic hair beads,<sup>6</sup> metal rod,<sup>7</sup> flying wire fragment,<sup>8</sup> lawn darts,<sup>9,10</sup> Eiffel-toy,<sup>11</sup> drill bit,<sup>12</sup> a nail or needle, a knife, a pencil, and other such weird things.<sup>13,14</sup> Hereby, two unique cases with injury by broken wheel of industrial grinder tool are added to this list.<sup>15</sup>

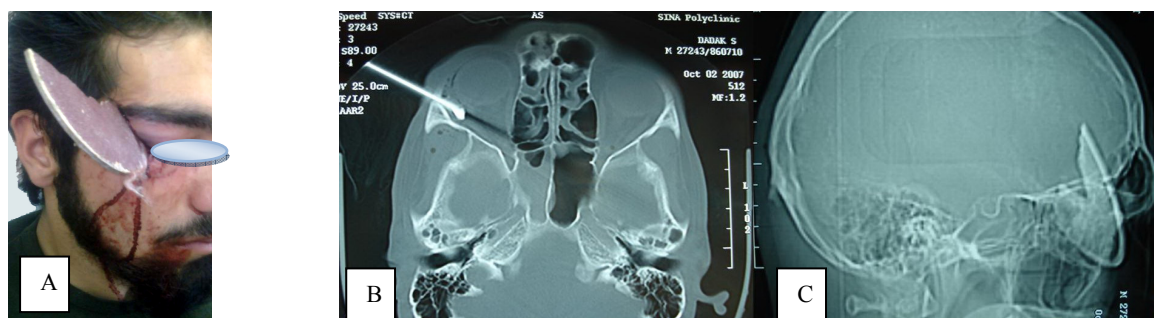
Gunshot injuries are more prevalent in the United States, with firearm injury being the second only to motor vehicle collisions in causing traumatic deaths,<sup>16</sup> whereas in South Africa stab wounds predominate.<sup>17,18</sup> Stab wounds to the cranium are injuries caused by a weapon with smaller impact area and wielded at low velocity in comparison with missile injury.

Although knives are by far the most common weapon in assault, even objects as innocuous as a pencil, metal rod, needle, and lawn dart may penetrate the cranium.<sup>7,9,10,13,14</sup> The orbit is a common site for penetration into the cranium. In the injuries with less kinetic energy,<sup>2</sup> traumatic damage is limited to the site of penetration, similar to the second case in this report.

Tan and Choudhari recommended that in the presence of an obvious penetrating injury with an

embedded foreign body, under no circumstances any attempt should be made to remove the object, until the patient had a thorough clinical and radiologic evaluation.<sup>5</sup> Sudden removal can cause loss of the tampon effect and subsequent catastrophic intracranial hemorrhage may happen. Removing the impacted object is best done in the operation room by a dedicated neurosurgical team. The principles of management of penetrating craniocerebral injuries consist of debridement and removal of the projectile(s) as well as all accessible bone fragments.<sup>19</sup> Devitalized tissues and clots should then be removed followed by meticulous homeostasis and watertight dural closure to avoid cerebrospinal fluid fistula, to prevent cerebral infestation, and to provide an important barrier to infection.

Nonfatal injuries to working-age adults are common, annually resulting in 12 episodes of medically-treated injuries per 100 adults with the age range of 18 to 64.<sup>16</sup> Traumatic brain injury (TBI) is a major cause of death and permanent disability in this age group especially in the developing countries. TBI occurring at the workplaces, comprise about 7% of all TBI population, and carries major economic repercussions in terms of lost wages and costs.<sup>7</sup> Work-related TBI has also been a significant contributor to the number of work-related deaths



**Figure 2.** **A)** The site of injury in the patient who was hit by the broken wheel of the industrial grinder; **B and C)** Tomography showing the position of the blade in the cranium and the orbit.

overall. Tricco et al. reported 488 work-related injury fatalities from the Chief Coroner's Office of Ontario during 1996 – 2000.<sup>20</sup> Evidence of TBI was apparent in 45% of these cases (n=211).<sup>20</sup> Pre-injury demographics and injury-related characteristics of work-related TBI were significantly different from nonwork-related TBI in characteristics such as age, gender, mechanisms of injury, injury severity score, length of hospital stay, and in-hospital death.<sup>21</sup> Males outnumbered females at a ratio of more than 9 to 1, with males accounting for 90% of the work-related injuries.<sup>21</sup> The victims were both men in our report as well.

Industries with the highest rate of work-related TBI expressed per 100,000 working population included primary industry (59.1%), agriculture (24.5%), construction (20.0%), and transportation/communications/utilities industries.<sup>9,16,20</sup> The patients presented in this report were both working in construction sectors and it is suggested that the instruments used by these workers need shields to prevent similar injuries.

Prevention is always better and more cost effective than treatment, and surveillance plays a critical part in highlighting the more dangerous industries, types of jobs, and characteristics of workers at risk. This allows targeted injury and illness intervention strategies and helps assess success of prevention efforts.

TBI can be an important cause of disability among the workers especially in the developing contexts working under situations with improper safety and with life-threatening instruments.

## References

- Schlep L. The occurrence of farm-environmental injuries in a Swedish municipality. *Accid AnalPrev*. 1992; **24**: 161 – 166.
- Amirjamshidi A, Abbassioun K, Roozbeh H. Air-gun pellet injuries to the head and neck. *Surg Neurol*. 1997; **47**: 331 – 338.
- Martinez-Lage JF, Mesones J, Gilabert A. Air-gun pellet injuries to the head and neck in children. *Pediatr Surg Inj*. 2001; **17**: 657 – 660.
- Lopez F, Martinez-Lage JF, Herrera A, Sanchez-Solis M, Torres P, Palacios MI, et al. Penetrating craniocerebral injury from an underwater fishing harpoon. *Childs Nerv Syst*. 2000; **16**: 117 – 119.
- Tan MH, Choudhari KA. Penetrating head injury from an electrical plug. *Injury*. 2003; **34**: 950 – 953.
- Geller E, Yoon MS, Loisel J, Crisci KL, Bierbrauer KS. Head injuries in children from plastic hair beads. *Pediatr Radiol*. 1997; **27**: 790 – 793.
- Regev E, Constantini S, Pomeranz S, Sela M, Shalit M. Penetrating craniocerebral injury caused by a metal rod: an unusual case report. *Injury*. 1990; **21**: 414 – 415.
- Bhatjiwale MG, Goel A, Muzumdar DP. Transnasal intracranial entry of a flying wire fragment. *Br J Neurosurg*. 2001; **15**: 256 – 258.
- Sotiropoulos SV, Jackson MA, Tremblay GF, Burry VF, Olson LC. Childhood lawn dart injuries. Summary of 75 patients and patient report. *Am J Dis Child*. 1990; **144**: 980 – 982.
- Tay JS, Garland JS. Serious head injuries from lawn darts. *Pediatrics*. 1987; **79**: 261 – 263.
- George M, Round J. An Eiffel penetrating head injury. *Arch Dis Child*. 2006; **91**: 416.
- Gutierrez-Gonzalez R, Boto GR, Rivero-Garvia M, Perez-Zamarron A, Gomez G. Penetrating brain injury by drill bit. *Clin Neurol Neurosurg*. 2008; **110**: 207 – 210.
- Domingo Z, Peter JC, de Villiers JC. Low-velocity penetrating craniocerebral injury in childhood. *Pediatr Neurosurg*. 1994; **21**: 45 – 49.
- Dujovny M, Osgood CP, Maroon JC, Jannetta PJ. Penetrating intracranial foreign bodies in children. *J Trauma*. 1975; **15**: 981 – 986.
- Corzillius M, Storz C, Grasner JT. Case report; severe neck injury caused by an angle grinder. *Anesthesiol Intensivmed Notfallmed Schmerzther*. 2007; **42**: 102 – 105.
- From the Centers for Disease Control and Prevention. Deaths resulting from firearm- and motor-vehicle-related injuries—United States, 1968 – 1991. *JAMA*. 1994; **271**: 495 – 496.
- Levy ML, Masri LS, Levy KM, Johnson FL, Martin-Thomson E, Couldwell WT, et al. Penetrating craniocerebral injury resultant from gunshot wounds: gang-related injury in children and adolescents. *Neurosurgery*. 1993; **33**: 1018 – 1025.
- Taylor AG, Peter JC. Patients with retained transcranial knife blades: a high-risk group. *J Neurosurg*. 1997; **87**: 512 – 515.
- Amirjamshidi A, Abbassioun K, Rahmat H. Minimal debridement or simple wound closure as the only surgical treatment in war victims with low-velocity penetrating head injuries. Indications and management protocol based upon more than eight years follow-up of 99 cases from Iran-Iraqe conflict. *Surg Neurol*. 2003; **60**: 105 – 111.
- Tricco AC, Colantonio A, Chipman M, Liss G, McLellan B. Work-related deaths and traumatic brain injury. *Brain Inj*. 2006; **20**: 719 – 724.
- Kim H, Colantonio A, Chipman M. Traumatic brain injury occurring at work. *NeuroRehabilitation*. 2006; **21**: 269 – 278.