

---

**Case Report**

---

**Osteosarcoma of the Larynx**

Zohreh Sanaat MD\*, Ghodrat Mohammady MD\*\*, Heidar Esmaili MD\*\*\*,  
Mahmoud Emrani MD†, Roya Dolatkah MD\*

---

**Malignant mesenchymal tumors of the larynx constitute 0.3% to 1% of all laryngeal cancers. Of them, osteosarcoma is the rarest. Osteosarcoma of the larynx may be a difficult clinical diagnosis. Pathologic confirmation of osteoid is required for the diagnosis. Treatment is primarily surgical. It is believed that aggressive surgical intervention directed at complete tumor extirpation is the treatment of choice. Outcomes of such patients are generally poor. Most patients die because of pulmonary metastasis. A case is reported here and a review of all available published cases of osteosarcoma of the larynx is presented.**

*Archives of Iranian Medicine, Volume 12, Number 5, 2009: 499 – 502.*

---

**Keywords:** Laryngeal cancer • osteosarcoma

**Introduction**

**S**arcoma constitutes fewer than 1% of the head and neck cancers, and represents fewer than 1% of laryngeal cancers.<sup>1,2</sup>

Osteosarcoma of the larynx is rare. Pseudosarcoma or carcinosarcoma of the larynx refers to a rare neoplasm containing malignant mesenchymal and epithelial elements. Some researchers have interpreted these tumors as anaplastic carcinoma with pseudosarcoma reactions of the mesenchymal tissue. Experiences with osteosarcoma of the larynx are limited to 15 cases in the literature.<sup>1-3</sup> Herein, we report another case of osteosarcoma of the larynx.

**Case Report**

A 71-year-old man was evaluated for increasing hoarseness for eight months, and dysphagia, odynophagia, and dyspnea since nearly

one year ago. He had no weight loss, otalgia, hemoptysis, or constitutional signs of any diseases. He had the history of smoking 30 pack year with no alcohol usage. He had no hypertension or other diseases.

Physical examination revealed bilateral true vocal cords mass with extension to supraglottic region. True vocal cords were fixed. No masses were palpable in his neck. Results of laboratory studies were normal. A computed tomography (CT) scan showed a solid mass, which destructed the true and false vocal cords and extended to supra- and infraglottis areas with no effect on thyroid cartilage (Figure 1).

Total laryngoscopy was done and a biopsy sample was taken from the laryngeal mass and then the total laryngectomy was performed.

**Pathology**

Microscopic examination of the initial biopsy specimen revealed a malignant tumor with pleomorphic cells, having hyperchromatic, sometimes spindle-shaped nuclei with differential diagnosis of spindle-shaped squamous cell carcinoma and sarcoma. Total laryngectomy specimen revealed the same histologic features of the previous biopsy, but osteoid and woven bone formation was observed in different parts. So, the diagnosis of osteogenic sarcoma was confirmed (Figure 2). After operation, the patient did not

---

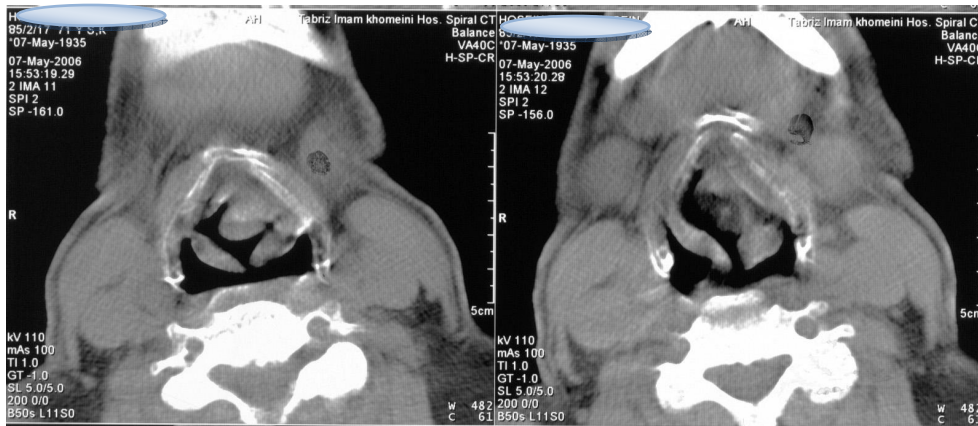**Authors' affiliations:** \*Hematology and Oncology Research Center, \*\*Department of Otolaryngology, \*\*\*Department of Pathology, †Department of Radiology, Tabriz University of Medical Sciences, Tabriz, Iran.

**•Corresponding author and reprints:** Zohreh Sanaat MD, Department of Hematology and Oncology, Tabriz University of Medical Sciences, Tabriz, Iran.

Tel: +98-411-336-1358, Fax: +98-411-334-3844

E-mail: sanaatz2000@yahoo.com

Accepted for publication: 16 October 2008



**Figure 1.** Computed tomography scan shows a solid mass, destruction of true and false vocal cords, and extension to supra- and infra-glottic areas.

accept any treatment modalities. Eight months later, a bone scan revealed multiple osseous metastases and CT of the chest showed pulmonary metastases. The patient died one year after the diagnosis due to the bone and pulmonary metastases.

### Discussion

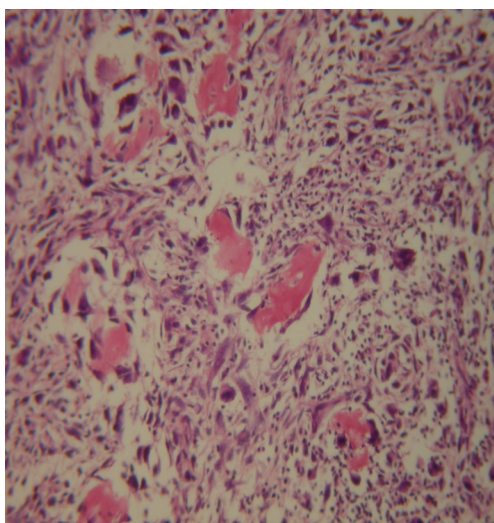
Osteosarcoma of the larynx was first described in 1942. Malignant sarcoma of the larynx is a rare entity, making up 0.5% to 1% of laryngeal neoplasms. To date, 15 cases of osteosarcoma of the larynx have been described. Of them, 13 patients were males and two were females.<sup>2</sup> The most common laryngeal sarcomas are chondrosarcoma and fibrosarcoma. Chondrosarcomas arise most frequently from the cricoid

(75%) and thyroid cartilages. Because of their well-differentiated nature, the prognosis is often favorable. Metastatic and poorly-differentiated tumors are rare. Fibrosarcomas of the larynx usually arise from the anterior vocal fold and anterior commissure. The prognosis depends on the tumor size. The five-year survival rates of well-differentiated and poorly-differentiated tumors are 50% and 5%, respectively.<sup>1</sup> Osteosarcoma has also been reported to be metastatic to the larynx, but only primary original osteosarcoma in the larynx is reviewed.

In two of these cases, osteosarcoma occurred by radiation therapy for the head and neck primary tumors.<sup>2,13</sup> The etiology of osteosarcoma of the larynx is unknown. There is no direct correlation with alcohol and tobacco use, but this information was only available in a small number of reported cases.<sup>3</sup> Our patient used tobacco but did not use alcohol and was not exposed to prior radiation therapy.

The most common presenting complaints in osteosarcoma of the larynx are hoarseness, dyspnea, and acute airway obstruction. In our patient, the mean duration of symptoms was approximately six months before the diagnosis. A summary of the 15 reported cases of primary osteosarcoma and our case is shown in Table 1.<sup>1-15</sup>

Treatment of osteosarcoma is surgery, radiation therapy, and chemotherapy. The Cooperative Osteosarcoma Study (COSS) group attempted to study the role of various chemotherapeutic regimens on the long-term survival and disease-free-interval in patients with skeletal osteosarcoma.<sup>2</sup> Because skeletal osteosarcoma is far more common, much more information should be available for better further improvement.



**Figure 2.** Malignant tumor with pleomorphic cells, having hyperchromatic, sometimes spindle-shaped nuclei (H&E, original magnification×40).

**Table 1.** Review of the clinicopathologic features of 16 cases of osteosarcoma of the larynx.

Case No.	Age(yr)/Sex	Symptom	Treatment	Outcome
1 <sup>4</sup>	51/M	Dyspnea, hoarseness	Total laryngectomy	Recurrence after 3 months, died after 6 months with extensive mediastinal metastases
2 <sup>5</sup>	51/M	Dyspnea, hoarseness	Total laryngectomy, XRT for local recurrence	Died after 14 months; local recurrence in wound, bilaterally in neck, and in lung
3 <sup>6</sup>	71/M	Hoarseness	Total laryngectomy	Alive and free of disease after 24 months
4 <sup>7</sup>	62/M	Hoarseness, acute airway obstruction	Subtotal laryngectomy and obstruction, XRT (4200 Gy) to stromal	Died after 3 months with neck mass and cervical lymphadenopathy
5 <sup>8</sup>	79/M	Chronic hoarseness, acute airway obstruction	Total laryngectomy	Died after 3 months with multiple pulmonary metastases
6 <sup>9</sup>	66/M	Progressive hoarseness, stridor	Total laryngectomy with thyroidectomy	Died after 20 months with pulmonary metastases
7 <sup>10</sup>	75/M	Hoarseness	Total laryngectomy with radical neck dissection	Died after 14 months with regional and distant disease
8 <sup>11</sup>	67/M	Dyspnea, hoarseness	XRT (6700Gy) to right and left side of neck	Died after 6 months
9 <sup>12</sup>	65/M	Dyspnea, hoarseness	XRT(4500 Gy); after one year, 4000Gy for recurrence	Recurrence after 1 year
10 <sup>13</sup>	56/M	XRT 3 years earlier for SCC of larynx	Not available	Not available
11 <sup>14</sup>	75/M	Mild dysphasia, odynophagia	Total laryngectomy, postoperative chemotherapy; XRT for soft tissue recurrence in neck	Recurrence in soft tissue of neck 13 months later
12 <sup>15</sup>	65/M	Progressive dyspnea	Thyrotomy with tumor resection, tracheostomy, XRT	Recurrence after one month, skin nodule resection and pectoralis flap; free of disease after 60 months
13 <sup>3</sup>	60/F	Odynophagia radiating to right ear, globus	Total laryngectomy	Free of disease after 44 months
14 <sup>2</sup>	69/F	Progressive dyspnea, XRT for previous SCC of larynx	Total laryngectomy, thyroidectomy, total pharyngectomy, esophagectomy	Free of disease after 4 months
15 <sup>1</sup>	47/M	Hoarseness	Total laryngectomy, XRT, chemotherapy	Died after 12 months with bone metastases
This report	71/M	Dyspnea, hoarseness	Laryngectomy	Died after 1 year with bone and pulmonary metastases

M=male, F=female, XRT=radiation therapy, SCC=squamous cell carcinoma.

The COSS group found confirmed data from controlled studies comparing adjuvant versus neoadjuvant chemotherapy.<sup>2</sup> The regimen recommended by the COSS group include methotrexate, doxorubicin, and cisplatin.<sup>2</sup> Because of rarity of osteosarcoma, there are no systematic

studies that can prove what kinds of treatments are effective on survival. Most patients died soon after their initial diagnoses, mostly of pulmonary metastasis or local/regional recurrence and bone metastasis. Three of the pervious 15 patients were treated with primary radiation therapy.<sup>1-3</sup> Six

patients were treated with surgery alone.<sup>3,4,6,8-10</sup> Our patient died one year after the diagnosis with bone and pulmonary metastases.

### References

- 1 Myssiorek D, Patel M, Wasserman P, Rofein O. Osteosarcoma of the larynx. *Ann Otol Rhinol Laryngol*. 1998; **107**: 70 – 74.
- 2 Athre RS, Vories A, Mudrovich S, Ducic Y. Osteosarcoma of the larynx. *Laryngoscope*. 2005; **115**: 74 – 77.
- 3 Berge JK, Kapadia SB, Myers EN. Osteosarcoma of the larynx. *Arch Otolaryngol Head Neck Surg*. 1998; **124**: 207 – 210.
- 4 Jackson C, Jackson CL. *Diseases and Injuries of the Larynx*. New York, NY: Macmillan Publishing Co. Inc.; 1942: plate XI.
- 5 Clerf LH. Sarcoma of the larynx. *Arch Otolaryngol*. 1946; **44**: 517 – 524.
- 6 Sprinkle PM, Allen MS, Brookshire PF. Osteosarcoma of the larynx. *Laryngoscope*. 1966; **76**: 325 – 333.
- 7 Morley AR, Cameron DS, Watson AJ. Osteosarcoma of the larynx. *J Laryngol Otol*. 1973; **87**: 997 – 1005.
- 8 Dahm LJ, Schaefer SD, Carder HM, Vellios F. Osteosarcoma of the soft tissue of the larynx. *Cancer*. 1978; **42**: 2343 – 2351.
- 9 Haar JG, Chaudhry AP, Karanjia MD, Milley PS. Chondroblastic osteosarcoma of the larynx. *Arch Otolaryngol*. 1978; **104**: 477 – 481.
- 10 Gorenstein A, Neel HB III, Weiland LH, Devine KD. Sarcomas of the larynx. *Arch Otolaryngol*. 1980; **106**: 8 – 12.
- 11 Suchatlampong V, Sriumpai S, Khawcharoenporn V. Osteosarcoma of the larynx: the first case report in Thailand with ultrastructural study. *J Med Assoc Thai*. 1981; **64**: 301 – 307.
- 12 Remagen W, Löhr J, von Westernhagen B. Osteosarcoma of the larynx. *HNO*. 1983; **31**: 366 – 368.
- 13 Laskin WB, Silverman TA, Enzinger FM. Postradiation soft tissue sarcomas: an analysis of 53 cases. *Cancer*. 1988; **62**: 2330 – 2340.
- 14 van Laer CG, Helliwell TR, Atkinson MW, Stell PM. Osteosarcoma of the larynx. *Ann Otol Rhinol Laryngol*. 1989; **98**: 971 – 974.
- 15 Pinsolle J, LeCluse I, Demeaux H, Laur P, Rivel J, Siberchicot F. Osteosarcoma of the soft tissue of the larynx: report of a case with electron microscopic studies. *Otolaryngol Head Neck Surg*. 1990; **102**: 276 – 280.