

---

## Case Report

---

# Association between Plaque-Type Psoriasis and Perianal Streptococcal Cellulitis and Review of the Literature

Abbas Rasi MD\*, Nargess Pour-Heidari MD\*

---

**Perianal streptococcal dermatitis is an uncommon superficial cutaneous infection of the perianal area almost exclusively described in children. Perianal streptococcal dermatitis is caused by group A beta-hemolytic streptococci and occurs mainly in children between six months and ten years of age. Prior therapy with topical antifungal agents, topical corticosteroids, and oral preparations for pinworms either fails to improve or worsens patient's symptoms. Early antibiotic therapy causes a dramatic and rapid improvement of symptoms. Treatment protocol consists of amoxicillin 40 mg/kg/day, divided into three doses, and/or topical application of mupirocin 2% ointment three times per day for ten days. We describe a four-year-old boy with perianal streptococcal dermatitis who was brought to our clinic with plaque type psoriasis.**

*Archives of Iranian Medicine, Volume 12, Number 6, 2009: 591 – 594.*

---

**Keywords:** Perianal cellulitis • plaque-type psoriasis • streptococcus

### Introduction

**P**erianal streptococcal dermatitis (PSD) is an uncommon superficial cutaneous infection of the perianal area almost exclusively described in children. Only few cases of PSD in adult patients are available in the literature. Several familial cases also have been reported.<sup>1-3</sup> Communal bathing is thought to facilitate familial spread; however, the incidence of communal bathing did not reach statistical significance in one study.<sup>2</sup>

PSD was first described in 1966 by Amren et al.<sup>4</sup> as a perianal streptococcal cellulitis. It represents a superficial bacterial infection usually with group A beta-hemolytic streptococci (GABHS). Symptoms may last from three weeks to six months. Patients are frequently misdiagnosed.<sup>5</sup> Initial treatment that delays effective treatment includes topical antifungal

agents, topical steroids, and oral preparations for pinworms. We describe a four-year-old boy with PSD who was brought to our clinic with plaque-type psoriasis. Early recognition, diagnosis, and treatment greatly decrease patient's discomfort and parental distress. Early antibiotic treatment results in dramatic and rapid improvement of symptoms.

### Case Report

A four-year-old Iranian boy was brought to our clinic with complaints of rectal itching and burning, and pain on defecation. The patient was afebrile and extremely uncomfortable due to severe pruritus in the perianal region.

Physical examination revealed a bright red, moist, edematous, and sharply demarcated rash that extended circumferentially for approximately 3 cm around the perianal area (Figure 1). The patient had been previously treated for three months with topical antibiotics, topical steroids, and topical antifungal creams prescribed by other physicians without improvement. The patient also had a three-year history of a mildly pruritic rash on his trunk. He had no other symptoms such as a sore throat or other infections. His family history was negative for psoriasis. On physical examination, he had some plaques typical for plaque psoriasis on

---

**Authors' affiliation:** \*Department of Dermatology, Hazrat-e-Rasul Hospital, Iran University of Medical Sciences, Tehran, Iran.

**•Corresponding author and reprints:** Abbas Rasi MD, Department of Dermatology, Hazrat-e-Rasul Hospital, Iran University of Medical Sciences, Niayesh St., Sattarkhan Ave., Tehran, Iran.

Tel: +98-216-651-5001-9, Fax: +98-216-651-7118

E-mail: dr\_rasi2002@yahoo.com

Accepted for publication: 24 October 2008

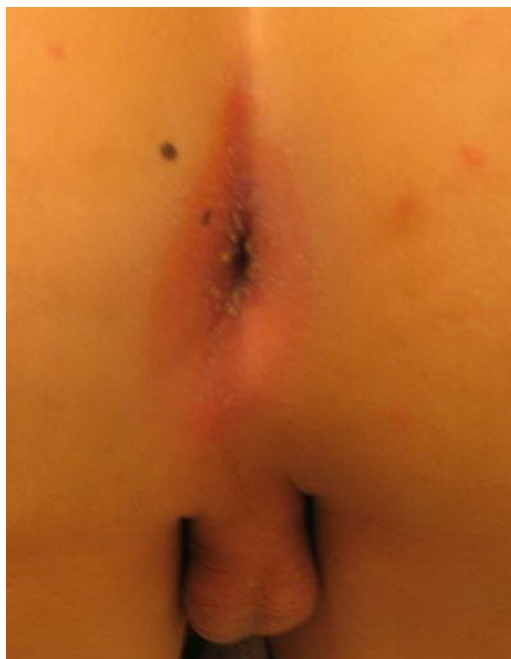

Figure 1. Perianal rash

his trunk and flank area (Figure 2).

Results of laboratory examinations, including red and white blood cell counts, erythrocyte sedimentation rate, urine microscopy and sediment, and stool examination were within normal limits. A clinical diagnosis of SPD was made and confirmed with a rapid streptococcal screen of perianal region. Therapies with topical medications were discontinued, and the patient was given oral amoxicillin (40 mg/kg/day) for ten days. A dramatic clinical response was noted within three days, and symptoms completely resolved after three weeks. But his psoriatic lesions did not respond to the therapy. Perianal swab taken three weeks later was negative for GABHS. To the best of our knowledge, perianal streptococcal cellulitis associated with plaque-type psoriasis has not been

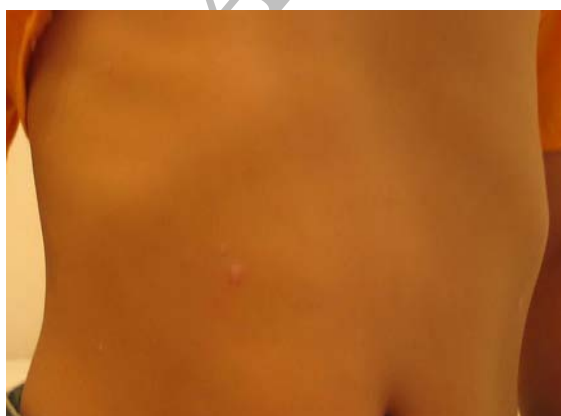

Figure 2. Plaque type lesions on trunk and flank

reported previously. We report this case for two reasons: first, to make physicians aware of this condition and second, to emphasize the necessity of examining patients, particularly pediatric patients with PSD, very thoroughly for other possible associated conditions.

## Discussion

PSD is caused by GABHS and occurs mainly in children between six months and ten years of age.<sup>6</sup> Although uncommon, PSD has also been reported as being caused by *Staphylococcus aureus*.<sup>7,8</sup> In one study, the incidence was reported to range from one in 218 to one in 2000 pediatric outpatient visits.<sup>2</sup> Signs and symptoms in this study included perianal dermatitis (90%), perianal itching (78%), rectal pain (52%), and blood-streaked stools (35%).<sup>2</sup> Intra-family spread has been reported in 50% of possible cases. Prior therapy with topical antifungal agents, topical corticosteroids, and oral preparations for pinworms either fails to improve or worsens patient's symptoms.<sup>5</sup> This type of therapy frequently delays definitive diagnosis and treatment. Children with streptococcal pharyngitis have a 6% anal carriage rate.<sup>9</sup> It is thought that gastric acid in a healthy host eliminates most of the swallowed pharyngeal bacteria; therefore, other sources of transmission are likely. Digital contamination from an infected oropharynx or other sites of streptococcal infection (i.e., impetigo) may be the source.

Clinically, this entity presents itself most commonly as a superficial perianal well-demarcated rim of erythema; sometimes fissuring may also be seen. Pain or tenderness, especially prominent on defecation, may lead to fecal retention in affected patients. Subcutaneous involvement, suggestive of cellulitis, is normally absent. The absence of fever and systemic signs and symptoms also support the superficial location of rash.<sup>2</sup> It may also affect the vulvar and penile tissues.<sup>1,9-11</sup> The association between PSD and guttate psoriasis has been reported by some authors,<sup>12,13</sup> but its association with plaque-type psoriasis has not been reported. The association between (guttate and plaque) psoriasis and streptococcal infections has been known for a long time and is well-documented. The mechanisms, however, are still a matter of investigation and several findings indicate a possible role for various bacterial proteins and/or toxins serving as

superantigens.<sup>14</sup> More recently, Tonkovic-Capin et al. and Stricker et al. found an association between PSD and streptococcal vulvovaginitis in a 41-year-old woman, a condition usually encountered in prepubertal girls.<sup>15,16</sup>

Although the clinical picture of a sharply demarcated erythema is very characteristic, PSD is often misdiagnosed for long periods of time and patients receive treatments for a variety of other diagnoses, including candidiasis, seborrheic dermatitis, psoriasis, atopic dermatitis, diaper rash, sexual abuse, local trauma from heavy wiping, and inflammatory bowel disease or pinworm infestation. A rapid streptococcal test or a culture of the perianal area may elucidate the diagnosis. Relapses have been noted in up to 39% of cases; thus, close follow-up is indicated.<sup>2</sup>

Early antibiotic therapy causes a dramatic and rapid improvement in symptoms. As the vast majority of infections are due to streptococci, a systemic penicillin or erythromycin combined with a topical antiseptic or antibiotic is the treatment of choice. The duration of the disease should be 14 to 21 days, depending on the clinical response. Post-treatment swabs and urine analysis to monitor for poststreptococcal glomerulonephritis are recommended. Although penicillin is generally recommended for the treatment of GABHS infection, amoxicillin is often better tolerated in pediatric population because of its better-tasting suspension.<sup>17</sup> Treatment protocol consists of amoxicillin 40 mg/kg/day, divided into three doses, and/or topical applications of mupirocin 2% ointment three times per day for ten days.<sup>6,13</sup> Penicillin, clindamycin phosphate, and erythromycin have also been used.<sup>18</sup> Although Medina et al. suggested topical mupirocin monotherapy for PSD caused by GABHS, others believe that systemic antibiotics such as penicillin, erythromycin, roxithromycin, or azithromycin should be the treatment of choice.<sup>19</sup> Therapy should be monitored by post-treatment perianal and throat swabs as well as urine analysis to monitor for poststreptococcal glomerulonephritis.

## Conclusion

Culture from the affected area should always be prepared in patients with persistent perianal erythema. SPD can masquerade as many other diseases. Perirectal tenderness and pain during defecation can result in constipation, particularly

when the diagnosis is not considered and effective therapy is delayed for months. Therapy should be monitored by post-treatment perianal and throat swabs as well as urine analysis to monitor for post-streptococcal glomerulonephritis. To the best of our knowledge, combination of psoriasis and PSD has not been previously described in the literature, and whether it is merely a chance occurrence or an actual association remains to be seen.


## References

- 1 Hirschfeld AJ. Two family outbreaks of perianal cellulitis associated with group A beta-hemolytic streptococci. *Pediatrics*. 1970; **46**: 799 – 802.
- 2 Kokx NP, Comstock JA, Facklam RR. Streptococcal perianal disease in children. *Pediatrics*. 1987; **80**: 659 – 663.
- 3 Paradisi M, Cianchini G, Angelo C, Conti G, Puddu P. Perianal streptococcal dermatitis: two familial cases. *Cutis*. 1994; **54**: 341 – 342.
- 4 Amren DP, Anderson AS, Wannamaker LW. Perianal cellulitis associated with group A streptococci. *Am J Dis Child*. 1966; **112**: 547 – 552.
- 5 Krol A. Perianal streptococcal dermatitis. *Pediatr Dermatol*. 1990; **7**: 97 – 100.
- 6 Brazilai A, Choen HA. Isolation of group A streptococci from children with perianal cellulitis and from their siblings. *Pediatr Infect Dis J*. 1998; **17**: 358 – 360.
- 7 Mostafa WZ, Arnaout HH, el-Lawindi ML, el-Abidin YM. An epidemiologic study of perianal dermatitis among children in Egypt. *Pediatr Dermatol*. 1997; **14**: 351 – 354.
- 8 Montemarano AD, James WD. *Staphylococcus aureus* as a cause of perianal dermatitis. *Pediatr Dermatol*. 1993; **10**: 259 – 262.
- 9 Duhra P, Ilchysyna A. Perianal streptococcal cellulitis with penile involvement. *Br J Dermatol*. 1990; **123**: 793 – 796.
- 10 Patrizi A, Costa AM, Fiorillo L, Neri L. Perianal streptococcal dermatitis associated with guttate psoriasis and/or balanoposthitis: a study of five cases. *Pediatr Dermatol*. 1994; **11**: 168 – 171.
- 11 Teillac-Hamel D, de Prost Y. Perianal streptococcal dermatitis in children. *Eur J Dermatol*. 1992; **2**: 71 – 74.
- 12 Honig PJ. Guttate psoriasis associated with perianal streptococcal disease. *J Pediatr*. 1988; **113**: 1037 – 1039.
- 13 Rehder PA, Eliezer ET, Lane AT. Perianal cellulitis. Cutaneous group A streptococcal disease. *Arch Dermatol*. 1988; **124**: 702 – 704.
- 14 Horiuchi N, Aiba S, Ozawa H, Sugawara S, Rikiishi H, Kumagai K, et al. Peripheral blood lymphocytes from psoriatic patients are hyporesponsive to beta-hemolytic streptococcal superantigens. *Br J Dermatol*. 1998; **138**: 229 – 235.
- 15 Tonkovic-Capin V, Fleming MG, Kleven-Kranz K, Lund MR. Vulvovaginitis and perianal cellulitis due to group A streptococcus in an adult woman. *Ach Dermatol*. 2005; **141**: 790 – 792.
- 16 Stricker T, Navratil F, Sennhauser FH. Vulvovaginitis in prepubertal girls. *Arc Dis Child*. 2003; **88**: 324 – 326.

- 17 Gilbert DN, Moellening RC, Sande MS. *The Sanford Guide to Antimicrobial Therapy*. Hyde Park Vt: Antimicrobial Therapy, Inc.; 1998.
- 18 Wright JE, Butt HL. Perianal infection with beta-hemolytic streptococcus. *Arch Dis Child*. 1994; **70**:

145 – 146.

- 19 Medina S, Gomez ML, de Misa RF, Ledo A. Perianal streptococcal cellulitis: treatment with topical mupirocin. *Dermatology*. 1992; **185**: 219.



Niavaran Palace, Tehran, Iran. Photo by S.M. Aznaveh, Yassavoli  
Publication