
Case Report

Neuropathic Osteoarthropathy in a Patient with Congenital Insensitivity to Pain

Maryam Mobini MD*, Ali Javadzadeh MD**, Jafar Forghanizadeh MD**

This report describes a 23-year-old man who presented with multiple joint deformities as a consequence of multiple painless intra-articular fractures.

Blood counts, biochemistry, and nerve conduction velocity were all normal. X-ray studies showed joint destruction in hips, elbows and knees.

We concluded that he is a case of congenital insensitivity to pain culminating in multiple charcot joints.

Archives of Iranian Medicine, Volume 12, Number 6, 2009: 599 – 602.

Keywords: Insensitivity to pain • neuropathic joint

Introduction

Congenital insensitivity to pain is a group of rare hereditary sensory and autonomic neuropathies (HSANs). These patients lack deep pain sensation and develop a plethora of bone and joint complications.¹ They have been categorized into five different types, although some children do not fit well into this classification.^{2,3} We report a case of congenital insensitivity to pain with painless large joint destruction and no history of a similar disorder in the family.

Case Report

A 23-year-old man presented for evaluation of multiple deformities in his upper and lower extremities.

Deformities started from age 11 when his first fracture occurred in the right hip with no pain.

Afterwards, other joint deformities occurred in the elbows, right knee and left hip. The fractures were mainly neglected because of lack of pain.

The patient had four siblings. His parents were cosines. He had no history of drug abuse, cigarette smoking, diabetes or alcohol consumption but he had some episodes of hyperpyrexia and anhidrosis. On examination the patient appeared well with a pulse rate of 78 beats/min and blood pressure of 120/80 mm Hg. Physical examination of the skin, nails, heart and lungs were unremarkable. Examination of the skeletal system showed multiple joint deformities in his large peripheral joints without any pain (Figure 1). Abnormal joint alignment was a result of articular structures and the ensuing faulty healing process. Peripheral small joints were normal without any deformity or swelling. Neurological examination of the patient revealed normal mental development and normal

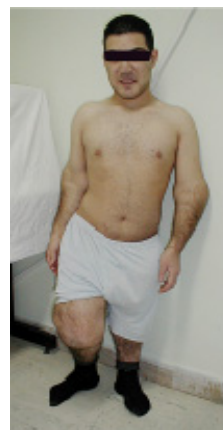


Figure 1. Deformities in limbs

Authors' affiliations: *Division of Internal Medicine, Mazandaran University of Medical Sciences, **Department of Medicine, Division of Rheumatology, Hazrat Rasool Hospital, Iran University of Medical Sciences, Tehran, Iran.

Corresponding author and reprints: Maryam Mobini MD, Division of Internal Medicine, Mazandaran University of Medical Sciences, Imam Khomeini Hospital, Razi Ave., Sari 4816633131, Iran. Email: mmobini50@yahoo.com

Accepted for publication: 4 December 2008

deep tendon reflexes. There was no muscular atrophy or ataxia. He was responsive to painful and thermal stimuli in the distal extremities.

Hematological tests included: white blood count, 6800; hemoglobin, 15.8; platelet count, 168000; fasting blood sugar, 95; blood urea nitrogen, 6; serum creatinine, 0.9; serum sodium, 140; serum potassium, 3.9. Venereal disease research laboratory (VDRL) was negative. Nerve conduction velocity and electromyography studies showed no abnormality. The patient refused sural nerve biopsy.

Radiographs showed joint destruction in the hips, elbows and right knee. The distal ends of the involved bones were irregularly destroyed and fragmentations of the articular osseous debris were found (Figures 2 and 3). There was not any fragility fracture. Vertebral X-ray was normal.

Discussion

Hereditary peripheral neuropathies have been classified based on their clinical characteristics; mode of inheritance, electrophysiological features, metabolic defects and specific genetic markers.² The major feature of hereditary sensory autonomic neuropathies (HSANs) is loss of large myelinated and unmyelinated nerve fibers. They have been categorized into types one through five, although some children do not fit well into this classification (Table 1).^{2,3}

Orthopedic consequences (osteomyelitis, Charcot arthropathy, dislocations, and fractures) often lead to the diagnosis and have important prognostic implications.⁴ HSAN type 1 is characterized by progressive degeneration of

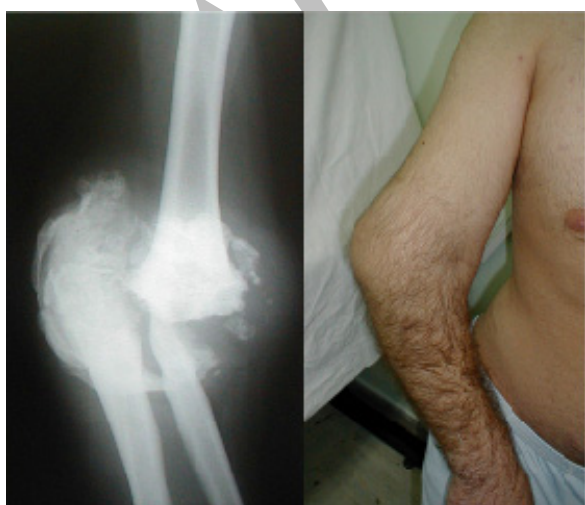

Figure 2. Deformity in elbow

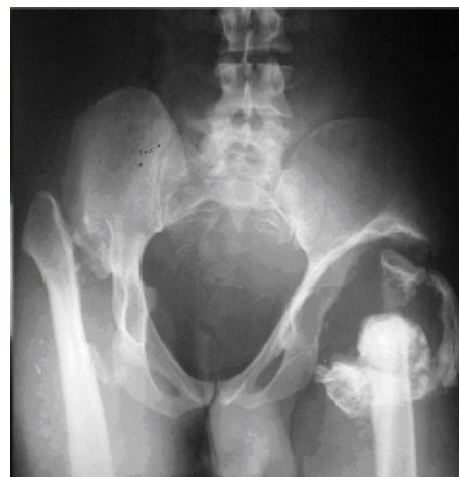

Figure 3. Joint destruction in hip

dorsal root ganglia and motor neurons, leading to distal sensory loss and later in the course of disease, distal muscle wasting, weakness and variable degrees of neural deafness.^{5,6} Most cases of HSAN type 1 show an autosomal dominant mode of inheritance.

HSAN type 2 is transmitted as an autosomal recessive trait characterized by loss of pain, temperature, pressure and touch sensation following large and small nerve fiber involvement.^{2,7} Recurrent infections of the digits and fractures occur in early childhood, with mutilation of the fingers and toes that occurs as the disease progresses.

HSAN type 3 is a progressive sensorimotor neuropathy but the resultant autonomic dysfunction is responsible for most of its clinical manifestations.⁸ This disorder is transmitted as an autosomal recessive trait and is essentially limited to children of Ashkenazi Jewish descent.

HSAN type 4 is an autosomal recessive disorder. Symptoms begin early in infancy and its prominent features include profound loss of pain sensitivity leading to injuries, self mutilation, and osteomyelitis.⁹ Loss of oral sensation leads to mutilation of the face and mouth. Episodic hyperthermia that can be associated with seizures and mild to moderate mental retardation is often present.^{10,11} The abnormal pain and temperature sensation as well as anhidrosis in HSAN type 4 is due to the absence of the afferent neurons and loss of eccrine sweat gland innervation.¹²

Patients with HSAN type 5 present with loss of pain and temperature sensation, but other sensations are preserved.¹³

Muscle strength, deep tendon reflexes, and nerve conduction studies are normal. Sural nerve

Table 1. Hereditary sensory and autonomic neuropathies (HSAN)

	HSAN type 1	HSAN type 2	HSAN type 3	HSAN type 4	HSAN type 5
Inheritance	AD-AR	AR	AR	AR	AR
Age of onset	Second decade or later	Infancy	Birth	Birth	Birth
Insensitivity to pain	++	++	+	++	++
Hidrosis	Normal	Normal	Decreased	Decreased	Normal
Mental retardation	Absent	-/+	+	++	+/-
Muscle hypotonia	Absent	Absent	+	Absent	Absent
Deep tendon reflexes	Absent	Absent	Often absent	Normal/decreased	Normal
Motor nerve conduction velocity	Variable	Mildly slowed	Normal/decreased	Normal/decreased	Normal
Sensory nerve conduction velocity	Low/absent	Low/absent	Low/absent	Low/absent	Normal
Biopsy findings	Loss of UF>MF	Absent MF	Reduced UF	Absent UF	Absent small MF

AD=autosomal dominant; AR=autosomal recessive; UF=unmyelinated fibers; MF=myelinated fibers (Modified from reference 15)

biopsy in this type shows the absence of small myelinated fibers, with preservation of the large fibers. Inheritance of this type is autosomal recessive. HSAN type 5 appears to be caused by a mutation in the nerve growth factor beta gene on chromosome 1.¹⁴

The clinical picture of our patient with an impaired sense of pain that started in the early second decade of his life without mental retardation, muscle hypotonia and normal nerve conduction velocity suggests the diagnosis of HSAN type 5. Given the absence of any apparent abnormality of the central or peripheral nervous system and normal nerve conduction velocity in our patient, we believe that he fits well into HSAN type 5. This patient however appears to be different from other reported cases of insensitivity to pain described in the medical literature in the presence of autonomic dysfunction and lack of any similar case in his family.

In 2002 Karkashan et al. reported a case-series of four related families with HSAN type 5 from Saudi Arabia. Most of those patients had painless injuries resulting in fractures, cuts, and bruises. Those patients had normal intelligence and other sensory modalities, deep tendon reflexes and sweating were normal.¹⁵ In 2006 Minde et al. presented six patients from a Swedish family with a mutation in the nerve growth factor beta that had similar presentation.¹ In 2006, Hu et al. reported a 12 year-old boy with congenital insensitivity to pain that had no family history of the disease and had non-consanguineous parents.¹⁶

Since there is no known cure for this disorder, emphasis on prevention of trauma is of utmost importance.¹⁵ The management of adult patients

with such conditions consists mainly of the use of orthoses and rehabilitation because the major problem is deformity and its consequences, not pain.¹

References

- 1 Minde J, Svensson O, Holmberg M, Solders G, Toolanen G. Orthopedic aspect of familial insensitivity to pain due to a novel nerve growth factor beta mutation. *Acta Orthopaedica*. 2006; **77**: 198 – 202.
- 2 Dyck PJ. Neuronal atrophy and degeneration predominantly affecting peripheral sensory and autonomic neurons. In: Dyck PJ, ed. *Peripheral Neuropathy*. Philadelphia: Saunders; 1993: 1065.
- 3 Thomas PK. Hereditary sensory neuropathies. *Brain Pathol*. 1993; **3**: 157 – 163.
- 4 Brofen C, Bensahel H, Teule JG. Orthopedic aspects of congenital insensitivity to pain. *Chir Pediatr*. 1985; **26**: 193 – 196.
- 5 Fitzpatrick DB, Hooper RE, Seife B. Hereditary deafness and sensory radicular neuropathy. *Arch Otolaryngol*. 1976; **102**: 552 – 557.
- 6 Houlden H, King R, Blake J, Grorers M, Love S, Woodward C, et al. Clinical, pathological, and genetic characterization of hereditary sensory and autonomic neuropathy type 1 (HSAN I). *Brain*. 2006; **129**: 411 – 425.
- 7 Ota M, Ellefson RD, Lambert EH, Dyck PJ. Hereditary sensory neuropathy, type II. Clinical, electrophysiologic, histologic, and biochemical studies of a Quebec kinship. *Neuro*. 1973; **29**: 23 – 37.
- 8 Danics J, Smith AA. Familial dysautonomia. *N Engl J Med*. 1966; **274**: 207 – 209.
- 9 Rosemberg S, Marie SK, Kliemann S. Congenital insensitivity to pain with anhidrosis (hereditary sensory and autonomic neuropathy type IV). *Pediatr Neurol*. 1994; **11**: 50 – 56.
- 10 Toscano E, Casa R, Mardy S, Gaetaniello L, Sadile F, Indo Y, et al. Multisystem involvement in congenital insensitivity to pain with anhidrosis (CIPA), a nerve growth factor receptor (Trk A)-related disorder.

- Neuropediatrics. 2000; **31**: 39 – 41.
- 11 Indo Y, Tsuruta M, Hayashida Y, Karim MA, Ohta K, Kawano T, et al. Mutations in the TRKA/NGF receptor gene in patients with congenital insensitivity to pain with anhidrosis. *Nat Genet.* 1996; **13**: 485 – 488.
 - 12 Indo Y. Genetics of congenital insensitivity to pain with anhidrosis (CIPA) or hereditary sensory and autonomic neuropathy type IV. Clinical, biological and molecular aspects of mutations in TRKA (NTRK1) gene encoding the receptor tyrosine kinase for nerve growth factor. *Clin Auton Res.* 2002; **12 (suppl 1)**: 120 – 132.
 - 13 Dyck PJ, Mellinger JF, Reagan TJ, Horowitz SJ, McDonald JW, Litchy WJ, et al. Not indifference to pain but varieties of hereditary sensory and autonomic neuropathy. *Brain.* 1983; **106**: 373 – 390.
 - 14 Einarsdottir E, Carlsson A, Minde J, Toolanen G, Svensson O, Solders G, et al. A mutation in the nerve growth factor beta gene (NGFB) causes loss of pain perception. *J Hum Mol Genet.* 1979; **13**: 799 – 805.
 - 15 Karkashan E, Joharji H, Al-Harbi N. Congenital insensitivity to pain in four related Saudi families. *Pediatr Dermatol.* 2002; **19**: 333 – 335.
 - 16 Hu J, Zhang A, Lin Zh, Zhou J. Congenital insensitivity to pain with anhidrosis and progressing acro-osteolysis: a case report with 7-year follow-up. *Chin Med J.* 2006; **119**: 2134 – 2137.

Archive of SID