

## Quantitative Study of the Effects of Morphine on the Mouse Spleen and Inguinal Lymph Node

Zahra Vojdani PhD<sup>1</sup>, Farzaneh Dehghani PhD<sup>2</sup>, Fatemeh Seyedi BS<sup>3</sup>, Ali Noorafshan PhD<sup>4</sup>, Faegheh Bahal-din Bagi PhD<sup>5</sup>

### Abstract:

**Background:** Morphine, as a narcotic analgesic drug, can suppress the immune system including the spleen and lymph node during long-term administration. Quantitative studies can be an appropriate indicator for the assessment of organ disturbances. As such, this study aimed to determine the effect of chronic morphine treatment on the histological parameters of the spleen and lymph node, with the use of stereological methods.

**Methods:** Nineteen male mice were divided into two groups, experimental and control. Addiction was induced by administration of 0.5% morphine solution in the experimental group. On day 71, after a physical dependency test, the animals were deeply anesthetized, dissected and their spleens and inguinal lymph nodes were removed. After histological preparation, the sections with a constant distance were selected and stained with hematoxylin-eosin. The total volume, red pulp, white pulp, and trabecular volume of the spleen as well as the total volume, cortex, nodule, medulla, medullary cord, and medullary sinus of the inguinal lymph node were calculated by Cavalieri's and point-counting methods. Data were analyzed with the Mann-Whitney U test.

**Results:** The mean total volume  $34.87 \pm 6.74 \text{ mm}^3$ , mean white  $9.57 \pm 2.66 \text{ mm}^3$  and red pulp volume  $24.10 \pm 4.65 \text{ mm}^3$  of the spleen in the experimental group decreased significantly [ $\sim 44\%$  ( $P < 0.001$ ),  $\sim 43\%$  ( $P < 0.003$ ), and  $\sim 39.5\%$  ( $P < 0.001$ ), respectively]. The mean cortex  $4.37 \pm 1.39 \text{ mm}^3$  and nodule volume  $1.67 \pm 0.70 \text{ mm}^3$  of the inguinal lymph node in the experimental group decreased significantly ( $P < 0.04$ ;  $\sim 31\%$  and  $\sim 29.5\%$ , respectively). In addition, the white blood cell count decreased in the experimental group  $7.12 \pm 2.7$  ( $\sim 21\%$ ).

**Conclusions:** Long-term use of morphine can suppress the immune system by reducing both the spleen and inguinal lymph node volume, and white blood cells.

**Keywords:** inguinal lymph node, morphine, spleen, stereology

### Introduction

Addiction has been one of the most notorious problems in recent years. It has negatively impacted

**Authors' affiliations:** <sup>1</sup>Anatomy Department, Shiraz University of Medical Sciences, Shiraz, Iran, <sup>2</sup>Histomorphometry and Stereology Research Centre, Shiraz University of Medical Sciences, Shiraz, Iran, <sup>3</sup>Department of Anatomy, Shiraz University of Medical Sciences, Shiraz, Iran, <sup>4</sup>Department of Anatomy, Histomorphometry and Stereology Research Centre, Shiraz University of Medical Sciences, Shiraz, Iran, <sup>5</sup>Department of Pharmacology, Shiraz University of Medical Sciences, Shiraz, Iran

**Corresponding author and reprints:** Zahra Vojdani PhD, Anatomy Department, Shiraz University of Medical Sciences, Shiraz, Iran. Tel: +98-711-230-4372, Fax: +98-711-230-4372, E-mail: vojdaniz@sums.ac.ir

Accepted for publication: 20 December 2009

not only health but also social, economic, and cultural conditions.<sup>1,2</sup> The most common drugs abused are opiates including opium, codeine, morphine, and heroin. Morphine, a narcotic analgesic drug, is the main alkaloid of opium.<sup>3</sup> *In vitro* studies with innate immune cells from experimental animals and humans and *in vivo* studies with animal models have shown that opiate abuse impairs innate immunity and is responsible for increased susceptibility to bacterial infection.<sup>4</sup>

Chronic administration of morphine can cause various disorders such as respiratory depression through a direct effect on the brain stem<sup>5</sup> and heart rate depression through vasodilatation of the peripheral

vessels in the body.<sup>6</sup> In the gastrointestinal system, although its most common and debilitating symptom is constipation, the impact of opioid-induced bowel dysfunction (OBD) extends beyond constipation to encompass a myriad of gastrointestinal (GI) signs and symptoms, ranging from decreased gastric emptying and reflux to abdominal pain, cramping, bloating, nausea, and vomiting.<sup>7</sup>

Morphine weakens the immune system's activity and inhibits immune response in the spleen, thymus and lymph node.<sup>8</sup> Studies have shown that morphine causes spleen atrophy<sup>9</sup> and reduces the number of natural killer cells,<sup>10,11</sup> B and T lymphocytes.<sup>12,13</sup>

Currently, a stereological method called "three dimension studies" is widely used to measure quantitative changes in tissues. The method used to determine the volumes of various subdivisions of organs is the Cavalieri principle. According to this principle, the volume of arbitrarily complex structures can be estimated from the sum of parallel areas separated by a known distance, provided that the set of sections is positioned randomly with respect to the chosen axis.<sup>14</sup> Profile areas are most efficiently estimated by point counting.<sup>15,16</sup> It is obvious that qualitative explanations of histological changes such as atrophy or hypertrophy are inadequate for comparing histological parameters. Such an experiment should be associated with quantitative parameters and describe the histological changes in a quantitative form. These parameters will show us to what degree the structure is smaller (atrophic) or larger (hypertrophic), and a more precise comparison can be made. Qualitative studies, however, cannot reveal such changes. Therefore, the aim of this study was to investigate the effects of morphine on the spleen's volume by the Cavalieri principle.

## Materials and Methods

### Animals and treatments

Nineteen male Balb/c mice (25 – 30 g) were randomly selected from the Laboratory Animal Center of Shiraz University of Medical Sciences and maintained one week before the experiments under standard conditions (12 hr light/dark cycle and 22±20°C). They were divided into two groups, experimental (n=9) and control (n=10). Both groups had continual free access to commercial chow pellets,

however, animals were allowed access to water from 10 a.m. to 17 p.m. in order to acclimate them to drinking during this period.<sup>17</sup>

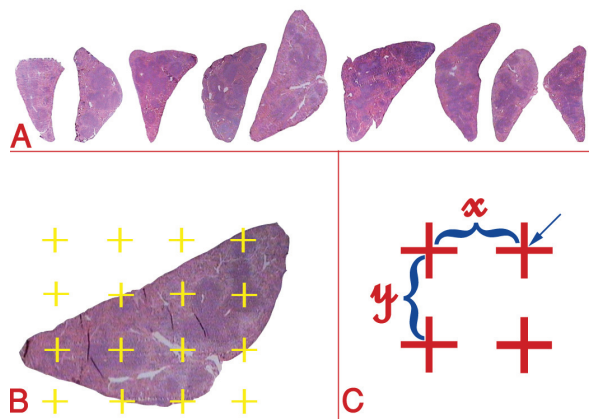
After one week, the experimental group was given two bottles of morphine solution 0.5% and water whereas the control group had only two bottles of water. The volume of water, 0.5% morphine and weight of food in each cage were recorded before 9 a.m. and after 17 p.m.<sup>17</sup>

On the 71<sup>st</sup> day, naloxon hydrochloride, 2.5 mg/kg, was injected intraperitoneally to precipitate withdrawal syndrome.<sup>18</sup> The symptoms of withdrawal syndrome including diarrhea, jumping, and escape attempts during a 20 minute period were recorded. After conducting a physical dependency test,<sup>18,19</sup> the findings indicated a positive withdrawal syndrome in the experimental group. In accordance with the Iran Veterinary Organization Ethics in Shiraz University of Medical Sciences, the animals were deeply anesthetized with ether and 1 mL blood was collected from the heart and refrigerated until white blood cells were counted. After tissue fixation by vascular perfusion with 4% buffered formalin, the spleen and inguinal lymph node were removed. Their weights were measured by a digital scale and lengths were determined by caliper. Subsequently, the tissues were fixed in buffered formalin for one week before histological processing and paraffin blocking.

### Stereological study

The Cavalieri principle was pursued to obtain an unbiased estimate of the total volume of the spleen or lymph node (reference volume;  $V_{ref}$ ).<sup>20,21</sup>

For the stereological study, the entire organs (spleen or lymph node) were sectioned serially at 5 µm thicknesses. The volume was obtained using a uniform random systematic sampling. Briefly, for each spleen or lymph node, 8 – 12 sections were sampled in a systematic random manner, i.e., selecting in equal distance and with a random start point (Figure 1). The sections were collected on glass slides and stained with hematoxylin and eosin. The microscopic images of the spleen or lymph nodes were projected on the laboratory table using a projecting microscope. A test system (grid) comprised of points was superimposed on the image at a final linear magnification of 54× and 30× for estimation of the spleen and lymph node volumes, respectively (Figure 1).



**Figure 1.** Stereological study of the spleen. **A)** Cavalieri principle, the entire spleen was sectioned, about 8 – 12 sections were sampled. (here 9) in a systematic random manner by using the formula:  $V_{ref} = T \times \Sigma A$ , “ $\Sigma A$ ” was obtained by  $\Sigma p \times (a/p)$ , “ $T$ ” was the distance between the adjacent sections. **B)** The grid of points was superimposed on the spleen section. The total number of points ( $\Sigma p$ ) hitting the sampled sections was counted. **C)** “ $(a/p)$ ” was the area associated with each point of the grid and calculated by the following formula:  $(a/p) = (\Delta x \times \Delta y) / M^2$ , where “ $\Delta x$ ” and “ $\Delta y$ ” were the distance between two adjacent points of the grid in the x-axis or y-axis, respectively. “ $M$ ” was the final magnification of the image. The right upper corner of each cross is considered a point.

The spleen or lymph node volume was estimated by multiplying the sum of the section areas ( $\Sigma A$ ) by the distance between sampled sections ( $T$ ). The volume was estimated as:

$$V_{ref} = T \times \Sigma A$$

“ $\Sigma A$ ” was obtained by  $\Sigma p \times (a/p)$

Where “ $\Sigma p$ ” was total number of points hitting the sampled sections and “ $(a/p)$ ” was the area associated with each point of the grid which was calculated by the following formula:

$$(a/p) = (\Delta x \times \Delta y) / M^2$$

Where “ $\Delta x$ ” and “ $\Delta y$ ” were the distance between two adjacent points of the grid in the x-axis or y-axis, respectively (Figure 1). “ $M$ ” was the final linear magnification of the microscopic images.<sup>20,21</sup>

In addition, in the stereological study of the spleen; the volume of the white pulp, red pulp, and trabecula were estimated. In the lymph node, the volume

of the cortex, medulla, follicle, medullary cord, and medullary sinus were also estimated. At first, the volume fraction of the above mentioned histological parameters were estimated. Volume fraction, or the fraction of each organ (spleen or lymph node) that had been occupied by a structure was estimated. Consequently to achieve absolute volume of the parameters and to prevent the reference trap<sup>20</sup> the volume fraction multiplied by the organ (spleen or lymph node) volume. Reference trap refers to an erroneous conclusion made by comparison of the fraction and not their absolute volume.

To estimate volume fraction ( $V_v$ ) of the above mentioned histological parameters the following formula was used:

$$V_v = p_{(structure)} / p_{(reference)}$$

Where the “ $p_{(structure)}$ ” was the numbers of points hitting the histological structures and “ $p_{(reference)}$ ” was the total number of points hitting the reference histological space (Figure 1).

#### White blood cell count

The number of WBCs including, lymphocytes, neutrophils, monocytes, eosinophils, and basophils were estimated using the Wright staining method in both the control and experimental groups.

#### Statistical analysis

The spleen weight, total volume, mean white pulp, red pulp, and trabecular volume of the spleen and total volume, cortex, nodule, medulla, medullary cord, and sinus of the inguinal lymph node in addition to the white blood cell count of the control and experimental groups were analyzed using the non-parametric test (Mann-Whitney U test).

#### Results

Naloxon hydrochloride was injected to precipitate withdrawal syndrome. The symptoms of withdrawal syndrome including diarrhea, jumping, and escape attempt and tremor during a 20 minute period were recorded. Table 1 indicates positive withdrawal syndromes in the experimental group. Table 2 shows the mean white blood cell count. Morphine caused an approximately 21% decrease in the peripheral

**Table 1.** Comparison of withdrawal syndrome symptoms during 20 min following naloxon hydrochloride injection (2.5 mg)

Symptoms	Control	Experimental	P-value
Jumping	10.1± 4.2	31.3±9.7	0.008
Escape	25.1 ±9.2	39.8± 11.1	0.02
Diarrhea	0	3.3 ±2.0	0.002
Tremor	0 (0%)	8 (83%)	<0.001

**Table 2.** Comparison of the number of blood leukocytes in the experimental and control groups. Total WBC ( $10^3$  cells/ml)

Blood cell number	Control	Experiment	P-value
WBC	9.1±2.4	7.1±2.7	0.105
Lymphocytes	5.9±1.5	4.7± 2	0.155
Neutrophils	3.1±1.2	2.2± 1.3	0.137
Monocytes	0.5±0.9	0.4±0.5	0.772
Basophils	0.2±0.4	0.2±0.4	1
Eosinophils	0.1±0.3	0.2±0.6	0.646

\*Results are listed as mean +SD

**Table 3.** Mean and standard deviation of various parameters in the control and experimental groups

Parameters	Control	Experiment	P-value
Spleen weight (mg)	160.21±31.84	101.82±21.82	0.001
Spleen volume (mm <sup>3</sup> )	58.81±12.8	34.87±6.74	0.001
White pulp volume (mm <sup>3</sup> )	16.91±5.77	9.57±2.66	0.003
Red pulp volume (mm <sup>3</sup> )	39.91±7.74	24.10±4.65	0.001
Trabecular volume (mm <sup>3</sup> )	1.69±0.66	1.20±0.37	0.09
Lymph node weight (mg)	23.66±6.92	18.01±6.24	0.07
Lymph node volume (mm <sup>3</sup> )	8.88±3.09	6.67±2.21	0.02
Cortex volume (mm <sup>3</sup> )	6.32±2.06	4.37±1.39	0.04
Medulla volume (mm <sup>3</sup> )	2.55±1.13	2.30±0.95	0.08
Follicle volume (mm <sup>3</sup> )	2.49±0.65	1.67 ±0.70	0.04
Medullary cord volume (mm <sup>3</sup> )	2.25±0.99	2.07±0.90	0.09
Medullary sinus volume (mm <sup>3</sup> )	0.29±0.19	0.21±0.07	0.08

blood lymphocyte count in the experimental group. Stereological findings show (Table 3) that the mean total volume of the spleen in the experimental group decreased 44% in comparison with that in the control group. The mean of both the white and red pulp volume decreased 43% and 39.5%, respectively. The difference between the mean trabecular volume of the spleen in the experimental and control groups was not significant. Morphine reduced the mean total weight of the spleen by approximately 37% and the diameter of the white pulp by about 30% in the experimental group.

Stereological findings show (Table 3) that the mean of the total volume of the inguinal lymph node in the experimental group decreased 25% in comparison with that in the control group. The mean cortex volume of the inguinal lymph node and the volume of its nodule decreased 31% and 29.5%, respectively. The difference between the mean medullary volume of the inguinal lymph

node and their medullary cord and medullary sinus in the experimental and control groups were not significant.

The difference between the mean of the inguinal lymph node weight in the experimental and control groups was not significant.

## Discussion

Chronic morphine administration can reduce spleen weight,<sup>9,22</sup> spleen atrophy,<sup>9</sup> and suppress allogenic response in mouse lymph nodes.<sup>8,23</sup> Using unbiased stereological methods, the present study has demonstrated a reduction of the total spleen and lymph node volume. It is obvious that a decrease in total organ volume might have been a result of volume reduction in different organ components such as red pulp, white pulp, and trabecula within the spleen.

In the present study, morphine reduced the number



of white blood cells and lymphocytes in the peripheral blood. Jamali, et al. reported that acute morphine administration reduced white blood cells.<sup>24</sup> Flores and colleagues showed a decrease in peripheral lymphocytes two hours after morphine injection.<sup>25</sup> Houghtling et al. (2000) reported the inhibition of lymphocyte proliferation in the blood after acute morphine.<sup>26</sup> It seems that morphine can cause a reduction of the total spleen and lymph node volume by decreasing lymphocytes.

Despite overwhelming evidence that morphine induces immune suppression, it is still not conclusively known how this effect is mediated. Three mechanisms have been suggested: 1) a direct mechanism where opioids bind to opioid receptors on the immune cells and directly modulate the function of these cells,<sup>27</sup> 2) an indirect mechanism where opioids bind to classical opioid receptors in the CNS, causing the release of catecholamine and/or steroids, which then indirectly affect immune cells,<sup>22,28</sup> and 3) the third mechanism which speculates that morphine activates the sympathetic nervous system (SNS) causing increased circulating levels of epinephrine from the adrenal medulla and norepinephrine from the sympathetic nerve terminals.<sup>29</sup> Bryant et al. (1991) showed that implantation of morphine plate subcutaneously caused reduction of the T and B lymphocytes by increasing secretion of corticoestrogen and decreasing concavaline which is the lymphocyte growth factor.<sup>22</sup>

Our study showed the most reduction in the outer cortex of the lymph node, but both white pulp and red pulp volume of the spleen also decreased. The outer cortex of the lymph node is mainly composed of lymphoid nodules and the interior part, as the germinal center, is rich in lymphoblasts and plasmoblasts.<sup>30</sup> Hydrocortisone can inhibit proliferation of mesenteric lymph node B lymphoblasts and plasmoblasts.<sup>31</sup> Buerki et al. showed that a high dose of a synthetic estrogen such as prednisolone caused deletion of the germinal center of the follicle.<sup>32</sup>

Therefore, it seems that morphine decreases the lymph node volume by reduction of germinal center lymphoblasts and plasmoblasts. These cells of the immune system are large proliferating cells that do not display surface immunoglobulins and are susceptible to death through apoptosis when compared to adult lymphocytes.<sup>33</sup> Morphine can not affect the medullary sinus and cord due to the lack of lympho-

blasts and plasmoblasts in these areas.

In this study, morphine decreased the mean white pulp and red pulp volume. White pulps are mainly composed of B and T lymphocytes and plasmoblasts.<sup>30</sup>

Some reports have shown that morphine reduces macrophages and B-cells in the spleen.<sup>12,34</sup> Stevens et al. has shown that apoptosis involved white pulp more than red pulp.<sup>35</sup> Indeed Garrido et al. has shown that dexametasone as a synthetic corticosteroid can decrease the white pulp of the spleen and the nodule of lymph nodes.<sup>36</sup> Tchernitchin et al. indicated that injection of estrogen caused reduction of the spleen's white pulp.<sup>37</sup>

The findings of this study revealed that morphine not only affects plasmoblasts and lymphoblasts of the white pulp, but it also decreases the red pulp. The red pulp contains lymphocytes, other blood cells, macrophages and APC.<sup>30</sup> Therefore, it is probable that morphine decreases other cells as well as plasmoblasts and lymphoblasts. Weber, Richard J et al. reported that morphine decreases cytotoxic activity of the natural killer cells<sup>11</sup> and macrophages of the spleen,<sup>34,38</sup> so it can reduce the red pulp volume. It seems that morphine decreases the spleen and lymph node volume mainly by reduction and apoptosis of plasmoblasts and lymphoblasts, but it has a lesser effect on macrophages and natural killer cells.

Trabecula of the spleen was the other parameter studied. No significant difference was found between the control and experimental groups. Weeks showed that morphine exhibited a reduction in cell adhesion to the matrix proteins and inhibited gelatinase secretion.<sup>39</sup> Morphine enhanced the accumulation of collagen type I in a dose-dependent manner and also increased the accumulation of collagen type III at a high concentration.<sup>40</sup> Singhal et al. (1997) speculated that morphine induced kidney fibroblast proliferation through the activation of early growth related genes, while it induced kidney fibroblast apoptosis through the generation of p53.<sup>41</sup> It seems that morphine manifests dual effects on connective tissue.

## Conclusion

Long-term use of morphine reduces total spleen volume due to the reduction of the white and red pulp volume in addition to a decrease in inguinal

lymph nodes due to a reduction of the cortex and their follicles. The number of blood lymphocytes also decreased.

### Acknowledgement

This study was financially supported by Shiraz University of Medical Sciences (grant number 83-2215). The authors also appreciate the assistance of the head of the Pharmacy Department, Dr. Panjehshahine, the staff of the animal house, and the anatomy research laboratory. This study was a part of the MS thesis that was done by F. Seyedi.

### References

- Noel RJ Jr, Rivera-Amill V, Bush S, Kumar A. Opiates, immune system, acquired immunodeficiency syndrome, and nonhuman primate model. *J Neurovirool.* 2008; **14**: 279 – 285.
- Friedman H, Newton C, Klein TW. Microbial infections, immunomodulation, and drugs of abuse. *Clin Microbiol Rev.* 2003; **16**: 209 – 219.
- Hagel JM, Macleod BP, Facchini PJ. Transgenic crops VI. In: Bajaj YPS, ed. *Biotechnology in Agriculture and Forestry*. Volume 61. New York: Springer Berlin Heidelberg; 2007: 169 – 187.
- Wang J, Barke RA, Ma J, Charboneau R, Roy S. Opiate abuse, innate immunity, and bacterial infectious diseases. *Arch Immunol Ther Exp (Warsz).* 2008; **56**: 299 – 309.
- Hutchinson MR, Northcutt AL, Chao LW, Kearney JJ, Zhang Y, Berkelhammer DL, et al. Minocycline suppresses morphine-induced respiratory depression, suppresses morphine-induced reward, and enhances systemic morphine-induced analgesia. *Brain Behav Immun.* 2008; **22**: 1248 – 1256.
- Brunton L, Lazo J, Parker K. Opioid analgesics. In: Goodman LS, Hardman JG, Limbird LE. *Gilman, Alfred Goodman, Goodman and Gilman's the Pharmacological Basis of Therapeutics*. New York: McGraw Hill. 11<sup>th</sup> ed. 2005; 547 – 591.
- Mehendale SR, Yuan CS. Opioid-induced gastrointestinal dysfunction. *Dig Dis.* 2006; **24**: 105 – 112.
- Vallejo R, de Leon-Casaola O, Benyamin R. Opioid therapy and immunosuppression. *Am J Ther.* 2004; **11**: 345 – 365.
- Gaveriaux-Ruff C, Matthes HW, Peluso J, Kieffer B. Abolition of morphine-immunosuppression in mice lacking the mu-opioid receptor gene. *Proc Natl Acad Sci U S A.* 1998; **95**: 6326 – 6330.
- Freier DO, Fuchs BA. A mechanism of action for morphine-induced immunosuppression: corticosterone mediates morphine-induced suppression of natural killer cell activity. *J Pharmacol Exp Ther.* 1994; **270**: 1127 – 1133.
- Weber-Richard J, Gomez-Flores R, Sora I, Uhl GR. Loss of morphine-induced suppression of NK cell activity and T-cell functions in m-opioid receptor knockout mice. *Am J Immunol.* 2006; **2**: 35 – 39.
- Vassou D, Bakogeorgou E, Kampa M, Dimitriou H, Hatzoglou A, Castanas E. Opioids modulate constitutive B-lymphocyte secretion. *Int Immunopharmacol.* 2008; **8**: 634 – 644.
- Zaki NG, Osman A, Moustafa H, Saad AH. Alterations of immune functions in heroin addicts. *Egypt J Immunol.* 2006; **13**: 153 – 171.
- Gundersen HJ, Jensen EB. The efficiency of systematic sampling in stereology and its prediction. *J Microsc.* 1987; **147**: 229 – 263.
- Jørgen H, Gundersen G, Boysen M, Reith A. Comparison of semiautomatic digitizer-tablet and simple point counting performance in morphometry. *Virchows Arch B Cell Pathol Incl Mol Pathol.* 1981; **37**: 317 – 325.
- Ishiyama G, Tokita J, Lopez I, Tang Y, Ishiyama A. Unbiased stereological estimation of the spiral ligament and stria vascularis volumes in aging and Ménière's disease using archival human temporal bones. *J Assoc Res Otolaryngol.* 2007; **8**: 8 – 17.
- Kumar R, Steinberg H, Stolerman IP. Inducing a preference for morphine in rats without premeditation. *Nature.* 1968; **218**: 564 – 565.
- Heron DA, Shinitzky M, Samuel D. Alleviation of drug withdrawal symptoms by treatment with a potent mixture of natural lipids. *Eur J Pharmacol.* 1982; **83**: 253 – 261.
- Kest B, Palmese CA, Hopkins E, Adler M, Juni A, Mogil JS. Naloxone-precipitated withdrawal jumping in 11 inbred mouse strains: evidence for common genetic mechanisms in acute and chronic morphine physical dependence. *Neuroscience.* 2002; **115**: 463 – 469.
- Gundersen HJ, Bendtsen TF, Korbo L, Marcussen N, Møller A, Nielsen K. et al. Some new, simple and efficient stereological methods and their use in pathological research and diagnosis. *APMIS.* 1988a; **96**: 379 – 394.
- Gundersen HJ, Bagger P, Benstsen TF, Evans SM, Korbo L, Marcussen N, et al. The new stereological tools: dissector, fractionators, nucleator, and point sampled intercepts and their use in pathological research and diagnosis. *APMIS.* 1988b; **96**: 857 – 881.
- Bryant HU, Bernton EW, Kenner JR, Holaday JW. Role of adrenal cortical activation in the immunosuppressive effects of chronic morphine treatment.

- Endocrinology*. 1991; **128**: 3253 – 3258.
23. Maity R, Mukherjee R, Skolnick P. Morphine inhibits the development of allogeneic immune responses in mouse lymph node. *Immunopharmacol*. 1995; **29**: 175 – 183.
  24. Jamali A, Bamdad T, Soleimanjahi H, Pakdel FG, Arefian E. Acute morphine administration reduces white blood cells' capability to induce innate resistance against HSV-1 infection in BALB/c mice. *Neuroimmunomodulation*. 2007; **14**: 16 – 23.
  25. Flores LR, Wahl SM, Bayer BM. Mechanisms of morphine-induced immunosuppression: effect of acute morphine administration on lymphocyte trafficking. *J Pharmacol Exp Ther*. 1995; **272**: 1246 – 1251.
  26. Houghtling RA, Mellon RD, Tan RJ, Bayer BM. Acute effects of morphine on blood lymphocyte proliferation and plasma IL-6 levels. *Ann NY Acad Sci*. 2000; **917**: 771 – 777.
  27. Núñez G, Urzúa J. Opioids and the immune system [in Spanish]. *Rev Med Chil*. 1999; **127**: 341 – 348.
  28. Freier DO, Fuchs BA. A mechanism of action for morphine-induced immunosuppression: corticosterone mediates morphine-induced suppression of natural killer cell activity. *J Pharmacol Exp Ther*. 1994; **270**: 1127 – 1133.
  29. Flores LR, Dretchen KL, Bayer BM. Potential role of the autonomic nervous system in the immunosuppressive effects of acute morphine administration. *Eur J Pharmacol*. 1996; **318**: 437 – 446.
  30. Janqueira LC, Carneiro J. *Basic Histology*. New York: McGraw-Hill; 2007.
  31. Fouhil AF, Turkall RM. Electron microscopic study on the effect of alternate-day hydrocortisone therapy on lymphocyte population in rat spleen and lymph nodes. *J Toxicol Pathol*. 1995; **23**: 72 – 82.
  32. Buerki H, Massner B, Cottier H, Chanana AD, Joel DD, Cronkite EP. Effects of lymph diversion versus corticosteroids on blood and lymphocyte pools. *Beitr Pathol*. 1976; **159**: 343 – 350.
  33. Knowles DM. *Neoplastic Hematopathology*. 2<sup>nd</sup> ed. Philadelphia: Lippincott Williams & Wilkins; 2000.
  34. Hilburger ME, Adler MW, Rogers TJ, Eisenstein TK. Morphine alters macrophage and lymphocyte population in the spleen and peritoneal cavity. *J Neuroimmunol*. 1997; **80**: 106 – 114.
  35. Stevenson JR, Westermann J, Liebmann PM, Hortner M, Rinner I, Felsner P, et al. Prolonged alpha-adrenergic stimulation causes change in leukocyte distribution and lymphocyte apoptosis in the rat. *J Neuroimmunol*. 2001; **120**: 50 – 57.
  36. Garrido E, Gomariz RP, Leceta J, Zapata A. Effects of dexamethasone on the lymphoid organs of *Rana perezi*. *Dev Comp Immunol*. 1987; **11**: 375 – 384.
  37. Tchernitchin AN, Carter W, Soto J, Baumann P. Effect of eosinophil-degranulating estrogens on spleen eosinophils and white pulp/red pulp ratio. *Agents Actions*. 1990; **31**: 249 – 256.
  38. Singhal PC, Sharma P, Kapasi AA, Reddy K, Franki N, Gibbons N. Morphine enhances macrophage apoptosis. *J Immunol*. 1988; **160**: 1886 – 1893.
  39. Weeks BS, Goldman S, Touma S, Payne M, Cadet P, Stefano GB. Morphine inhibits indolactam V-induced U937 cell adhesion and gelatinase secretion. *J Cell Physiol*. 2001; **189**: 179 – 188.
  40. Singhal PC, Sharma P, Gibbons N, Franki N, Kapasi A, Wagner JD. Effect of morphine on renomedullary interstitial cell proliferation and matrix accumulation. *Nephron*. 1997; **77**: 225 – 234.
  41. Singhal PC, Sharma P, Sanwal V, Prasad A, Kapasi A, Ranjan R, et al. Morphine modulates proliferation of kidney fibroblasts. *Kidney Int*. 1998; **53**: 350 – 357.