

Photoclinic

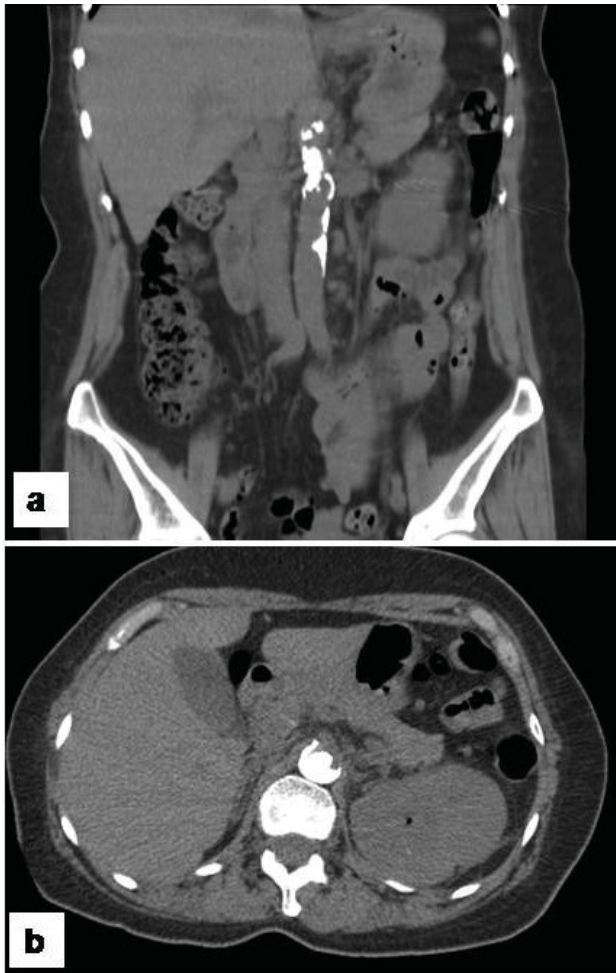

Figure 1. a) Coronal section of unenhanced computed tomography (CT) revealed a heavily calcified aortic lesion extending from the level of the superior mesenteric artery to the infra-renal artery. **b)** Axial section showed an incomplete occlusion of the aortic lumen.

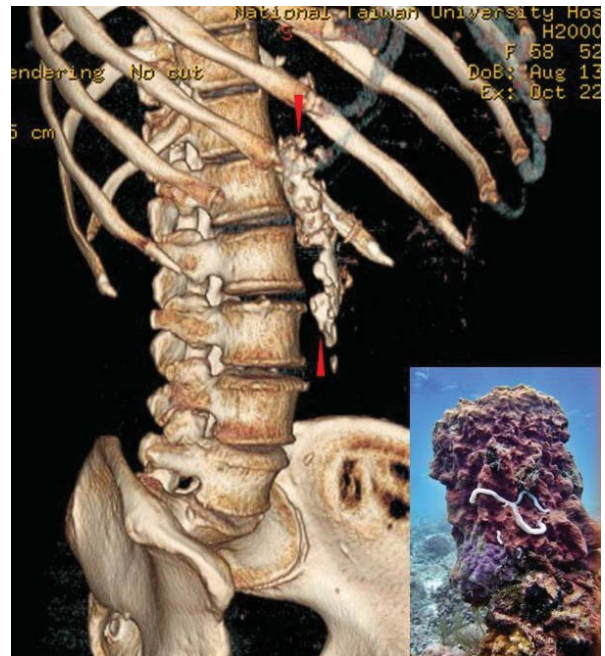


Figure 2. Unenhanced CT with volume-rendering reformation disclosed the aortic calcification with a rock-hard, irregular, gritty, and whitish surface resembling a coral reef (between arrowheads). Insert: typical appearance of a coral reef.

Cite this article as: Huang CC, Tsai CW, Kuo CC. Photoclinic. *Arch Iran Med.* 2012; 15(1): 63 – 64.

A 58-year-old woman presented with refractory hypertension and impaired renal function with a serum creatinine level that fluctuated between 176.8 and 221 $\mu\text{mol/L}$ (normal 61.9 – 132.5). In addition, intermittent claudication in the bilateral calf muscles

Chun-Chieh Huang MD¹, Ching-Wei Tsai MD², Chin-Chi Kuo MD²
Authors' affiliations: ¹Department of Medical Imaging, Far Eastern Memorial Hospital, New Taipei City, Taiwan, ²Department of Internal Medicine, National Taiwan University Hospital Yun-Lin Branch, Yun-Lin, Taiwan.
•Corresponding author and reprints: Chin-Chi Kuo MD, Department of Internal Medicine, National Taiwan University Hospital Yun-Lin Branch, Yun-Lin, Taiwan. Tel: +886-2- 2356-2570, Fax: +886-2- 2322-4552, E-mail: chinchik@gmail.com
 Accepted for publication: 18 May 2011

had been noted for one year. Physical examination revealed abdominal bruits and weak pulses in the bilateral lower extremities. Ankle brachial pressure indices (ABPI) were reduced symmetrically (right 0.63, left 0.57). Abdomino-pelvic computed tomography (CT) scan showed a severely calcified aorta from the level of superior mesenteric artery (SMA) to the infra-renal artery (Figure 1a), causing nearly total aortic luminal narrowing (Figure 1b) and atrophy of the right kidney.

What is your diagnosis?
 See the next page for diagnosis.

Photoclinic Diagnosis:

Coral Reef Aorta

Reconstructed unenhanced CT with volume-rendering reformation disclosed a typical picture of “coral-reef aorta” (CRA; Figure 2). CRA is a rare calcifying suprarenal aortic disease.¹ Although the pathogenesis of CRA remains uncertain, it has been suggested that this unique phenomenon may be attributed to calcification of a fibrin-platelet thrombus. It is distinct from the usual site of aortic atherosclerosis that involves the abdominal aortic bifurcation². The aortic obstruction results from a rock-hard, irregular gritty intra-aortic mass with a white luminal surface resembling coral reef (Figure 2, insert). The range of symptoms includes those of mesenteric ischemia, refractory renovascular hypertension, chronic kidney disease (CKD) with intermittent acute deterioration, and lower extremity ischemic symptoms due to flow limitation.^{1,2} The treatment of choice for hemodynamically unstable CRA is surgical endarterectomy.³

Acknowledgment

The authors would like to thank Ms. Asther Lau for her permission to use the coral reef photo.

References

1. Schulte KM, Reiher L, Grabitz L, Sandmann W. Coral reef aorta: A long-term study of 21 patients. *Ann Vasc Surg.* 2000; **14**: 626 – 633.
2. Grottemeyer D, Pourhassan S, Rehbein H, Voiculescu A, Reinecke P, Sandmann W. The coral reef aorta - a single centre experience in 70 patients. *Int J Angiol.* 2007; **16**: 98 – 105.
3. Holfeld J, Gottardi R, Zimpfer D, Dorfmeister M, Dumfarth J, Funovics M, et al. Treatment of symptomatic coral reef aorta by endovascular stent-graft placement. *Ann Thorac Surg.* 2008; **85**: 1817 – 1819.

Archive of SID