

## Case Report

# Primary Adrenal Hydatid Cyst Presenting with Arterial Hypertension

Maral Mokhtari MD<sup>1</sup>, Sam ZeraatianNejadDavani MD<sup>2</sup>

## Abstract

Hydatid disease is an endemic illness in some countries. The main sites of involvement are the liver and lungs, but rarely, it can be seen in other organs as well. Herein, we report a case of primary adrenal hydatid cyst accompanied by arterial hypertension.

**Keywords:** Adrenal gland, hydatid cyst, hypertension

**Cite this article as:** Mokhtari M, ZeraatianNejad Davani S. Primary Adrenal Hydatid Cyst Presenting with Arterial Hypertension. *Arch Iran Med.* 2012; **15**(5): 328 – 330.

## Introduction

Hydatid disease is a parasitic disease most commonly caused by the larval stage of the tapeworm *Echinococcus granulosus*.<sup>1</sup> Humans may become intermediate hosts through contact with a definitive host or by ingestion of contaminated water or vegetables.<sup>2</sup>

In humans, eggs hatch and embryos migrate through the intestinal mucosa before entering the portal circulation, causing hepatic hydatid disease. If embryos bypass the liver, they can reach the pulmonary circulation via the inferior vena cava, forming cysts in the lungs.<sup>2-5</sup> The most frequent sites of hydatid cyst involvement are the liver (45% – 75%) and lungs (10% – 50%).<sup>4</sup> Embryos may reach other organs or tissues in the body via the systemic circulation. These unusual sites include the brain, muscles, kidneys, heart, adrenals, and numerous other sites, all of which may cause preoperative diagnostic difficulties.<sup>1</sup>

The hydatid cyst wall has 3 layers of which the outermost layer is the pericyst, the middle layer is the laminated membrane, and the innermost layer is called the endocyst or germinal epithelium.<sup>1</sup>

Localization of the hydatid cyst in the adrenal glands is very rare (less than 1% of all cases).<sup>4,5</sup> Most reported cases have been discovered incidentally, but some adrenal hydatid disease has been reported to coexist with arterial hypertension.<sup>4-9</sup> There are a few reports of adrenal hydatid cyst presenting with symptoms suggestive of pheochromocytoma (episodes of headache, sweating, palpitations, and hypertension).<sup>5</sup>

Herein we report a case of primary adrenal hydatidosis, accompanied by arterial hypertension.

## Case report

A 66-year-old female referred to the Surgical Department at Fasa University of Medical Sciences with complaints of right flank

pain with radiation to her back. She had a 2-year history of arterial hypertension (systolic 150 – 170 and diastolic 95 – 105) and was on anti-hypertensive medications. Physical examination was unremarkable except for a blood pressure of 150/95. Laboratory examinations that included hematological and biochemical studies were within normal limits. As a part of the diagnostic workup, abdomino pelvic computed tomography scan (CT scan) and plain chest X-ray were performed. Chest X-ray was unremarkable; however the abdominal CT scan showed a solitary lesion measured 5 cm with coarse calcification in the right adrenal gland (Figure 1). The other organs were unremarkable. Due to the possibility of pheochromocytoma, the urine catecholamine level was measured which was normal. The patient underwent open laparotomy and a right adrenalectomy was performed.

Gross examination revealed a thick-walled, calcified cystic mass filled with an amorphous, fragile, creamy-white material measured 5.5×5 cm (Figures 2 A,B). Microscopic study showed a calcified cyst that had a fibrous wall with no epithelial lining. The cyst was filled with a pink amorphous material that contained rare hooklet of *echinococcus granulosus* (Figures 3 A, B, C).

The histologic diagnosis was primary adrenal hydatid cyst. The post-operative period was uneventful and the patient was discharged with normal blood pressure. Thus anti-hypertensive medications were discontinued. During the following 3 months, the patient remained normotensive.

## Discussion

Hydatid disease is a parasitic disease, endemic in Iran and some countries. Cysts located in organs other than the liver and lungs are usually manifestation of generalized disease.<sup>4</sup>

Adrenal gland involvement may be due to secondary spread resulting from spontaneous or intra-operative rupture of a primary cyst, but the primary hydatid cyst of the adrenal gland is a rare event.<sup>2</sup> Cysts of the adrenal glands are usually unilateral (90%) and show no special predilection for either side.<sup>4</sup>

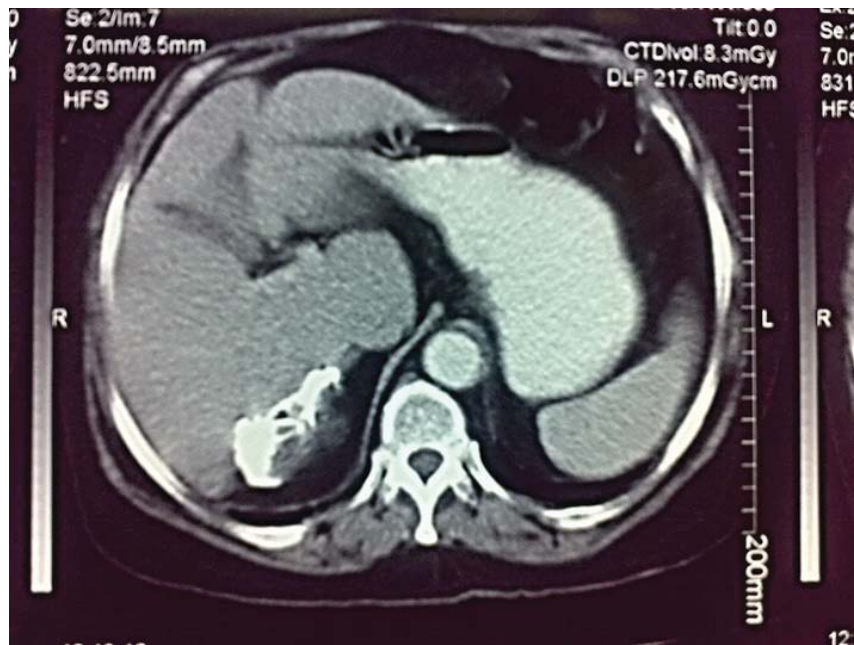Adrenal hydatid disease is slow-growing, there for it is usually an incidental discovery. When symptoms are present they are related to visceral compression. The most prominent features are flank pain, gastrointestinal symptoms (bloating, nausea, vomiting,

**Authors' Affiliations:**<sup>1</sup>Department of Pathology, Shiraz University of Medical Sciences, Shiraz, Iran, <sup>2</sup>Department of Surgery, Fasa University of Medical Sciences, Fasa, Iran.

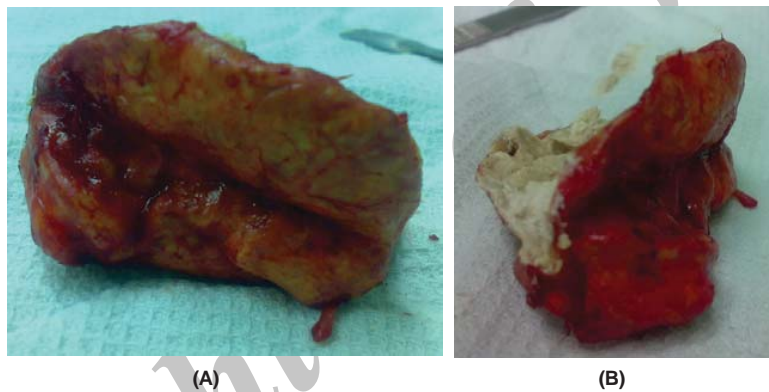
**Corresponding author and reprints:** Maral Mokhtari MD, Pathology Department, Shiraz University of Medical Sciences, Shiraz, Iran.

Fax: +987112301784, E-mail: maral\_mokhtari@yahoo.com.

Accepted for publication: 12 October 2011



**Figure 1.** Abdominal CT scan shows a calcified mass in the right adrenal gland.



**Figures 2 A,B.** Large cystic adrenal mass filled with chalky white material.

constipation, and anorexia) and a palpable mass.<sup>2,7</sup> Rarely, hydatid cyst coexists with arterial hypertension and is referred to as Goldblatt's phenomenon which may be caused by external compression of the renal artery by the cyst.<sup>3</sup> Some hypertensive patients have normal blood pressure after surgical removal of the hydatid cyst, as in our patient, however presence of adrenal hydatid cyst as the sole etiology of the hypertension is controversial. Some authors have reported that the hypertension may continue even after complete resection of the cyst.<sup>9</sup>

Nouria et al.<sup>5</sup> have reported a case of adrenal hydatid cyst with cardinal symptoms of pheochromocytoma and elevated Vanillylmandelic acid (VMA) level. They suggested that the elevation of catecholamine may be due to compression of the adrenal medulla by the cyst leading to catecholamine release.

In our case the urine VMA was within normal limits so the pressure effect on the adrenal medulla was a remote possibility. Compression of the renal artery may be the responsible cause of hypertension because of normalization of blood pressure after surgery.

Serological studies may help to diagnose hydatid cyst but they lack sensitivity and specificity. Imaging studies such as ultrasound, CT scan and MRI can assist with diagnosis, site of involvement,

the number of cysts, and possible complications.<sup>2</sup>

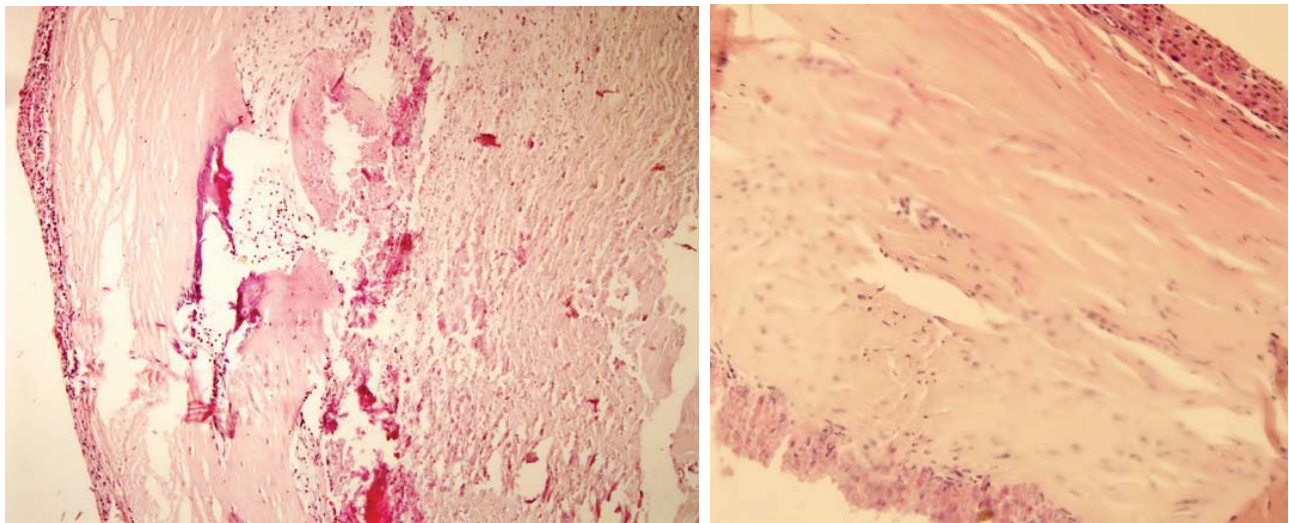
In radiologic modalities calcification is seen in about 20% of hydatid cysts and its presence in an adrenal mass is suggestive of hydatid cyst.<sup>2</sup>

The complications of adrenal hydatid disease include rupture, fistula formation, hemorrhage, and anaphylactic shock.<sup>2,7</sup>

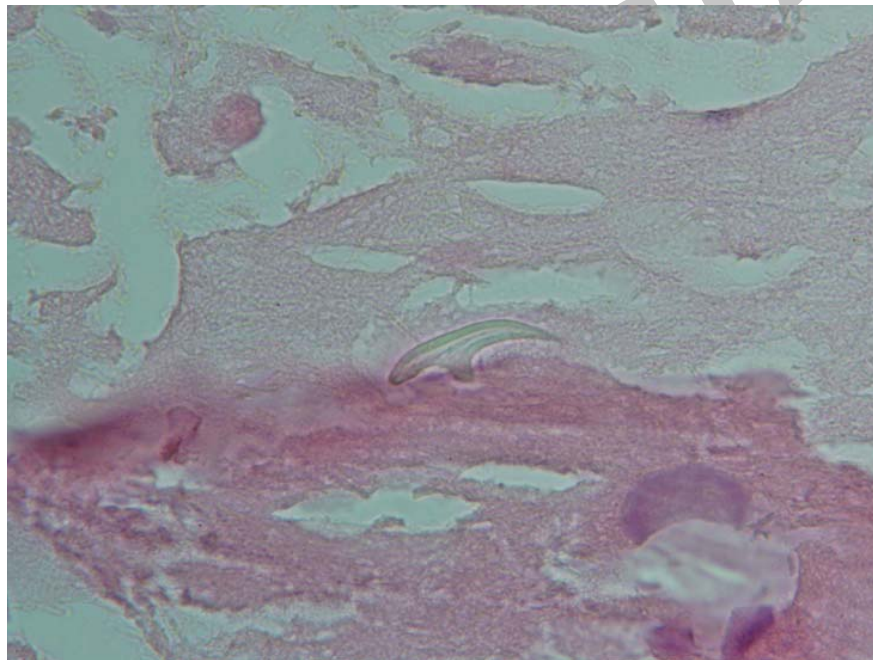
Differential diagnosis of an adrenal cyst include endothelial cyst, pseudocyst, cystic neoplasms such as lymphangioma, post-traumatic cyst, cystic pheochromocytoma, abscess, and other congenital or acquired cysts.<sup>2,4</sup>

## Conclusion

Primary hydatid cyst of the adrenal gland is a rare disease that may mimic many adrenal lesions, therefore it should be considered in the differential diagnosis of all adrenal cysts, particularly in endemic areas. This can be rarely accompanied by arterial hypertension as well as adrenal pheochromocytoma. Although imaging studies assist with diagnosis, however the exact nature of the adrenal hydatid cyst requires histologic examination.



(A) (B)  
**Figures 3A,B.** Fibrosed, calcified cyst wall with remnants of the adrenal cortex. H & E 100x, 400x.



**Figure 3C.** Hooklet of echinococcus granulosus. H & E, oil immersion.

## References

1. Yuskel M, Demirplat G, Sever A, Bakris S, Bulbuloglu E, Elmas N. Hydatid disease involving some rare locations in the body: Apictorial essay. *Korean J Radiol.* 2007; **8**: 531 – 540.
2. Sallami S, Ben Rhouma S, Horanchi A. Primary adrenal hydatid cyst: A case report. *Ibnosina J Med BS.* 2010; **2**(1): 38 – 41.
3. Abdulmajed M, Resorlu B, Kara C, Turkolmez K. Isolated primary hydatid cyst of adrenal gland: A case report. *Turkish Journal of Urology.* 2010; **36**(2): 211 – 215.
4. Dionigi G, Carrafiello G, Recaldini C, Sessa F, Boni L, Rovera F, et al. Laparoscopic resection of a primary hydatid cyst of the adrenal gland: A case report. *J Med Case Reports.* 2007; **1**: 61 .
5. Nouria Y, Benyounes A, Kbaier I, Attyaoui F, Horanchi A. Adrenal hydatid cyst presenting as a pheochromocytoma. *BJU International.* 2000; **86**(6): 754.
6. Escudero M, Sabater L, Calavete J, Camps B, Labios M, Liedo S. Arterial hypertension due to primary adrenal hydatid cyst. *Surgery.* 2002; **132**(5): 894 – 895.
7. Ozarmagan S, Erbil Y, Barbaros U, Salmaslioglu A, Bozboru A. Primary hydatid disease in the adrenal gland: A case report. *Braz J Infect Dis* 2006; **10** (5): 362 – 363.
8. Gurbuz R, Guven S, Klinc M, Abasiyanik F, Gokce G, Peskin M. Primary hydatid cyst in adrenal gland: A case report. *Int Urol Nephrol.* 2005; **37**: 21 – 23.
9. Safioleas MC, Moulakakis KG, Kostakis A. Coexistence of primary adrenal hydatid cyst and arterial hypertension: Reports of a case and review of the literature. *Acta Chir Belg.* 2006; **106**: 719 – 721.