

Original Article

Percutaneous Transvenous Mitral Commissurotomy: Significance of Echocardiographic Assessment in Prediction of Immediate Result

Hakimeh Sadeghian MD¹, Mojtaba Salarifar MD², Mehrnaz Rezvanfard MD³, Ebrahim Nematipour MD², Masoumeh Lotfi Tokaldany MD MPH³, Azam Safir Mardanloo MD¹, Hamid-Reza Poorhosseini MD², Vahid Semnani MD⁴

Abstract

Background: The current study aims to identify demographic, clinical characteristics, echocardiographic and/or mitral valve morphological parameters that may predict the successful result of percutaneous transvenous mitral commissurotomy (PTMC).

Methods: The medical records of 196 patients (48 males, mean age: 42.7 ± 11.5 years) who underwent PTMC were reviewed. Prior to PTMC, a combination of transthoracic and transesophageal echocardiography were used to investigate substantial mitral valve morphological subcomponents (thickening, mobility, calcification, and subvalvular thickness) and suitability for PTMC. The second transthoracic echocardiographic assessment was performed within six weeks after PTMC. Patients were divided into two categories of successful or unsuccessful according to PTMC results. Successful PTMC was defined as: final mitral valve area (MVA) ≥ 1.5 cm² without a post-procedure mitral regurgitation (MR) grade >2 . The significant predictor of the result was identified by comparing demographic data, initial echocardiographic assessment and mitral valve morphological scores within both groups.

Results: The mean MVA increased from 1.0 ± 0.2 cm² to 1.7 ± 0.4 cm², and mitral valve mean gradient (MVMG) decreased from 11.5 ± 5.2 to 5.2 ± 3.3 mmHg ($P < 0.001$ for both). Successful results were obtained in 139 (70.9%) patients compared to unsuccessful results in 57 (29.1%). Unsuccessful results were due to suboptimal secondary MVA < 1.5 cm² in 50 (25.5%) patients and post-procedure MR grade >2 in 7 (3.6%). Multiple logistic regression analysis indicated that young age, lower size of the left atrium (LA), and smaller degree of mitral valve thickness were the predictors of successful result.

Conclusion: Pre-procedure echocardiographic assessment appears to be helpful in predicting PTMC results. Successful PTMC is influenced by the patients' age, LA size, and mitral valve thickness.

Keywords: Echocardiographic assessment, immediate result, mitral valve morphology, percutaneous transvenous mitral commissurotomy

Cite the article as: Sadeghian H, Salarifar M, Rezvanfard M, Nematipour E, Lotfi Tokaldany M, Safir Mardanloo A, Poorhosseini MR, Semnani V. Percutaneous Transvenous Mitral Commissurotomy: Significance of Echocardiographic Assessment in Prediction of Immediate Result. *Arch Iran Med.* 2012; **15(10)**: 629 – 634.

Introduction

Since the introduction of percutaneous transvenous mitral commissurotomy (PTMC) in 1982 by Inoue, the procedure has been used extensively throughout the world as a non-surgical alternative in the treatment of mitral stenosis (MS) with gratifying results in a high percentage of patients.¹⁻⁵ One of the widely used definitions for a successful PTMC result is an increase in optimal mitral valve area (MVA) and absence of significant levels of mitral regurgitation (MR) under echocardiographic assessment.³⁻⁵ Most patients benefit immediately from this procedure^{3,6}; some may, however, show minimal clinical improvements due to a slight increase in MVA or potential complications.^{3,7-9} MR severity may increase in 25%–83% of cases.^{2,6,9} This well recognized complication is usually mild and well tolerated but may give rise to the production of significant MR in 2%–19% of

patients with the need for valve replacement in a few patients.^{3,10-12}

Patient selection may have an important impact on the result of percutaneous balloon mitral valvotomy.^{3,8,13,14} A pre-procedure echocardiographic assessment provides information on the structure of the mitral apparatus, the severity of the stenotic lesion and other possible valvular abnormalities.^{13,15,16} There is substantial controversy regarding predictors of the immediate result in patients undergoing PTMC. Whereas many investigators have previously demonstrated that the pathological or echocardiographic characteristics of the mitral valve may influence the increase in the MVA or MR grade following surgical or percutaneous mitral valvotomy,^{7,8,12,13,17,18} others disagree.^{9,11,15,19,20} However, still others believe that anatomy is only a relative predictor of immediate results and suggest other demographic and echocardiographic variables are predictive factors.^{4,14,21}

The echocardiographic score has been widely utilized to study the influence of morphological characteristics of the mitral valve on PTMC results.^{4-6,8,21} Most echocardiographic evaluations have considered the total echocardiographic score in the mitral valve morphological evaluation, while only a few studies have regarded the individual subcomponent scores (leaflet thickening, valve calcification, leaflet motility, and subvalvular thickness) to examine their value in the prediction of the immediate result.^{6,17,20} Furthermore, there is not a unique consensus on the morphologi-

Authors' affiliations: ¹Echocardiography Department, Tehran Heart Center, Tehran University of Medical Sciences, Tehran, Iran. ²Interventional cardiology Department, Tehran Heart Center, Tehran University of Medical Sciences, Tehran, Iran. ³Research Department, Tehran Heart Center, Tehran University of Medical Sciences, Tehran, Iran. ⁴Pathology Department, Semnan University of Medical Sciences, Semnan, Iran.

Corresponding author and reprints: Hakimeh Sadeghian MD, Tehran Heart Center, North Kargar Street, Tehran, Iran. Tel: +98-218-802-9257, Fax: +98-218-802-9256, Email: sadeghianhakimeh@yahoo.com
Accepted for publication: 20 June 2012

cal subcomponent scores which could influence the PTMC result. Thus in the current study we aim to identify the likely role of demographic data, clinical characteristics, echocardiographic and mitral valve morphological parameters in influencing the successful result of PTMC in our clinical setting and to provide equations for estimating the probability of a successful PTMC result, based on patient characteristics and pre-procedure echocardiographic assessment.

Material and Methods

Study population

From July 2002 to November 2009, we retrospectively reviewed the records of 199 patients who underwent PTMC. Included were 196 patients who had available data on pre- and post-PTMC echocardiographic assessments. There were 48 (24.5%) male and 148 (75.5%) female patients; the mean age was 42.7 ± 11.5 years (range: 15–79 years). Patients' demographic data and clinical characteristics are summarized in Table 1. In our institution, PTMC is the procedure of choice for treatment of all symptomatic or asymptomatic patients (with a pulmonary systolic pressure greater than 50 mmHg at rest or 60 mmHg with exercise) who have moderate to severe MS.²² Presence of each of the following factor was considered as exclusion criterion: left atrial thrombus, significant coexistent valve lesions, MR severity greater than grade 2+ or unfavorable mitral valve morphology with Wilkins total score > 12. Patients with exclusion criteria were referred for surgical treatment. Informed consent was obtained from all patients. Table 1 shows mitral valve morphological measurements and pre-PTMC echocardiographic measurements for all patients.

Cardiac catheterization and percutaneous transvenous mitral commissurotomy (PTMC)

A self-positioning single balloon (Inoue balloon) was applied for commissurotomy in all patients. The upper limit of the balloon diameter was chosen according to the patient's height. Inflation was commenced at less than the predetermined upper-limit diameter. Multiple, stepwise graded ballooning was performed using increments of 1–2 mm until the reduction in the transmitral gradient was satisfactory. If optimal hemodynamic results were not achieved at the maximum diameter of the balloon, additional inflation was not attempted.

Echocardiographic evaluation

Echocardiographic assessment was conducted for all patients during the week leading up to the procedure using a combination of transthoracic two-dimensional (2D) pulsed and continuous-wave Doppler with color-flow imaging (Vingmed GE, Horten, Norway, 3.5 MHz transducer) and transesophageal echocardiography (Vivid-7, Vingmed GE, Horten, Norway, 5 MHz transducer). All patients were reassessed between 24 hours and 6 weeks after PTMC via transthoracic echocardiography.

The following echocardiographic measurements were assessed before and after PTMC based on the American Society of Echocardiography (ASE) guidelines and standards^{23,24}: MVA as determined by the Doppler pressure half-time (PHT) method, left ventricle ejection fraction (LVEF) as measured by the modified biplane Simpson method, mitral valve peak gradient (MVPG), mitral valve mean gradient (MVMG), systolic and diastolic left ventricle dimension (sLVD and dLVD), left atrium (LA) size,

and pulmonary artery systolic pressure (PAPs). MR severity was assessed by echocardiography and scored 0 as no or trivial, 1 as mild, 2 as moderate, 3 as moderate to severe, and 4 as severe MR.²⁵ An ultrasound evaluation of the structural features of the mitral valve and subvalvular apparatus was performed for each patient before the procedure. The anterior and posterior leaflets were scored individually according to (a) leaflet thickening, (b) leaflet mobility, (c) leaflet calcification, and (d) subvalvular thickness. Each component was assigned a score of 0–4 in accordance with the Wilkins echocardiographic scoring system and summing the individual scores generally resulted in a total echocardiographic score for the mitral valve that varied from 0 to 16,¹³ with higher values representing greater morphological abnormality. Finally, the overall score of the mitral valve morphological subcomponents was obtained by calculating the arithmetic mean of the severity grades of the anterior and posterior leaflets. With regard to our data, the subcomponent scores ranged from 0 to 3 for leaflet thickening or leaflet calcification, and from 0 to 4 for leaflet mobility or subvalvular thickness. The final total echocardiographic scores ranged from 3 to 12.

According to previously established criteria, a successful PTMC result was defined as a post-procedure MVA ≥ 1.5 cm² with MR grade ≤ 2 .^{3–5} To determine the predictors of PTMC success, we categorized patients into two groups according to the overall PTMC result: i) successful (final MVA ≥ 1.5 cm² without post-procedure MR grade > 2) and ii) unsuccessful (final MVA < 1.5 cm² or post-procedure MR grade > 2). All patients' characteristics and echocardiographic measurements were compared between groups to identify any predictive parameters that might have influenced the PTMC results.

Statistical analysis

The data are presented as mean \pm SD for numerical variables and summarized by absolute frequencies and percentages for the categorical variables. Student's paired *t*-test or Wilcoxon's signed ranks test was employed to compare the measurements before and after mitral valve commissurotomy. Univariate analysis of the baseline demographic data, clinical characteristics, and echocardiographic measurements was performed within individual groups applying the student's *t*-test Mann-Whitney's U test, Chi-square, or Fisher's exact test, as appropriate (Table 1). Multiple logistic regression analysis was implemented to identify the predictors of a successful result. The variables of age, gender, pre-procedure MVA, LVEF, MVMG, dLVD, LA size, PAPs along with morphological scores of the mitral valve subcomponents (thickening, calcification, mobility, and subvalvular thickening) were entered into the logistic model.

To examine the two-way interaction effects between the variables, age was stratified into two groups of ≥ 40 and < 40 years and initial MVA was divided into MVA ≥ 1.0 cm² and < 1.0 cm². All two-way interaction terms between any of these newly categorized variables and other variables were systematically introduced into the logistic model to assess for significant effects. The associations of the independent predictors with successful result in the final model were expressed as odds ratios (OR) with 95% confidence intervals (CIs). Model discrimination was measured using the statistic, which is equal to the area under the receiver operating characteristic (ROC) curve. Model calibration was estimated using the Hosmer-Lemeshow goodness-of-fit statistic (higher *P* values imply that the model is a better fit with the observed data).

Table 1. Comparison of patients' characteristics and echocardiographic measurements between groups according to PTMC results.

Patients' characteristics	Total (n = 196)	PTMC results		P-value
		Unsuccessful (n = 57)	Successful (n = 139)	
Age (years)	42.7 ± 11.5	46.0 ± 10.7	41.3 ± 11.5	0.009
Male gender	48 (24.5)	12 (21.1)	36 (25.9)	0.584
Diabetes mellitus	6 (3.1)	2 (3.6)	3 (2.2)	0.633
Chronic obstructive pulmonary disease	1 (0.5)	0	1 (0.7)	0.705
Hypertension	11 (5.7)	4 (7.1)	7 (5.2)	0.415
Cigarette smoking	20 (10.4)	4 (7.1)	16 (11.9)	0.240
Cerebrovascular accident	3 (1.6)	0	3 (2.2)	0.348
Transient ischemic attacks	1 (0.5)	1 (1.8)	0	0.295
History of previous PTMC	9 (4.7)	3 (5.6)	6 (4.4)	0.496
History of open mitral valve commissurotomy	2 (1)	1 (1.9)	1 (0.7)	0.483
Echocardiographic measurements				
Mitral valve area (MVA; cm ²)	1.0 ± 0.2	1.0 ± 0.2	1.0 ± 0.2	0.120
Mitral regurgitation (MR) grade	0.5 ± 0.6	0.6 ± 0.6	0.5 ± 0.6	
Left ventricle ejection fraction (LVEF; %)	55.3 ± 6.2	55.1 ± 7.1	55.3 ± 5.9	0.798
Mitral valve peak gradient (MVPG; mmHg)	20.2 ± 8.1	19.8 ± 7.2	20.3 ± 8.4	0.722
Mitral valve mean gradient (MVMG; mmHg)	11.7 ± 5.4	11.4 ± 5.2	11.8 ± 5.5	0.709
Systolic left ventricle dimension (sLVD; mm)	30.9 ± 6.1	31.3 ± 7.2	30.6 ± 5.7	0.534
Diastolic left ventricle dimension (dLVD; mm)	44.9 ± 5.7	45.8 ± 6.9	44.6 ± 5.1	0.276
Left atrium size (LAs; mm)	46.6 ± 9.5	50.5 ± 12.8	45.1 ± 7.5	0.008
Pulmonary artery systolic pressure (PAPs; mmHg)	47.1 ± 15.0	48.3 ± 13.6	46.6 ± 15.5	0.196
Mitral valve morphological scores				
Total score	7.7 ± 1.5	8.0 ± 1.5	7.6 ± 1.5	0.131
Thickness	2.0 ± 0.4	2.2 ± 0.4	2.0 ± 0.4	0.003
Calcification	1.4 ± 0.6	1.6 ± 0.7	1.4 ± 0.6	0.078
Mobility	2.1 ± 0.4	2.1 ± 0.5	2.1 ± 0.4	0.692
Subvalvular thickness	2.0 ± 0.7	2.1 ± 0.6	2.2 ± 0.7	0.784

Data are presented as mean ± SD and n (%).

Intra- and inter-observer variability was analyzed in ten randomly selected subjects and expressed as the mean percentage error (difference/mean) for the numerical variables and the Cohen Kappa coefficient for the categorical variables.

For the statistical analysis, the statistical package SAS version 9.1 for Windows (SAS Institute Inc., Cary, NC, USA) was used. All *P*-values were 2-tailed, with statistical significance defined by a *P* value ≤ 0.05.

Results

Amongst 196 patients included in our study, there were no deaths or any complications, with the exception of worsening MR that was associated with PTMC. The mean MVA increased significantly from 1.0 ± 0.2 cm² (range: 0.4–1.4) to 1.7 ± 0.4 cm² (*P* < 0.001). Echocardiographic evaluation showed a significant decrease in PAPs from 49.9 ± 13.9 to 38.9 ± 12.6 mmHg, MVMG from 11.5 ± 5.2 to 5.2 ± 3.3 mmHg, and MVPG from 19.5 ± 7.5 to 10.0 ± 4.0 mmHg following PTMC (*P* < 0.001 for all; Figure 1).

A successful PTMC result was obtained in 139 (70.9%) patients opposed to 57 (29.1%) who had unsuccessful results that were due to suboptimal secondary MVA < 1.5 cm² in 50 (25.5%) patients and post-procedure MR grade > 2 in 7 (3.6%). Amongst all patients, the MR severity worsened in 53 (28.2%) patients by one grade in 34 (18.6%), two grades in 12 (6.4%), three grades in 3 (1.6%), and four grades in 3 (1.6%) patients while it remained the same in 108 (57.4) or decreased by one grade in 27 (14.4%) patients after PTMC. Severe MR occurred in 4 (2.0%) patients following PTMC.

Inter- and intraobserver variability

The echocardiographic parameters measured by the same observer were replicable for the mitral valve morphological total score (7.5%), mitral valve morphological subcomponents (Kappa

range: 0.58–0.68, approximate significance < 0.01), MR severity (Kappa: 0.72, approximate significance < 0.01) and MVA (11.9%). The measurements taken by the two observers were reproducible for total mitral valve morphological score (11.1%), mitral valve morphological subcomponent scores (Kappa range: 0.48–0.62, approximate significance < 0.01), MR severity (Kappa: 0.67, approximate significance < 0.01) and MVA (6.8%).

The effect of patients' characteristics and echocardiographic measurements

Table 1 shows that patients who had successful PTMC results were significantly younger than those with unsuccessful results (*P* = 0.009). No difference was found in the sex distribution between the groups with respect to the PTMC result (*P* = 0.584). Likewise, comparisons of the incidence of comorbidities or any previous commissurotomy between the groups did not show any significant difference in terms of PTMC result. Evaluation of pre-PTMC echocardiographic measurements showed that the pre-procedure mean LA size was significantly lower in patients who had successful PTMC results than those with unsuccessful results (*P* = 0.008). Mitral valve morphological total score was not significantly different between the patients with and without successful results while comparison of morphological subcomponents revealed that the degree of mitral valve thickness was significant and mitral valve calcification tended to be lower in patients whose results were successful (*P* = 0.003) compared to those with unsuccessful results (*P* = 0.078).

Predictive factors for successful result after PTMC

The demographic variables, pre-procedure echocardiographic measurements, and mitral valve morphological subcomponent scores were included in the model to determine whether they were independent predictive factors for a successful result. The analysis identified that age (*P* = 0.0021), LA size (*P* = 0.0235), and valve

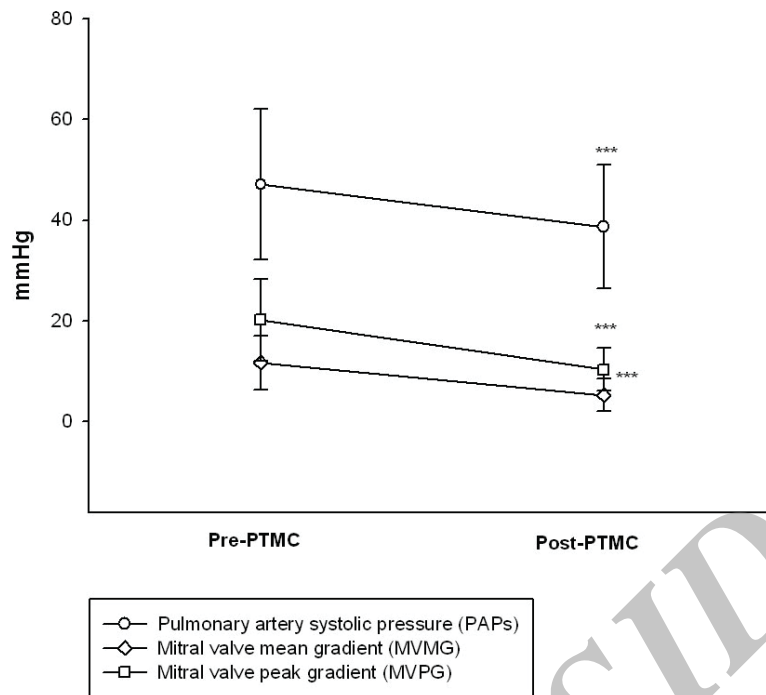


Figure 1. Plot of changes in hemodynamic parameters before and after percutaneous transvenous mitral commissurotomy (PTMC). All values are mean ± SD. ****P* < 0.001 when compared to pre-procedure measurements.

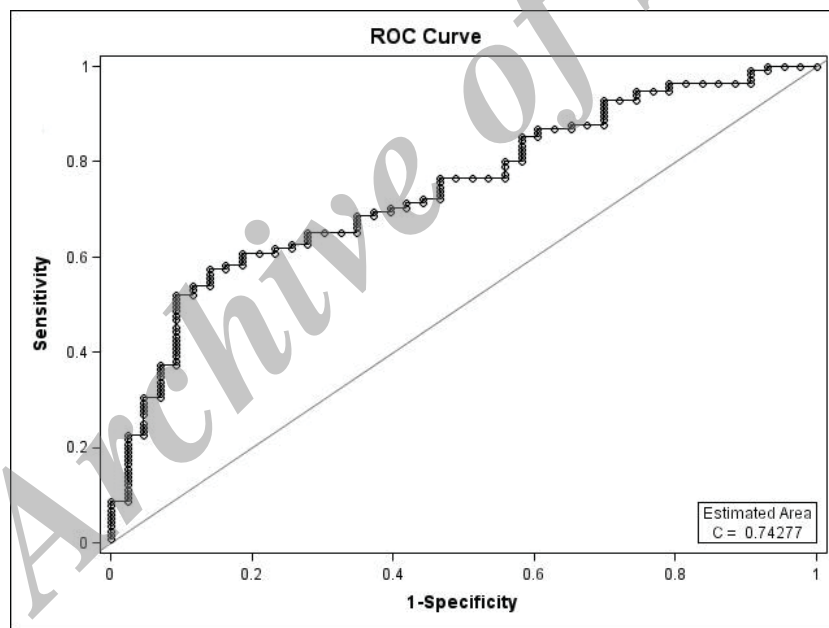


Figure 2. The ROC curve derived from factors affecting successful PTMC results.

thickness (*P* = 0.0184) were significant predictors for a successful PTMC result. The strength of the predictive factors is indicated by the adjusted OR in Table 2. The probability (*P*) of a successful MVA increase in these patients could be predicted via the equation below:

$$P_{(\text{Successful outcome})} = \frac{e^{7.2857 - 0.0576 (\text{Age}) - 0.0500 (\text{LA size}) - 1.1473 (\text{Valve thickness})}}{1 + e^{7.2857 - 0.0576 (\text{Age}) - 0.0500 (\text{LA size}) - 1.1473 (\text{Valve thickness})}}$$

The good fit of the model was shown by the absence of a significant difference between the predicted (using the model) and observed results (Hosmer-Lemeshow goodness-of-fit test, *P* = 0.45). The area under the ROC curve was 0.74 (Figure 2). No

interaction effects were detected in the prediction of a successful PTMC result.

Discussion

This study showed that pre-PTMC echocardiographic evaluation may be helpful for prediction of immediate outcome of the procedure. This study revealed that successful result of PTMC was influenced by patients' age, LA size, and mitral valve thickness. Based on our findings, younger age could be regarded as an independent predictor for a successful result. In line with our results, previous studies have identified young age as a signifi-

Table 2. Factors predictive of a successful percutaneous transvenous mitral commissurotomy (PTMC) result.

	Odds ratio (OR)	95% Confidence interval (CI)	P-value
Age	0.944	0.910-0.979	0.0021
Pre-procedure LA size	0.951	0.911-0.993	0.0235
Mitral valve thickness	0.317	0.122-0.824	0.0184

cant predictor of a successful immediate result.^{3,4,17} In regard to echocardiographic measurements, initial size of LA appears to be an independent predictor of the PTMC result. Wilkins et al., in a study of 22 patients, have reported no difference in the LA volume in patients with optimal or suboptimal outcomes.¹³ However, in a study of 1,024 patients by Iung et al., primary LA diameter was linked to immediate results but this variable was not selected as a significant predictor of the outcome after applying a secondary logistic model.⁴ Similar to previous studies, no other hemodynamic variables such as primary size of mitral valve, LVEF, MVMG, sLVD, dLVD and PAP have emerged as predictors of result.^{3,5,7,13,21}

Based on our findings, mitral valve thickness and leaflet calcification were significantly associated with a successful result after PTMC, whereas the total score and subcomponents of mobility and subvalvular thickness might not influence the PTMC result. There have been conflicting reports about the predictive role of morphological scores in MVA increase after PTMC. For all the studies that have confirmed a significant influence of the total morphological score or morphological classification of the mitral valve on the increase in the valve area after valvotomy^{1,2,4,8,13,14,16,21,26,27} there are reports that reject any correlation between the total echocardiographic and immediate result of the procedure.^{17,26} In regard to the subcomponents of Wilkins echocardiographic score, the existing literature abounds with controversies. Some investigators have identified valvular thickening⁶ and valvular calcification^{18,28,29} as independent predictors of MVA increase, whereas others have found no significant correlation between leaflet thickness,^{15,20} valvular calcification,^{2,20} and the immediate result of valvuloplasty. Comparisons with other studies are limited because various criteria are applied by investigators for patient inclusion, in addition to the definition of a successful procedure and morphological evaluation of mitral valve. Using different balloon techniques such as the single, double or Inoue balloon also possibly influence the result. In this study, we have shown that the maximum mitral valve deformity grade was 3 according to leaflet thickness or calcification and 4 according to leaflet mobility or subvalvular thickness. These findings suggest a more important predictive role for mitral valve thickness and calcification on a successful PTMC result.

In the current study, we used the PHT method since the post-procedure MVA was not measured by planimetry in some patients. Despite limitations in using the PHT method immediately post-PTMC,³⁰ reports have asserted that PHT and planimetry are usually similar in MVA measurements post-PTMC whenever both methods are feasible.^{31,32} Using 3-D echocardiography in future studies may provide more accurate parameters for the prediction of the PTMC result since this method provides a unique en face view and morphologic analysis of the entire mitral valve apparatus²⁹ and it is superior for the evaluation of leaflet mobility and commissures.³³

The echocardiographic examination aids clinicians to predict overall PTMC success. Successful PTMC results are influenced by patients' age, LA size, and mitral valve thickness.

Conflict of interest

The authors declared that they have no conflict of interest.

References

1. Participants NV. Multicenter experience with balloon mitral commissurotomy: NHLBI Balloon Valvuloplasty Registry report on immediate and 30-day follow-up results. *Circulation*. 1992; **85**: 448 – 461.
2. Arora R, Kalra GS, Singh S, Mukhopadhyay S, Kumar A, Mohan JC, et al. Percutaneous transvenous mitral commissurotomy: immediate and long-term follow-up results. *Cathet Cardiovasc Diagn*. 2002; **55**: 450 – 456.
3. Vahanian A. Percutaneous mitral commissurotomy. *Eur Heart J*. 1996; **17**: 1465.
4. Iung B, Cormier B, Ducimetiere P, Porte JM, Nallet O, Michel PL, et al. Immediate results of percutaneous mitral commissurotomy: a predictive model on a series of 1514 patients. *Circulation*. 1996; **94**: 2124 – 2130.
5. Iung B, Garbarz E, Michaud P, Helou S, Farah B, Berdah P, et al. Late results of percutaneous mitral commissurotomy in a series of 1024 patients: analysis of late clinical deterioration: frequency, anatomic findings, and predictive factors. *Circulation*. 1999; **99**: 3272 – 3278.
6. Abascal VM, Wilkins GT, O'Shea JP, Choong CY, Palacios IF, Thomas JD, et al. Prediction of successful outcome in 130 patients undergoing percutaneous balloon mitral valvotomy. *Circulation*. 1990; **82**: 448 – 456.
7. Reid CL, McKay CR, Chandraratna PA, Kawanishi DT, Rahimtoola SH. Mechanisms of increase in mitral valve area and influence of anatomic features in double-balloon, catheter balloon valvuloplasty in adults with rheumatic mitral stenosis: a Doppler and two-dimensional echocardiographic study. *Circulation*. 1987; **76**: 628 – 636.
8. Nobuyoshi M, Hamasaki N, Kimura T, Nosaka H, Yokoi H, Yasumoto H, et al. Indications, complications, and short-term clinical outcome of percutaneous transvenous mitral commissurotomy. *Circulation*. 1989; **80**: 782 – 792.
9. Essop MR, Wisenbaugh T, Skoularigis J, Middlemost S, Sareli P. Mitral regurgitation following mitral balloon valvotomy. Differing mechanisms for severe versus mild-to-moderate lesions. *Circulation*. 1991; **84**: 1669 – 1679.
10. Harrison JK, Wilson JS, Hearne SE, Bashore TM. Complications related to percutaneous transvenous mitral commissurotomy. *Cathet Cardiovasc Diagn*. 1994; **Suppl 2**: 52 – 60.
11. Krishnamoorthy KM, Radhakrishnan S, Shrivastava S. Natural history and predictors of moderate mitral regurgitation following balloon mitral valvuloplasty using Inoue balloon. *Int J Cardiol*. 2003; **87**: 31 – 36.
12. Hernandez R, Macaya C, Bañuelos C, Alfonso F, Goicolea J, Iiguez A, et al. Predictors, mechanisms, and outcome of severe mitral regurgitation complicating percutaneous mitral valvotomy with the Inoue balloon. *Am J Cardiol*. 1992; **70**: 1169 – 1174.
13. Wilkins GT, Weyman AE, Abascal VM, Block PC, Palacios IF. Percutaneous balloon dilatation of the mitral valve: an analysis of echocardiographic variables related to outcome and the mechanism of dilatation. *Br Med J*. 1988; **60**: 299 – 308.
14. Tuzcu EM, Block PC, Griffin BP, Newell JB, Palacios IF. Immediate and long-term outcome of percutaneous mitral valvotomy in patients 65 years and older. *Circulation*. 1992; **85**: 963 – 971.
15. Come PC, Riley MF, Diver DJ, Morgan JP, Safian RD, McKay RG. Noninvasive assessment of mitral stenosis before and after percutaneous balloon mitral valvuloplasty. *Am J Cardiol*. 1988; **61**: 817 – 825.
16. Sutaria N, Shaw TRD, Prendergast B, Northridge D. Transoesophageal echocardiographic assessment of mitral valve commissural morphology predicts outcome after balloon mitral valvotomy. *Br Med J*. 2006; **92**: 52 – 57.
17. Herrmann HC, Ramaswamy K, Isner JM, Feldman TE, Carroll JD,

- Pichard AD, et al. Factors influencing immediate results, complications, and short-term follow-up status after Inoue balloon mitral valvotomy: a North American multicenter study. *Am Heart J.* 1992; **124**: 160 – 166.
18. Tuzcu EM, Block PC, Griffin B, Dinsmore R, Newell JB, Palacios IF. Percutaneous mitral balloon valvotomy in patients with calcific mitral stenosis: immediate and long-term outcome. *J Am Coll Cardiol.* 1994; **23**: 1604 – 1609.
 19. Feldman T, Carroll JD, Isner JM, Chisholm RJ, Holmes DR, Massumi A, et al. Effect of valve deformity on results and mitral regurgitation after Inoue balloon commissurotomy. *Circulation.* 1992; **85**: 180 – 187.
 20. Goswami KC, Bahl VK, Talwar KK, Shrivastava S, Manchanda SC. Percutaneous balloon mitral valvuloplasty using the Inoue balloon: analysis of echocardiographic and other variables related to immediate outcome. *Int J Cardiol.* 1999; **68**: 261 – 268.
 21. Palacios IF, Sanchez PL, Harrell LC, Weyman AE, Block PC. Which patients benefit from percutaneous mitral balloon valvuloplasty? Prevalvuloplasty and postvalvuloplasty variables that predict long-term outcome. *Circulation.* 2002; **105**: 1465 – 1471.
 22. Libby P, Bonow R, Mann DL, Zipes D. *Braunwald's Heart Disease.* Philadelphia: Saunders elsevier; 2008.
 23. Baumgartner H, Hung J, Bermejo J, Chambers JB, Evangelista A, Griffin BP, et al. Echocardiographic assessment of valve stenosis: EAE/ASE recommendations for clinical practice. *J Am Soc Echocardiogr.* 2009; **22**: 1 – 23.
 24. Jang IK, Block PC, Newell JB, Tuzcu EM, Palacios IF. Percutaneous mitral balloon valvotomy for recurrent mitral stenosis after surgical commissurotomy. *Am J Cardiol.* 1995; **75**: 601 – 605.
 25. Feigenbaum H, Armstrong WF, Ryan T. *Feigenbaum's Echocardiography.* Philadelphia: Lippincott WILLIAMS and WILKINS; 2005.
 26. Fatkin D, Roy P, Morgan JJ, Feneley MP. Percutaneous balloon mitral valvotomy with the Inoue single-balloon catheter: commissural morphology as a determinant of outcome. *J Am Coll Cardiol.* 1993; **21**: 390 – 397.
 27. Ahmad A, Imran SH, Abid AR, Mallick NH. Percutaneous transvenous mitral commissurotomy. *Professional Med J.* 2007; **14**: 602 – 609.
 28. Sutaria N, Northridge DB, Shaw TRD. Significance of commissural calcification on outcome of mitral balloon valvotomy. *Br Med J.* 2000; **84**: 398 – 402.
 29. Anwar AM, Attia WM, Nosir YFM, Soliman OII, Mosad MA, Othman M, et al. Validation of a New Score for the Assessment of Mitral Stenosis Using Real-Time Three-Dimensional Echocardiography. *J Am Soc Echocardiogr.* 2010; **23**: 13 – 22.
 30. Thomas JD, Wilkins GT, Choong CY, Abascal VM, Palacios IF, Block PC, et al. Inaccuracy of mitral pressure half-time immediately after percutaneous mitral valvotomy. Dependence on transmitral gradient and left atrial and ventricular compliance. *Circulation.* 1988; **78**: 980 – 993.
 31. Otto CM, Davis KB, Holmes DR. Methodologic issues in clinical evaluation of stenosis severity in adults undergoing aortic or mitral balloon valvuloplasty. *Am J Cardiol.* 1992; **69**: 1607 – 1616.
 32. Manga P, Singh S, Brandis S, Friedman B. Mitral valve area calculations immediately after percutaneous balloon mitral valvuloplasty: effect of the atrial septal defect. *J Am Coll Cardiol.* 1993; **21**: 1568 – 1573.
 33. Salustri A, Becker AE, van Herwerden L, Vletter WB, Ten Cate FJ, Roelandt J. Three-dimensional echocardiography of normal and pathologic mitral valve: a comparison with two-dimensional transesophageal echocardiography. *J Am Coll Cardiol.* 1996; **27**: 1502 – 1510.

Archive of SID