

Case Report

Pseudoaneurysm of the Brachial Artery in a Four-Month-Old Boy: Diagnosis and Treatment

Mirko Žganjer MSc PhD¹, Vlasta Žganjer MD², Irenej Cigit MD¹, Ante Čizmić MD¹

Abstract

Pseudoaneurysms arise from a disruption in the arterial wall and blood dissecting into the tissues around the damaged artery creating a perfused sac that communicates with the arterial lumen. Trauma to the wall of the artery may lead to the development of a pseudoaneurysm. Post-traumatic pseudoaneurysm development is very rare in the peripheral artery and often is a consequence of venipuncture.

We have reported the case of the four-month-old boy who developed a pseudoaneurysm following an accidental arterial puncture. In the antecubital area we noticed a pulsative mass and palpable thrill. The patient underwent a Doppler ultrasound examination and CT with contrast. Surgery was indicated. Following excision of the pseudoaneurysm, an end-to-end anastomosis was performed. Follow-up for four years revealed palpable peripheral pulsation at the wrist level. In the postoperative period, all ultrasound findings were normal.

End-to-end anastomosis is preferable if it can be performed without tension or damage to the major collateral vessels.

Keywords: Brachial artery injury, children, pseudoaneurysms

Cite the article as: Žganjer M, Žganjer V, Cigit I, Čizmić A. Pseudoaneurysm of the Brachial Artery in a Four-Month-Old Boy: Diagnosis and Treatment. *Arch Iran Med.* 2012; **15(10)**: 650 – 651.

Introduction

A pseudoaneurysm, called also a false aneurysm, is a leakage of arterial blood from an artery into the surrounding tissue with a connection between the artery and the resultant adjacent cavity. Also, a pseudoaneurysm is defined as an aneurysmal sac surrounded by fibrous tissue instead of other vascular layers such as the muscular layer.^{1,2} The most common etiology in children defined as an arterial complication is peripheral arterial puncture following venipuncture.³⁻⁵ Symptoms depend on the location and size of the pseudoaneurysms. Peripheral artery pseudoaneurysms in the brachial artery, particularly located near the elbow pit may cause thromboembolic complications in the hand and fingers. When a pseudoaneurysm has been diagnosed, surgical repair is indicated immediately because of possible complications of ischemia, hemorrhage, neurologic symptoms, nerve compression, venous edema or deep vein thrombosis, and cutaneous erosions.⁶⁻⁸

Case report

A four-month-old boy was admitted to a clinic for surgery due to the presence of swelling in the right elbow pit (Figure 1). His medical history was remarkable for an eight-day stay in the intensive care unit for prolonged neonatal jaundice. After three weeks the parents noticed swelling in his right elbow pit, for which they visited the pediatrician who suggested observation, because he was not sure what it's doing. After two months of observation, the infant was referred to a pediatric surgeon. The mass was a pulsative mass that had a palpable thrill at the brachial artery level which had developed in the post-traumatic period.

Authors' affiliations: ¹Department of Pediatric Surgery, Clinical Hospital, Zagreb, Klaićeva 16, Croatia. ²Pfizer d.o.o., Zagreb, Radnička Cesta 80, Croatia.

Corresponding author and reprints: Mirko Žganjer MSc PhD, Clinical Hospital Zagreb, Klaićeva 16, 10000 Zagreb, Croatia.

Tel: +3851 46 00 227, Fax: +385 1 46 00 169, E-mail: mirko.ganjer@gmail.com
Accepted for publication: 4 April 2012

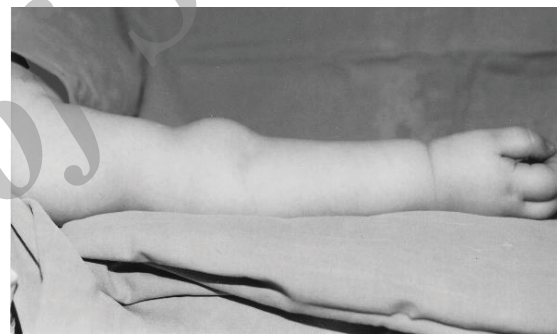

Figure 1. Photo of the pseudoaneurysm.

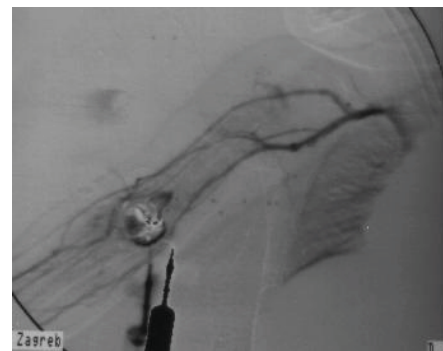


Figure 2. CT angiography with contrast.

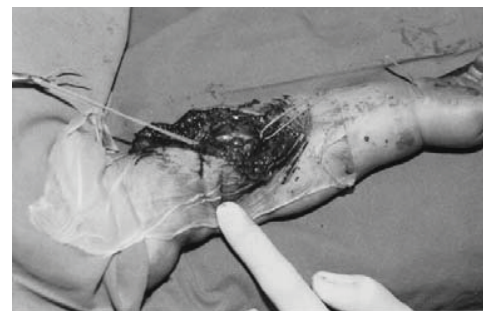


Figure 3. Pseudoaneurysm - detail from operative treatment.

To diagnose the pseudoaneurysm we performed Doppler ultrasound. Ultrasound results were remarkable for a 19 mm swollen area that had a thick, irregular wall. In the interior of the formation there was turbulent flow with an arterial signal. On the ventral side of the formation, the ultrasound showed the brachialis artery, which communicated with the pseudoaneurysm. After ultrasound diagnosis the patient underwent a CT scan with IV contrast (Figure 2), which showed the presence of an 18 mm diameter formation in the elbow, which was connected with the brachialis artery. Clinical examination and radiological diagnosis confirmed the presence of a brachialis artery pseudoaneurysm, which was located on the brachial artery where it crosses to the cubital artery. Incision above the pseudoaneurysm appears brachial artery with pseudoaneurysm which measuring about 2 centimeters with a strong fibrous wall (Figure 3). We did not locate the clot in the lumen of the pseudoaneurysm. Treatment included surgical excision of the pseudoaneurysm under general anesthesia and an end-to-end anastomosis of the brachial artery with Prolene 7.0 was performed. We did not administer IV heparin prior to clamping the artery. The radial and ulnar pulses were palpable following arterial repair and removal of the arterial clamps. At the completion of surgery, anastomotic patency was neat. Postoperative recovery was without complications and the patient was discharged from the hospital in good condition.

Follow-up period for four years revealed palpable peripheral pulsation at the wrist level. Ultrasound findings were normal in the follow up period.

Discussion

Pseudoaneurysms are uncommon in adults and even less common in children. Blunt trauma, penetrating trauma and attempts at vascular access are the most common etiologic factors. They are very rare in children under the age of one, particularly those located in the brachial artery.^{9,10} Clinical outcome depends on rapid diagnosis and repair of the injury. To diagnose arterial lesions such as pseudoaneurysms, color Doppler ultrasonography or CT angiography should be performed. Using ultrasonography with Doppler evaluation for diagnosis in the emergency setting has been excellent but not widely used because its sensitivity is lower than arteriography. CT angiography is a noninvasive, rapid imaging technique that shows high sensitivity and specificity in the detection of arterial injuries located in the extremities. CT angiographic signs of arterial injury include active extravasation of contrast material, pseudoaneurysm formation, abrupt narrowing of an artery, loss of opacification of an arterial segment, and arteriovenous fistula formation. Studies have shown the sensitivity of CT angiography to be 90%–95.1% and its specificity 98.7%–100% for detecting arterial injury to the extremities after trauma.

There are various approaches to treat pseudoaneurysms, but in children we have recommended two surgical methods: i) resection of the pseudoaneurysm and involved part of the artery with restoration of arterial continuity by an end-to-end anastomosis and

ii) reconstruction using a venous interposition graft. Primary arterial repair and end-to-end anastomosis is the recommended technique. End-to-end anastomosis is preferable if it can be performed without tension or damage to the major collateral vessels. Early diagnosis before complications and microvascular reconstruction are most important in managing these injuries. Exposure of the brachial artery is approached with a median incision. The median nerve is always identified and separated from the brachial artery.

In our patient we did not notice any local effects of a pseudoaneurysm such as ischemia, neurologic symptoms, nerve compression, or deep vein thrombosis.

We recommend early diagnosis and surgery to prevent complications. Immediate repair is advocated in this injury to ensure adequate growth of the limb. Doppler ultrasonography is an excellent and sensitive method to confirm the presence of a vascular injury. If there are doubts after clinical examination and ultrasound regarding vascular status, CT angiography should be performed to confirm vascular injury.^{11–15}

References

1. Ergunes K, Yilic L, Ozsoyler I, Kestelli M, Ozbek C, Gurbuz A. Traumatic brachial artery injuries. *Tex Heart Inst J*. 2006; **33**: 31 – 34.
2. Shah SR, Wearden PD, Gaines BA. Pediatric peripheral vascular injuries: a review of our experience. *J Surg Res*. 2009; **153**: 162 – 166.
3. Dzepina I, Unusic J, Mijatovic D, Bulic K. Pseudoaneurysms of the brachial artery following venipuncture in infants. *Pediatr Surg Int*. 2004; **20**: 594 – 597.
4. Dogan OF, Demirchin M, Ucar I, Duman U, Yilmaz M, Boke E. Iatrogenic brachial and femoral artery complications following venipuncture in children. *Heart Surg Forum*. 2006; **9**: 675 – 680.
5. Yilmaz M, Dogan OF, Tok M, Hazirolan T, Guvener M, et al. Pseudoaneurysm of the brachial artery in two infants following accidental arterial puncture. *Vasa*. 2005; **34**: 198 – 200.
6. Yetkin U, Gurbuz A. Post-traumatic pseudoaneurysm of the brachial artery and its surgical treatment. *Tex Heart Inst J*. 2003; **30**: 293 – 297.
7. Ekim H, Tuncer M. Management of traumatic brachial artery injuries: a report on 49 patients. *Ann Saudi Med*. 2009; **29**: 105 – 109.
8. Zellweger R, Hess F, Nicol A, Omoshoro-Jones J, Kahn D, Navsaria P. An analysis of 124 surgically managed brachial artery injuries. *Am J Surg*. 2004; **188**: 240 – 245.
9. Franz RW, Goodwin RB, Hartman JF, Wright ML. Management of upper extremity arterial injuries at an urban level I trauma center. *Ann Vasc Surg*. 2009; **23**: 8 – 16.
10. Gow KW, Mykytenko J, Patrick EL, Dodson TF. Brachial artery pseudoaneurysm in a 6-week-old infant. *Am Surg*. 2004; **70**: 518 – 521.
11. Miller-Thomas MM, West OC, Cohen AM. Diagnosing traumatic arterial injury in the extremities with CT angiography: pearls and pitfalls. *Radiographics*. 2005; **25(suppl 1)**: S133 – S142.
12. Mommsen P, Zeckey C, Hildebrand F, Frink M, Khaladj N, Lange N, et al. Traumatic extremity arterial injury in children: epidemiology, diagnostics, treatment, and prognostic value of Mangled Extremity Severity Score. *J Orthop Surg Res*. 2010; **5**: 25.
13. Allan P, Dulkins PA, McDicken WN, Pozniak M. *Clinical Doppler Ultrasound*. First ed. USA: Elsevier Limited; 2006: 73 – 99.
14. Arger PH, DeBari Iyooob S. *The Complete Guide to Vascular Ultrasound*. USA: Lippincott, Williams and Wilkins; 2004: 26 – 40.
15. Pelchivitz DJ, Cahill AM, Baskin KM, Kaye RD, Towbin RB. Pseudoaneurysm in children: diagnosis and interventional management. *Pediatr Radiol*. 2005; **35**: 434 – 439.