

# Cystic Lesions of the Pancreas

Mehdi Mohamadnejad MD<sup>1</sup>, Mohamad A. Eloubeidi MD<sup>2</sup>

## Abstract

Pancreatic cysts (PCs) are being increasingly detected due to the widespread use of high-resolution abdominal imaging. The main imaging modalities to diagnose PCs include high-resolution spiral CT scan, MRI, and endoscopic ultrasound (EUS). EUS has the added benefit of enabling cyst fluid sampling through FNA and significantly improves clinical diagnosis of PCs. Some PCs like pseudocysts, serous cystadenomas, and lymphoepithelial cysts are entirely benign lesions and can be managed non-operatively. However, other lesions like mucinous cystic neoplasms, or cystic neuroendocrine tumors are pre-malignant or malignant lesions and require surgical intervention. In this review, we describe diagnosis and management of common pancreatic cystic lesions.

**Keywords:** Endoscopic ultrasound, neoplasm, pancreatitis, pancreas

**Cite the article as:** Mohamadnejad M, Eloubeidi MA. Cystic Lesions of the Pancreas. *Arch Iran Med.* 2013; **16(4)**: 233 – 239.

## Introduction

Pancreatic cysts (PCs) are being increasingly detected due to the widespread use of high-resolution abdominal imaging.

Pancreatic cyst is not a rare medical entity. About 2.6% of asymptomatic adults and more than 8% of those aged above 80 years have pancreatic cyst on multirow-detector CT scan.<sup>1,2</sup> The prevalence of PCs has been reported to be as high as 24% in autopsy series.<sup>3</sup>

Pancreatic cysts are widely variable in term of their malignant potential. Some of them are benign lesions and can be safely managed expectantly, and some others are pre-malignant or malignant lesions and generally require surgical resection at diagnosis or close follow up. On the other hand, surgical resection of PCs (particularly those located in the pancreatic head) is associated with significant morbidity.<sup>4</sup> Therefore, approaching a patient with pancreatic cyst poses significant challenge for the physicians.

Pancreatic cysts can be classified into pseudocyst and true cysts. Pancreatic pseudocysts are surrounded by fibrous and granulation tissue and are associated with acute or chronic pancreatitis.<sup>5</sup>

True pancreatic cysts are lined by epithelium and subdivided into non-neoplastic and neoplastic cysts.

While it had been reported in the earlier literature that 90% of the pancreatic cysts are pseudocysts,<sup>6</sup> however more recent series reported that more than half of the PCs are not pseudocyst.<sup>7-9</sup>

Pancreatic cystic neoplasms are classified by world health organization (WHO) into serous cystic tumors, mucinous cystic neoplasms (MCNs), intraductal papillary mucinous neoplasm (IPMN), and solid pseudopapillary neoplasms (SPNs).<sup>10</sup> Additionally, solid tumors of the pancreas (e.g., pancreatic neuroen-

doctrine tumors, pancreatic adenocarcinomas) may undergo cystic degeneration and present with a solid-cystic mass lesion.

In this review, we discuss current advances in the application of imaging modalities to diagnose pancreatic cystic lesions with special emphasize on endoscopic ultrasound (EUS), and EUS-guide fine needle aspiration (EUS-FNA). Then we discuss current diagnosis and management of the main pancreatic cystic lesions.

## Imaging Modalities to Diagnose Pancreatic Cysts

Accurate pre-operative diagnosis of pancreatic cysts precludes unnecessary surgical resection of many benign cystic lesions (e.g., pseudocyst, serous cystadenoma).

There have been significant progresses in the recent years in the pre-operative diagnosis of pancreatic cysts.

An interesting case series of 851 patients with PCs who underwent surgical resection at Massachusetts General Hospital showed that the trend for surgical resection of PCs has changed significantly over the past 33 years. For example, 27% of the resected PCs were serous cystadenoma in the time period of 1978 to 1989; however this proportion was decreased to 12% in the recent years.<sup>4</sup> This indicates improved diagnosis and hence decreased surgical resection rate for benign pancreatic cysts in the recent years. Also, the proportion of malignant neoplasms decreased over time (41% between 1978 and 1989; 12% between 2005 and 2011) indicating the earlier diagnosis of pre-malignant lesions.<sup>4</sup>

The main imaging modalities to diagnose PCs include high-resolution spiral CT scan, MRI, and EUS. The latter has the added benefit of enabling cyst fluid sampling through FNA. Few studies have compared the performance of different imaging modalities for detecting pancreatic cystic lesions.

In a recent study, high-risk asymptomatic individuals were screened for pancreatic lesions with CT scan, MRI, and EUS. In this study, EUS and MRI performed better than CT for detecting pancreatic lesions. IPMN was the most frequently detected lesion.<sup>11</sup>

Once a pancreatic cyst is detected, the physician needs to diagnose the cyst type or at least categorize the cyst as benign, pre-malignant or malignant to decide if surgical resection is required.<sup>12</sup>

**Authors' affiliations:** <sup>1</sup>Digestive Disease Research Center, Tehran University of Medical Sciences, Tehran, Iran. <sup>2</sup>Department of Medicine, Division of Gastroenterology, American University of Beirut, Beirut, Lebanon.

**Corresponding author and reprints:** Mohamad A. Eloubeidi MD, Division of Gastroenterology and Hepatology, American University of Beirut School of Medicine, PO Box 11-0236, Riad El Solh 110, 72020, Beirut, Lebanon. E-mail: me75@aub.edu.lb

Accepted for publication: 6 March 2013

The diagnostic accuracies of CT scan and MRI in pancreatic cysts are comparable.

The accuracy of multidetector CT scan (MDCT) and MRI for making the correct diagnosis in pancreatic cysts range from 40 to 60%<sup>13-15</sup>

MRI may perform better than MDCT for predicting ductal communication in pancreatic cysts and for differentiating IPMN from other lesions.<sup>16</sup>

Also, the identification of internal dependent debris by MRI may help to distinguish pseudocysts from neoplastic pancreatic cysts.<sup>17</sup>

Both MRI and MDCT perform better in classifying cysts as mucinous or non-mucinous than in determining a specific diagnosis. The accuracies of MRI and MDCT range from 70 to 85% in differentiating mucinous from non-mucinous cystic lesions.<sup>15,18</sup> Also, a good accuracy of 70 to 80% has been reported for MDCT and MRI for in differentiating benign from malignant lesions.<sup>19</sup> CT or MR features suggestive of malignancy include lesion size of more than 30 mm, main pancreatic duct dilation of more than 8 mm, common bile duct dilation, presence of mural nodule, presence of solid component, irregularly thickened wall of the cyst, and associated lymphadenopathy.<sup>15,20,21</sup>

EUS provides excellent imaging from the pancreatic cysts. However, EUS morphology alone has limited ability for differentiating mucinous from non-mucinous cystic lesion.<sup>22</sup> In another study, EUS morphology had the accuracy rate of 40 to 93% for the diagnosis of neoplastic vs. non-neoplastic cystic lesions. This study found no good interobserver agreement among experienced endosonographers for diagnosis of neoplastic vs. non-neoplastic lesions.<sup>23</sup>

In a study of 145 patients with pancreatic cyst, EUS more frequently identified multifocality of the pancreatic cystic lesions compared to CT scan or MRI. Also, malignancy was confirmed or suspected in 3 patients by EUS-guided FNA cytology, not suspected by CT or MRI.<sup>24</sup>

#### Cyst fluid analysis

The cyst fluid can be conveniently aspirated through EUS-guided FNA. There are numerous studies evaluating the value of cyst fluid analysis for diagnosing the type of pancreatic cyst. The cyst fluid can be evaluated for cytology, tumor markers (e.g., carcinoembryonic antigen, etc.), enzymes (e.g., amylase) and molecular markers.

Cytology may help for differentiating mucinous from non-mucinous cysts through identifying mucin producing cells. Also, cytology may diagnose malignant cystic lesions (e.g., cystadenocarcinoma) by demonstrating malignant cells or cells with high grade atypia (dysplasia) in the cyst fluid.<sup>25</sup>

Cytology of the cyst fluid provides high specificity but moderate to low sensitivity for differentiating mucinous from non-mucinous cysts or diagnosing malignant cystic lesion.

Brugge et al. reported the cyst fluid cytology has a sensitivity of 34.5% and specificity of 83% for distinguishing mucinous vs. non-mucinous cysts.<sup>22</sup> In this study, the sensitivity of cytology for diagnosing malignancy was 22%.<sup>22</sup> In a recent study, Genevay et al. retrospectively re-reviewed the cytology slides of 112 patients with histologically confirmed mucinous cysts of the pancreas. They found high grade atypia (dysplasia) in the epithelial cells has a specificity of 85% and sensitivity of 72% for predicting malignancy in mucinous cysts.<sup>25</sup>

Brushing the cyst wall during FNA increases the diagnostic

yield of EUS-guided FNA. In a study of 37 patients with pancreatic cystic lesion, the sensitivity of cyst fluid FNA for detecting intracellular mucin was 23%. The sensitivity was increased to 62% by brushing the cyst wall.<sup>26</sup>

Also, performing FNA of the far wall of the cyst (called cyst wall puncture) may increase the yield of EUS-guided FNA for diagnosing mucinous cyst.<sup>27</sup>

Carcinoembryonic antigen (CEA) of the cyst fluid is the most accurate test for determining the cyst as mucinous.<sup>28</sup> Using the cut-off value of 192 ng/mL CEA has a sensitivity of 73% and specificity of 84% for differentiating mucinous from non-mucinous cystic lesions.<sup>22</sup> It should be noted that cyst fluid CEA is not accurate enough for differentiating malignant from non-malignant mucinous cysts.<sup>29</sup> Also, CEA cannot differentiate mucinous cystadenoma from IPMN as it is elevated in all mucinous cysts.<sup>30</sup>

Amylase of the cyst fluid is elevated whenever the cyst has a communication to the pancreatic duct. Van der Waaj et al. reported that cyst fluid amylase of less than 250 U/L virtually excludes pseudocyst.<sup>31</sup> However, it should be noted that high levels of cyst fluid amylase cannot confirm the diagnosis of pseudocyst or exclude mucinous cystic lesion. High levels of cyst fluid amylase are also seen in patients with IPMN as the cyst has communication with the pancreatic duct.

Molecular markers in the cyst fluid are being increasingly studied in the recent years.

PathfinderTG is a commercial biomarker panel which consists of k-ras mutation, DNA content, and loss of heterozygosity at microsatellites linked to tumor suppressor genes.<sup>32</sup>

Khalid et al. evaluated the pancreatic cyst fluid for molecular markers. They found elevated DNA content and high amplitude k-ras mutation may indicate malignancy. Also, the presence of k-ras mutation was indicative for mucinous cystic lesion.<sup>33</sup> However, another study doubted the value of PathfinderTG in patients with small cysts and low clinical suspicion for malignancy.<sup>32</sup> Also, Chai et al. assessed the performance of CEA, cytology and k-ras mutation in the cyst fluid for diagnosing mucinous cysts. They found an elevated cyst fluid CEA is the most sensitive test to diagnose mucinous cysts, however k-ras mutation identified mucinous cysts in 2 of 25 (8%) patients in whom CEA and cytology were noncontributory.<sup>34</sup> In general, it can be concluded that CEA and cytology are the most helpful diagnostic tests on the cyst fluid; however, molecular testing (particularly k-ras mutation) has the small added value to the combination of CEA and cytology. Considering the low sensitivity of k-ras testing, a negative test does not exclude a mucinous cyst, however, a positive k-ras mutation supports the diagnosis of mucinous cyst when cyst fluid CEA is not elevated.<sup>2</sup>

In general, we recommend the cyst fluid is evaluated for cytology, CEA, and amylase. In instances where clinical suspicion for mucinous cyst is high and CEA is not elevated, the cyst fluid can be evaluated for k-ras testing if available.

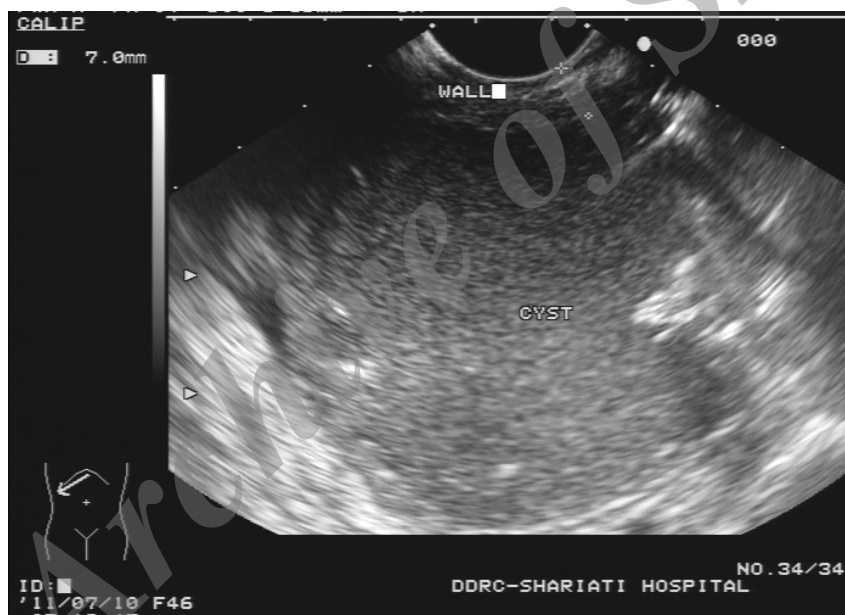Here we briefly discuss the current diagnosis and management of common pancreatic cystic lesions (Table 1).

#### Pancreatic pseudocyst

Patients with pancreatic pseudocyst typically have a history of acute or chronic pancreatitis. Pseudocysts are slightly more common in men than in women. They are mostly unilocular or less likely oligolocular, and have no or few septa. They do not have enhancing mural nodule on contrast-enhanced CT or MRI, and usu-

**Table 1.** EUS features and cyst fluid characteristics of common pancreatic cysts.

	Pseudocyst	MCN	IPMN	SCN	SPN	NET¶	
<b>Gender difference</b>	M = F	F > M	F = M	F > M	F > M	M > F¶	
<b>Location</b>	Anywhere	Body & tail>head	Head>body & tail	Body & tail>head	Body & tail>head	Body & tail>head¶	
<b>EUS features</b>	Mostly unilocular; Anechoic, or contains debris	Unilocular or oligolocular; May have mural nodule	Multiple cysts communicated to PD; Dilated PD on MD-IPMN	Honeycombing appearance; central calcification in one third	Mixed solid-cystic; well defined margin	Mixed solid-cystic, or cystic	
	CEA	Low	High	High	Low	NA	Low*
	Amylase	High	Usually low, but can be high*	High	Low	NA	Low*
<b>Cyst fluid analysis</b>	Cytology	Inflammatory cells	Extracellular mucin or mucinous epithelial cells may be seen; Atypical cells may be seen	Extracellular mucin or mucinous epithelial cells may be seen; Atypical cells may be seen	Acellular or hypocellular sample; Cuboidal cells with cytoplasmic glycogen†	Branching papilla with fibrovascular core; IHC: positive for vimentin & CD10‡	Plasmacytoid cells with round to oval nuclei; IHC: positive for synaptophysin, chromogranin£
MCN = mucinous cystic neoplasm; IPMN = intraductal papillary mucinous neoplasm; SCN = serous cystadenoma; SPN = solid pseudopapillary neoplasm; NET = neuroendocrine tumor; PD = pancreatic duct; MD-IPMN = main duct IPMN; NA = not available; ¶NET is usually solid with a well defined margin, however, it can be cystic in 10% of the cases (Reference 35); *Reference 36; ¶Reference 37; £Reference 38; †Reference 39; ‡Reference 40.							

**Figure 1.** EUS appearance in a patient with a large pseudocyst in the pancreatic head. The cyst contains debris. The cyst was drained through EUS-guided cyst-duodenostomy.

ally have a thin and uniform wall.<sup>41</sup> On EUS, some pseudocysts are uniformly anechoic and some others contain large amounts of debris (Figure 1). Cyst fluid is yellow to brown. Infected pseudocysts may contain gross pus. Cyst fluid contains low CEA and high amylase levels. Pancreatic pseudocyst in an asymptomatic patient can be managed expectantly; however, a large pseudocyst in a symptomatic patient requires intervention. The intervention includes drainage rather than resection. Drainage of pancreatic pseudocyst can be carried out through endoscopic, radiologic, or surgical approach.<sup>42</sup> EUS-guided drainage is emerging as a safe and effective way to treat pancreatic pseudocysts.<sup>43,44</sup>

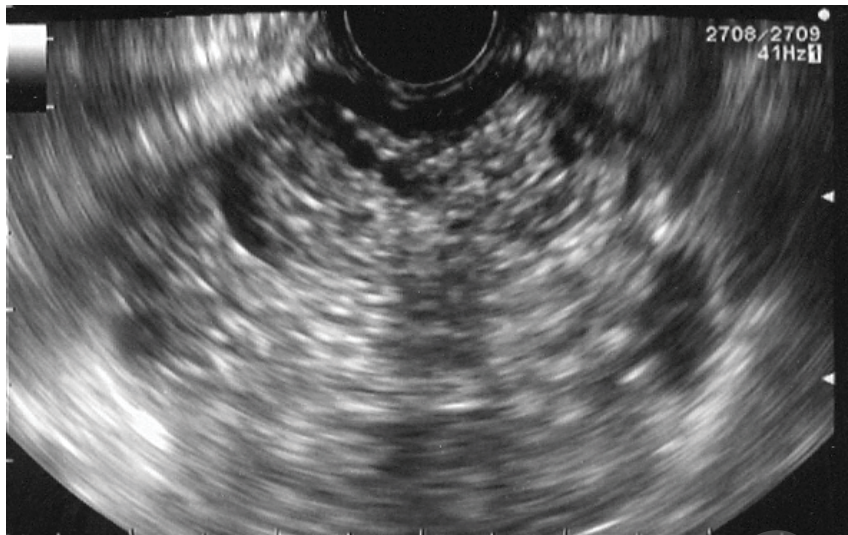
#### Serous cystadenoma

Serous cystadenoma is a benign cystic lesion and accounts for

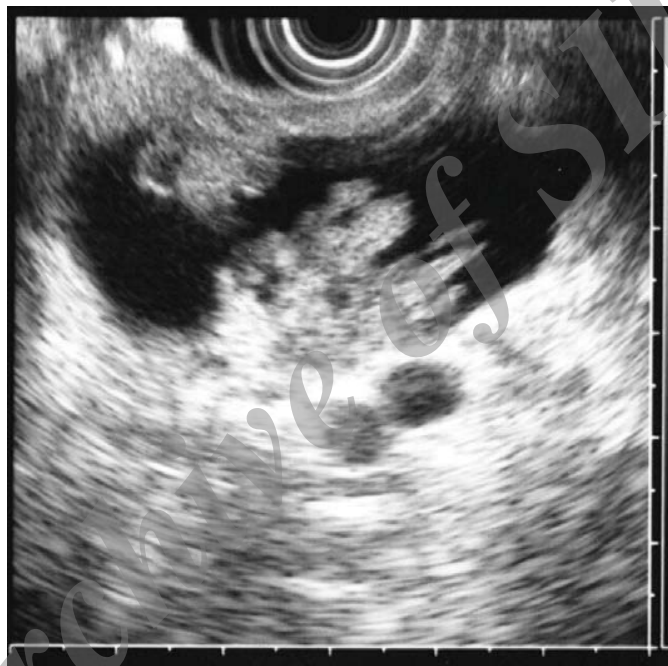about one third of PCs.<sup>45</sup> The mean age at presentation is around 60 years and 75% of the affected individuals are female.<sup>46</sup>

In a large surgical series of patients with serous cystadenoma, 44% of the lesions were located in the neck, head, or uncinate process of the pancreas and 56% were in the body or tail region.<sup>46</sup> The typical endosonographic feature of serous cystadenoma includes aggregates of several small (3 to 5 mm each) cysts separated by thin septa making a honeycombing appearance (Figure 2). The aggregates of very small cystic lesions might be mistaken as a solid mass on CT scan. The characteristic central calcified scar which is called sunburst appearance can be best seen on CT scan in up to 30% of the patients.

In up to 10% of the patients, serous cystadenoma may have oligocystic or macrocystic appearance and might be mistaken with



**Figure 2.** EUS features of microcystic serous cystadenoma with honeycombing appearance.



**Figure 3.** EUS features of main duct intraductal papillary mucinous neoplasm (IPMN) of the pancreas. Note the ectatic dilation of the main pancreatic duct which harbors multiple mural nodules.

mucinous cystadenoma.<sup>45</sup>

On EUS-guided FNA, the cyst fluid is colorless or blood tinged and contains low amylase and CEA levels.<sup>5</sup> The cysts that are larger than 4 cm are more likely to be symptomatic. Also, the growth rate of the lesions larger than 4 cm is significantly higher than the smaller lesions.<sup>46</sup> Therefore, it is recommended that patients with symptomatic lesion or those with lesions larger than 4 cm undergo surgical resection.

Asymptomatic patients with small serous cystadenoma (e.g., less than 4 cm in size) can be managed with periodic follow up.

#### Mucinous cystic neoplasms

Mucinous cystic neoplasms (MCNs) are classified into mucinous cystadenoma and mucinous cystadenocarcinoma. MCNs are pathologically characterized as having mucin producing epithelial lining and ovarian stroma.<sup>47</sup> Mucinous cystadenoma is a pre-ma-

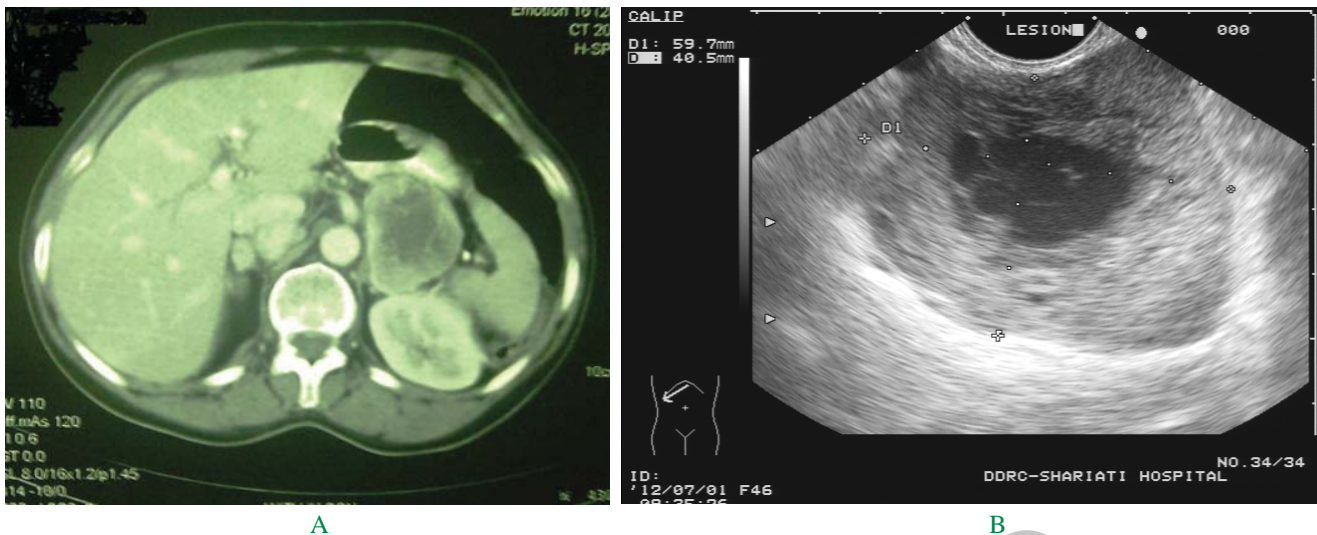
lignant lesion and may progress to carcinoma in-situ or invasive mucinous cystadenocarcinoma.<sup>47</sup>

MCNs are seen almost exclusively in women. More than 90% of the lesions are located in the body or tail of the pancreas.<sup>47</sup>

On EUS, the lesion is typically unilocular or oligolocular containing 6 or fewer locules each of which is greater than 2 cm. There might be peripheral calcification in less than a quarter of the patients.<sup>48,49</sup> MCN has no communication to the pancreatic duct. The presence of thick wall, mural nodule or associated mass lesion raises suspicion for superimposed invasive cancer.

Differentiating mural nodule from mucin can be difficult in a mucinous cystic lesion.

In a recent study, EUS detected mural nodule with 75% sensitivity and 83% specificity, however these values were 24% and 100%, respectively for CT scan.<sup>50</sup> The presence of color Doppler flow, or lack of mobility with changing position favor the pres-



**Figure 4.** A) CT image of cystic neuroendocrine tumor in a middle aged woman. B) EUS image showing the lesion as a solid mass which contains a cystic component in its central part. EUS-guided FNA confirmed the diagnosis.

ence of mural nodule. The following features favor the presence of mucin rather than mural nodule on EUS: being hypoechoic with a hyperechoic rim, having a smooth edge, movement with changing position or saline lavage, movement with the tip of the needle during FNA.<sup>50</sup>

EUS-guided FNA is helpful for making pre-operative diagnosis of MCNs. Typically, the cyst fluid in MCN is colorless and transparent, has high viscosity, and contains high CEA and low amylase levels.

In a large series, 10% of MCNs had invasive cancer at the time of resection.<sup>4</sup>

As MCNs are pre-malignant lesions or already harbor malignancy, they should be resected in surgically fit patients. Benign MCN does not recur after surgical resection.<sup>47</sup>

There has been interest in the recent years to ablate mucinous cystic lesions of the pancreas through non-invasive approaches. In a randomized trial, EUS-guided ethanol lavage resulted in greater decrease in pancreatic cyst size compared with saline solution lavage. In this study, CT-defined complete cyst ablation achieved in one third of patients.<sup>51</sup>

In another study of patients with suspected mucinous cystic lesions, EUS-guided ethanol lavage followed by injection of paclitaxel led to complete resolution of the cysts in 62% of the patients.<sup>52</sup>

It should be noted that EUS-guided cyst ablation is still an investigational approach and cannot be considered outside the clinical trials.

#### Intraductal papillary mucinous neoplasm

IPMN was first described in 1982.<sup>53</sup> It is increasingly being diagnosed in the recent years, so that IPMN is the most common type of PCs resected in the recent years.<sup>4</sup> Patients with IPMN are generally older than those with MCN (69 vs. 51 years, respectively in a recent surgical series).<sup>4</sup> Pathologically, IPMN is characterized by proliferation of mucinous cells arising from main pancreatic duct or side branches of pancreatic duct. So that it is classified into main duct (MD-IPMN), branch-duct (BD-IPMN), and mixed IPMN. The latter involves both the main duct and side branches. IPMN may progress from adenoma, to carcinoma in

situ and finally to invasive carcinoma. MD-IPMN affects both genders equally, while BD-IPMN is more common in females. About 70% of MD-IPMN and 60% of BD-IPMN are located in the head, neck, or uncinate process of the pancreas.<sup>4</sup> One third of MD-IPMN harbor invasive cancer at the time of resection. Although the natural course of small BD-IPMN in asymptomatic individuals is less clear, but about 14% of BD-IPMN have invasive cancer at the time of resection.<sup>4</sup>

On EUS, MD-IPMN presents as diffuse dilation of main pancreatic duct with mural ductal nodules and intra-luminal filling defects (Figure 3). BD-IPMNs present with multiple or (less likely single) cystic lesions in the pancreas which have communication with the pancreatic duct. Main pancreatic duct is normal sized or slightly dilated in BD-IPMN. Cyst fluid is typically colorless and transparent in IPMN and contains high levels of CEA and amylase.

High risk features in IPMN include the presence of mural nodule or mass lesion, cyst size larger than 3 cm, main pancreatic duct diameter >5 mm, cyst fluid cytology suspicious or positive for malignancy, and presence of obstructive jaundice.<sup>54</sup>

Management of main duct IPMN includes surgical resection. However, there are several points that make the management of BD-IPMN more challenging. BD-IPMN has more indolent natural course than MD-IPMN; there is a risk of recurrence after surgical resection of BD-IPMN; and patients with BD-IPMNs involving the entire pancreas may require total pancreatectomy which is associated with significant long term morbidity. Therefore, a small BD-IPMNs in asymptomatic individual can be managed by watchful-waiting strategy with periodic MRI or EUS. However, the presence of any of the high risk features mentioned above mandates surgical resection of the lesion in surgically fit individuals.<sup>54</sup>

#### Solid pseudopapillary neoplasm

Solid pseudopapillary neoplasm (SPN) generally occurs in young women. About 70% of the lesions are located in the body/tail region of the pancreas.<sup>4</sup> SPN presents as a solid-cystic mass lesion with well-defined margin on imaging. In a series of 28 patients with SPN, the tumor was solid in 50%, mixed solid-cystic

in 39%, and cystic in 11% on EUS imaging.<sup>55</sup>

In this series, EUS-guided FNA was diagnostic in 75% of SPNs.<sup>55</sup> FNA typically shows cohesive groups of small uniform cells in branching and papillary structures. IHC staining on tumor cells is positive for vimentin and CD 10.<sup>40</sup>

SPNs are frequently diagnosed incidentally in asymptomatic individuals. However, larger lesions may present with abdominal pain. SPNs have an indolent course, however, if left untreated may invade into adjacent organs and major vessels.<sup>56</sup> Treatment includes surgical resection.

#### Cystic neuroendocrine tumors

Pancreatic neuroendocrine tumors usually present as solid, homogeneous mass lesion with a well-defined margin on EUS.<sup>37</sup> However, about 10% of neuroendocrine tumors are cystic (Figures 4A and 4B).<sup>35</sup>

In a series of nine patients with cystic neuroendocrine tumors (NETs), the lesions were mixed solid cystic in 4 and pure cystic in 5.<sup>35</sup> Cyst fluid from a cystic NET typically have low CEA and amylase levels.<sup>36</sup> Cytology from the cyst fluid or the solid component shows cohesive groups of plasmacytoid cells with round-to oval, mildly enlarged nuclei. IHC staining is positive for synaptophysin and chromogranin.<sup>38</sup>

#### Rare non-neoplastic pancreatic cysts

Lymphoepithelial cyst is a rare, benign non-neoplastic cyst of the pancreas. It is more common in men and evenly distributed throughout the pancreas. Most of the lesions are discovered incidentally on abdominal imaging. As it is filled with large number of debris, the lesion appears as a well-defined solid appearing hypoechoic and heterogeneous mass on EUS.<sup>57</sup> The cyst fluid is milky in color and cytology shows squamous cells, keratinaceous debris and lymphoid cells.<sup>58</sup> Asymptomatic lesions are managed conservatively, however, surgical resection is indicated if the patient is symptomatic or if the diagnosis is doubtful.

Benign epithelial cyst, also called simple cyst is a rare non-neoplastic cyst. Imaging usually shows a unilocular cyst with a thin wall and no mural nodule. It is associated with autosomal dominant polycystic kidney disease. The lesion may undergo surgical resection if a neoplastic cyst cannot be excluded.<sup>59</sup>

Hydatid disease is caused by the larval stage of tapeworm *Echinococcus granulosus*. The liver is the most common site of infection. Rarely, the pancreas is the only affected organ.<sup>60</sup> The hydatid cyst has variable features on trans-abdominal or endoscopic ultrasonography depending on the stage of the disease. In early stages it appears as a unilocular cyst. Several echogenic foci due to hydatid sand may be seen inside the cyst. The cyst wall usually appears as double echogenic lines separated by a hypoechoic layer. In later stages of the disease, the lesion manifests as multivesicular and multiseptated cyst. The septations represent the walls of daughter cysts. In final stages the cyst develops a thick calcified wall.<sup>61</sup> This rare medical entity should be considered in patients with pancreatic cystic lesions who have conditions such as living in or emigrated from endemic areas, positive serologic test for hydatid cyst, and the presence of appropriate sonographic features. Treatment includes medical therapy with albendazole and surgical resection.

In conclusion, PCs are being increasingly detected in current clinical practice. Pre-operative diagnosis of PCs has been improved significantly in the recent years by the use of MRI and

EUS-guided FNA. This has led to decreased unnecessary surgical resection of benign cystic lesions. Also, many patients with BD-IPMN and no high risk feature can be managed expectantly. We also believe that multidisciplinary approach that involves gastroenterologist, surgeons and radiologists can be very important in managing patients with pancreatic cystic lesions of the pancreas.

## References

- Laffan TA, Horton KM, Klein AP, Berlanstein B, Siegelman SS, Kawamoto S, et al. Prevalence of unsuspected pancreatic cysts on MDCT. *AJR Am J Roentgenol.* 2008; **191**: 802 – 807.
- Pitman MB. Pancreatic cyst fluid triage: a critical component of the preoperative evaluation of pancreatic cysts. *Cancer Cytopathol.* 2012 Sep 7. doi: 10.1002/cncy.21227.
- Kimura W. How many millimeters do atypical epithelia of the pancreas spread intraductally before beginning to infiltrate? *Hepatogastroenterology.* 2003; **50**: 2218 – 2224.
- Valsangkar NP, Morales-Oyarvide V, Thayer SP, Ferrone CR, Wargo JA, Warshaw AL, et al. 851 resected cystic tumors of the pancreas: a 33-year experience at the Massachusetts General Hospital. *Surgery.* 2012; **152**(3 suppl 1): S4 – S12.
- Al-Haddad M, El Hajj II, Eloubeidi MA. Endoscopic ultrasound for the evaluation of cystic lesions of the pancreas. *JOP.* 2010; **11**: 299 – 309
- Meyer W, Köhler J, Gebhardt C. Cystic neoplasms of the pancreas-cystadenomas and cystadenocarcinomas. *Langenbecks Arch Surg.* 1999; **384**: 44 – 49.
- Spinelli KS, Fromwiller TE, Daniel RA, Kiely JM, Nakeeb A, Komorowski RA, et al. Cystic pancreatic neoplasms: observe or operate. *Ann Surg.* 2004; **239**: 651 – 659.
- Zhang XM, Mitchell DG, Dohke M, Holland GA, Parker L. Pancreatic cysts: depiction on single-shot fast spin-echo MR images. *Radiology.* 2002; **223**: 547 – 553.
- Megibow AJ, Lombardo FP, Guarise A, Carboogni G, Scholes J, Rofsky NM, et al. Cystic pancreatic masses: cross-sectional imaging observations and serial follow-up. *Abdom Imaging.* 2001; **26**: 640 – 647.
- Zamboni G, Kloeppl G, Hruban RH, et al. Mucinous cystic neoplasms of the pancreas. In: Aaltonen LA, Hamilton, SR, eds. *World Health Organization Classification of Tumours. Pathology and Genetics of Tumours of the Digestive System.* Lyon, France: IARC Press; 2000: 234.
- Canto MI, Hruban RH, Fishman EK, Kamel IR, Schulick R, Zhang Z, et al. Frequent detection of pancreatic lesions in asymptomatic high-risk individuals. *Gastroenterology.* 2012; **142**: 796 – 804
- Samarasena JB, Nakai Y, Chang KJ. Endoscopic ultrasonography-guided fine-needle aspiration of pancreatic cystic lesions: a practical approach to diagnosis and management. *Gastrointest Endosc Clin N Am.* 2012; **22**: 169 – 185.
- Procacci C, Biasiutti C, Carboogni G, Accordini S, Bicego E, Guarise A, et al. Characterization of cystic tumors of the pancreas: CT accuracy. *J Comput Assist Tomogr.* 1999; **23**: 906 – 912
- Visser BC, Yeh BM, Qayyum A, Way LW, McCulloch CE, Coakley FV. Characterization of cystic pancreatic masses: relative accuracy of CT and MRI. *AJR Am J Roentgenol.* 2007; **189**: 648 – 656
- Sainani NI, Saokar A, Deshpande V, Fernández-del Castillo C, Hahn P, Sahani DV. Comparative performance of MDCT and MRI with MR cholangiopancreatography in characterizing small pancreatic cysts. *AJR Am J Roentgenol.* 2009; **193**: 722 – 731.
- Song SJ, Lee JM, Kim YJ, Kim SH, Lee JY, Han JK, et al. Differentiation of intraductal papillary mucinous neoplasms from other pancreatic cystic masses: comparison of multirow-detector CT and MR imaging using ROC analysis. *J Magn Reson Imaging.* 2007; **26**: 86 – 93.
- Macari M, Finn ME, Bennett GL, Cho KC, Newman E, Hajdu CH, et al. Differentiating pancreatic cystic neoplasms from pancreatic pseudocysts at MR imaging: value of perceived internal debris. *Radiology.* 2009; **251**: 77 – 84
- Sahani DV, Sainani NI, Blake MA, Crippa S, Mino-Kenudson M, del-Castillo CF. Prospective evaluation of reader performance on MDCT in characterization of cystic pancreatic lesions and prediction of cyst biologic aggressiveness. *AJR Am J Roentgenol.* 2011; **197**: W53 – W61.
- Lee HJ, Kim MJ, Choi JY, Hong HS, Kim KA. Relative accuracy of

- CT and MRI in the differentiation of benign from malignant pancreatic cystic lesions. *Clin Radiol*. 2011; **66**: 315 – 321
20. Kawamoto S, Lawler LP, Horton KM, Eng J, Hruban RH, Fishman EK. MDCT of intraductal papillary mucinous neoplasm of the pancreas: evaluation of features predictive of invasive carcinoma. *AJR Am J Roentgenol*. 2006; **186**: 687 – 695.
  21. Lee CJ, Scheiman J, Anderson MA, Hines OJ, Reber HA, Farrell J. Risk of malignancy in resected cystic tumors of the pancreas < or =3 cm in size: is it safe to observe asymptomatic patients? A multi-institutional report. *J Gastrointest Surg*. 2008; **12**: 234 – 242.
  22. Brugge WR, Lewandrowski K, Lee-Lewandrowski E, Centeno BA, Szydio T, Regan S, et al. Diagnosis of pancreatic cystic neoplasms: a report of the cooperative pancreatic cyst study. *Gastroenterology*. 2004; **126**: 1330 – 1336.
  23. Ahmad NA, Kochman ML, Brensinger C, Brugge WR, Faigel DO, Gress FG, et al. Interobserver agreement among endosonographers for the diagnosis of neoplastic versus non-neoplastic pancreatic cystic lesions. *Gastrointest Endosc*. 2003; **58**: 59 – 64.
  24. Adimoolam V, Sanchez MJ, Siddiqui UD, Yu S, Dzuira JD, Padda MS, et al. Endoscopic ultrasound identifies synchronous pancreas cystic lesions not seen on initial cross-sectional imaging. *Pancreas*. 2011; **40**: 1070 – 1072.
  25. Genevay M, Mino-Kenudson M, Yaeger K, Konstantinidis IT, Ferrone CR, Thayer S, et al. Cytology adds value to imaging studies for risk assessment of malignancy in pancreatic mucinous cysts. *Ann Surg*. 2011; **254**: 977 – 983.
  26. Al-Haddad M, Gill KR, Raimondo M, Woodward TA, Krishna M, Crook JE, et al. Safety and efficacy of cytology brushings versus standard fine-needle aspiration in evaluating cystic pancreatic lesions: a controlled study. *Endoscopy*. 2010; **42**: 127 – 132.
  27. Hong SK, Loren DE, Rogart JN, Siddiqui AA, Sendecki JA, Bibbo M, et al. Targeted cyst wall puncture and aspiration during EUS-FNA increases the diagnostic yield of premalignant and malignant pancreatic cysts. *Gastrointest Endosc*. 2012; **75**: 775 – 782.
  28. Pitman MB. Revised international consensus guidelines for the management of patients with mucinous cysts. *Cancer Cytopathol*. 2012; **120**: 361 – 365.
  29. Pais SA, Attasaranya S, Leblanc JK, Sherman S, Schmidt CM, DeWitt J. Role of endoscopic ultrasound in the diagnosis of intraductal papillary mucinous neoplasms: correlation with surgical histopathology. *Clin Gastroenterol Hepatol*. 2007; **5**: 489 – 495.
  30. Al-Rashdan A, Schmidt CM, Al-Haddad M, McHenry L, Leblanc JK, Sherman S, et al. Fluid analysis prior to surgical resection of suspected mucinous pancreatic cysts. A single centre experience. *J Gastrointest Oncol*. 2011; **2**: 208 – 214.
  31. van der Waaij LA, van Dullemen HM, Porte RJ. Cyst fluid analysis in the differential diagnosis of pancreatic cystic lesions: a pooled analysis. *Gastrointest Endosc*. 2005; **62**: 383 – 389.
  32. Panarelli NC, Sela R, Schreiner AM, Crapanzano JP, Klimstra DS, Schnoll-Sussman F, et al. Commercial molecular panels are of limited utility in the classification of pancreatic cystic lesions. *Am J Surg Pathol*. 2012; **36**: 1434 – 1443
  33. Khalid A, Zahid M, Finkelstein SD, LeBlanc JK, Kaushik N, Ahmad N, et al. Pancreatic cyst fluid DNA analysis in evaluating pancreatic cysts: a report of the PANDA study. *Gastrointest Endosc*. 2009; **69**: 1095 – 1102.
  34. Chai SM, Herba K, Kumarasinghe MP, de Boer WB, Amanuel B, Grieu-Iacopetta F, et al. Optimizing the multimodal approach to pancreatic cyst fluid diagnosis: Developing a volume-based triage protocol. *Cancer Cytopathol*. 2012 Sep 7. doi: 10.1002/cncy.21226.
  35. Kongkam P, Al-Haddad M, Attasaranya S, O'Neil J, Pais S, Sherman S, et al. EUS and clinical characteristics of cystic pancreatic neuroendocrine tumors. *Endoscopy*. 2008; **40**: 602 – 605.
  36. Park WG, Mascarenhas R, Palaez-Luna M, Smyrk TC, O'Kane D, Clain JE, et al. Diagnostic performance of cyst fluid carcinoembryonic antigen and amylase in histologically confirmed pancreatic cysts. *Pancreas*. 2011; **40**: 42 – 45.
  37. Pais SA, Al-Haddad M, Mohamadnejad M, Leblanc JK, Sherman S, McHenry L, et al. EUS for pancreatic neuroendocrine tumors: a single-center, 11-year experience. *Gastrointest Endosc*. 2010; **71**: 1185 – 1193.
  38. Mohamadnejad M, Emerson R, DeWitt J. Photoclinic. Pancreatic neuroendocrine tumor. *Arch Iran Med*. 2010; **13**: 445 – 446.
  39. Huang P, Staerckel G, Sneige N, Gong Y. Fine-needle aspiration of pancreatic serous cystadenoma: cytologic features and diagnostic pitfalls. *Cancer*. 2006; **108**: 239 – 249.
  40. Song JS, Yoo CW, Kwon Y, Hong EK. Endoscopic ultrasound-guided fine needle aspiration cytology diagnosis of solid pseudopapillary neoplasm: three case reports with review of literature. *Korean J Pathol*. 2012; **46**: 399 – 406.
  41. Buerke B, Domagk D, Heindel W, Wessling J. Diagnostic and radiological management of cystic pancreatic lesions: important features for radiologists. *Clin Radiol*. 2012; **67**: 727 – 737.
  42. Cannon JW, Callery MP, Vollmer CM Jr. Diagnosis and management of pancreatic pseudocysts: what is the evidence? *J Am Coll Surg*. 2009; **209**: 385 – 393.
  43. Varadarajulu S. Endoscopic management of pancreatic pseudocysts. *J Digest Endosc*. 2012; **5**: 58 – 64.
  44. Seewald S, Ang TL, Teng KC, Soehendra N. EUS-guided drainage of pancreatic pseudocysts, abscesses and infected necrosis. *Dig Endosc*. 2009; **21(Suppl 1)**: S61 – S65.
  45. Sakorafas GH, Smyrniotis V, Reid-Lombardo KM, Sarr MG. Primary pancreatic cystic neoplasms revisited. Part I: serous cystic neoplasms. *Surg Oncol*. 2011; **20**: e84 – e92.
  46. Tseng JF, Warshaw AL, Sahani DV, Lauwers GY, Rattner DW, Fernandez-del Castillo C. Serous cystadenoma of the pancreas: tumor growth rates and recommendations for treatment. *Ann Surg*. 2005; **242**: 413 – 421.
  47. Reddy RP, Smyrk TC, Zapiach M, Levy MJ, Pearson RK, Clain JE, et al. Pancreatic mucinous cystic neoplasm defined by ovarian stroma: demographics, clinical features, and prevalence of cancer. *Clin Gastroenterol Hepatol*. 2004; **2**: 1026 – 1031.
  48. Acar M, Tatli S. Cystic tumors of the pancreas: a radiological perspective. *Diagn Interv Radiol*. 2011; **17**: 143 – 149.
  49. Paspulati RM. Multidetector CT of the pancreas. *Radiol Clin North Am*. 2005; **43**: 999 – 1020.
  50. Zhong N, Zhang L, Takahashi N, Shalmiyev V, Canto MI, Clain JE, et al. Histologic and imaging features of mural nodules in mucinous pancreatic cysts. *Clin Gastroenterol Hepatol*. 2012; **10**: 192 – 198.
  51. DeWitt J, McGreevy K, Schmidt CM, Brugge WR. EUS-guided ethanol versus saline solution lavage for pancreatic cysts: a randomized, double-blind study. *Gastrointest Endosc*. 2009; **70**: 710 – 723.
  52. Oh HC, Seo DW, Song TJ, Moon SH, Park do H, Soo Lee S, et al. Endoscopic ultrasonography-guided ethanol lavage with paclitaxel injection treats patients with pancreatic cysts. *Gastroenterology*. 2011; **140**: 172 – 179.
  53. Ohashi K, Murakami Y. Four cases of “mucin-producing” cancer of the pancreas (Japanese). *Prog Digest Endosc*. 1982; **20**: 348 – 351.
  54. Tanaka M, Fernández-del Castillo C, Adsay V, Chari S, Falconi M, Jang JY, et al. International consensus guidelines 2012 for the management of IPMN and MCN of the pancreas. *Pancreatol*. 2012; **12**: 183 – 197.
  55. Jani N, Dewitt J, Eloubeidi M, Varadarajulu S, Appalaneni V, Hoffman B, et al. Endoscopic ultrasound-guided fine-needle aspiration for diagnosis of solid pseudopapillary tumors of the pancreas: a multicenter experience. *Endoscopy*. 2008; **40**: 200 – 203.
  56. Santini D, Poli F, Lega S. Solid-papillary tumors of the pancreas: histopathology. *JOP*. 2006; **7**: 131 – 136.
  57. Nasr J, Sanders M, Fasanella K, Khalid A, McGrath K. Lymphoepithelial cysts of the pancreas: an EUS case series. *Gastrointest Endosc*. 2008; **68**: 170 – 173.
  58. Karim Z, Walker B, Lam E. Lymphoepithelial cysts of the pancreas: the use of endoscopic ultrasound-guided fine-needle aspiration in diagnosis. *Can J Gastroenterol*. 2010; **24**: 348 – 350.
  59. Bergin D, Ho LM, Jowell PS, Pappas TN, Paulson EK. Simple pancreatic cysts: CT and endosonographic appearances. *AJR Am J Roentgenol*. 2002; **178**: 837 – 840.
  60. Krige JE, Mirza K, Bornman PC, Beningfield SJ. Primary hydatid cysts of the pancreas. *S Afr J Surg*. 2005; **43**: 37 – 40.
  61. Pedrosa I, Safz A, Arrazola J, Ferreirós J, Pedrosa CS. Hydatid disease: radiologic and pathologic features and complications. *Radiographics*. 2000; **20**: 795 – 817.