

## Case Report

# Surgical Management of a Rare form of Cervical Dysgenesis with Normal Vagina, Normal Vaginal Portion of the Cervix and Obstructed Uterus

Mohammad Ebrahim Parsanezhad MD<sup>1</sup>, Bahia Namavar Jahromi MD<sup>2</sup>, Leila Salarian MD<sup>3</sup>, Maryam Parsa-Nezhad<sup>4</sup>

## Abstract

This case was an extremely rare form of cervical dysgenesis that presented with cyclic pain. Diagnostic laparoscopy and vaginoscopy showed the presence of a blind uterus at the level of the internal cervical os with a normal vagina and exocervix. Müllerian ducts are the embryologic origin for the uterus, cervix and upper part of the vagina. Müllerian duct migration initiates from the upper part of the Müllerian system. Therefore an obstructed uterus is usually associated with cervical and upper vaginal anomalies. This case was unusual because of the presence of an isolated segmental atresia at the level of the internal cervical os. However the vaginal portion of the cervix, vagina and urinary system were normal. We theorized that the absence of an appropriate fusion between the Müllerian duct and its underlying mesoderm, loss of cell-to-cell communication and special gene expression during a critical time period or a vascular accident between 12–22 weeks of gestation might have caused this anomaly. The patient underwent a laparotomy to create a utero-cervical canal using a peritoneal graft.

**Keywords:** Müllerian aplasia/dysgenesis, Müllerian ducts/abnormalities, uterine cervix

**Cite the article as:** Parsanezhad ME, Namavar Jahromi B, Salarian L, Parsa-Nezhad M. Surgical Management of a Rare form of Cervical Dysgenesis with Normal Vagina, Normal Vaginal Portion of the Cervix and Obstructed Uterus. *Arch Iran Med.* 2013; **16**(4): 246 – 248.

## Introduction

According to the American Fertility Society (AFS), cervical agenesis or dysgenesis is classified as a class IB Müllerian anomaly under segmental Müllerian agenesis-hypoplasia and class IIB in the classification of uterovaginal anomalies under disorders of vertical fusion.<sup>1</sup> Agenesis of the uterine cervix is rare and usually associated with the absence of a segment or all of the vagina.<sup>2</sup> Cervical dysgenesis has been classified by Rock et al. into three subtypes: a) a well-formed cervix with obstruction of the endocervical lumen; b) a cervical cord observed with a completely obstructed endocervical canal; and c) fragmentation of the cervix with certain palpable areas of the cervix.<sup>3</sup>

The current case had a single functional uterus that was obstructed at the lower segment, with no communication to a single, normal appearing cervix and vagina. This case might be considered a variant of uterine cervical dysgenesis at the level of the internal os, however, none of the available classifications completely matched her anatomical abnormality. This case has been considered to be unusual because according to the embryologic devel-

opmental theory of female reproductive tract anomalies, when a cervix is normally present usually the uterus and upper vagina should also be present and thoroughly canalized. The patient has undergone a successful surgical intervention which resulted in the creation of a functional utero-cervical canal. Peritoneal graft was used for covering the canal.

## Case Report

A twelve-year-old female with complaints of primary amenorrhea and cyclic abdominal pain of one year duration was admitted to Shahid Faghihi Hospital. Ultrasound showed a 69 × 38 × 42 mm uterus with 20 mm fluid in the uterine cavity and normal ovaries. A small amount of free fluid was seen in the posterior cul-de-sac. Intravenous pyelography was normal. MRI showed a distended uterine cavity due to fluid accumulation which favored hematometra and an empty normal vagina. Obstruction at the cervical level was suggested.

Diagnostic laparoscopy showed an enlarged uterus and small endometriotic lesions on both tubes (Figure 1). Examination under anesthesia showed a normal clitoris, normal urethra and vaginal opening. Vaginoscopy showed a normal cervix and normal vaginal length. The cervical canal was only one cm deep with occlusion in the upper part (Figure 2). A thin fibrotic band about 3 cm between the cervix and the uterus was palpated during a rectal examination.

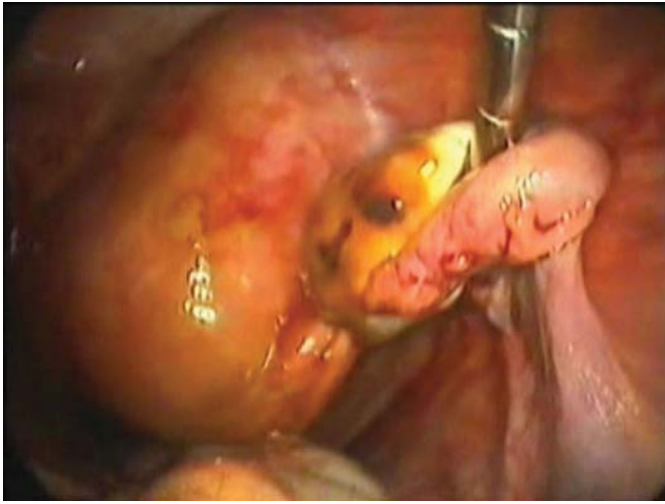
The condition was discussed with the patient and her family (Figure 3) and they decided upon reconstructive surgery in the next setting. However, the patient was lost to follow up for 15 months. During this period she had monthly pelvic pain and developed an abdominal protrusion.

**Authors' affiliations:** <sup>1</sup>Department of Obstetrics and Gynecology, Division of Reproductive Endocrinology and Infertility, School of Medicine, Shiraz University of Medical Sciences, Shiraz, Iran. <sup>2</sup>Infertility Research Center, Division of Reproductive Endocrinology and Infertility, Department of Obstetrics and Gynecology, School of Medicine, Shiraz University of Medical Sciences, Shiraz, Iran. <sup>3</sup>Department of Pediatrics, School of Medicine, Shiraz University of Medical Sciences, Shiraz, Iran. <sup>4</sup>Medical Student, Royal College of Surgeons in Ireland-Bahrain.

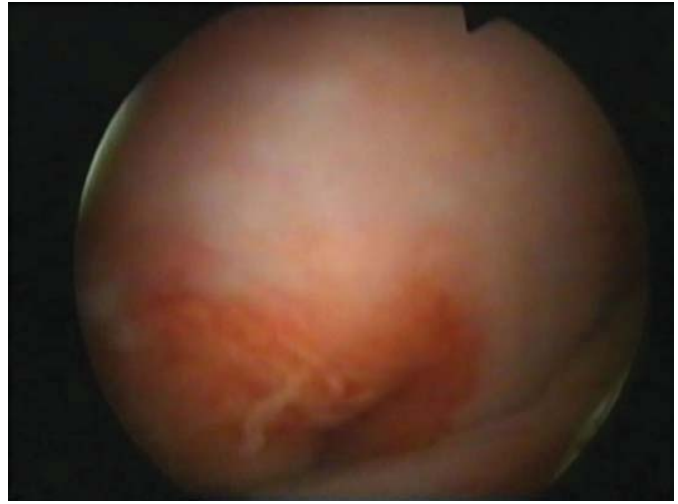**•Corresponding author and reprints:** Bahia Namavar Jahromi MD, Infertility Research Center, Division of Reproductive Endocrinology and Infertility, Department of Obstetrics and Gynecology, School of Medicine, Shiraz University of Medical Sciences, Shiraz, Iran. Tel: +98-917-315-8723;

Fax: +98-711-233-2365; E-mail: namavarb@sums.ac.ir

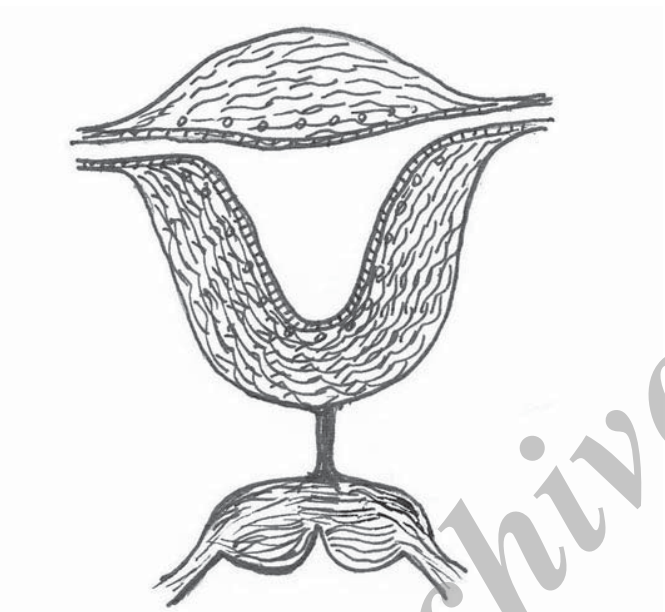Accepted for publication: 5 September 2012



**Figure 1.** Diagnostic laparoscopy showed enlarged uterus with engorged tubes and minimal endometriotic lesions on the tubes and ovaries.



**Figure 2.** Vaginoscopy showed a normal appearing cervix.

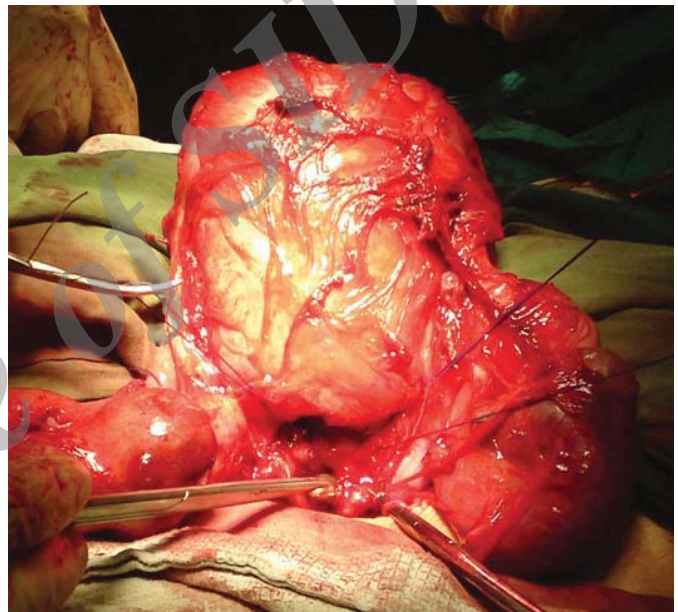

**Figure 3.** Schematic diagram of the anatomical abnormality.

An ultrasound scan performed during the second admission was remarkable for a large cystic structure (19 × 13.5 × 8 cm) filled with echogenic material. Other cystic structures (2 × 4 cm) were reported in both adnexa. Laboratory analyses had the following results: estrogen = 89, TSH = 1.5, FSH = 4.3, LH = 2.5, prolactin = 14.4, testosterone = 0.4, dehydroepiandrosterone sulfate (DHEAS) = 1, WBC = 7.6 × 10<sup>3</sup>/UL, RBC = 3.98 × 10<sup>6</sup>/UL, Hb = 10.2 g/dL, platelet = 422 × 10<sup>3</sup>/UL, INR = 1.09 mg/dL, FBS = 95 mg/dL, BUN = 16 mg/dL, creatinine = 0.5, and normal urinalysis.

The patient underwent a laparotomy. The abdomen was opened by a Pfannenstiel incision. An enlarged uterus and stage III endometriosis (according to the Revised Classification of the American Society for Reproductive Medicine) were seen (Figure 4).<sup>4</sup> Endometrial lesions were treated and the adhesions released.

A transverse incision on the lower part of the uterus was created and approximately 700 cc of old blood was drained. The ureters were catheterized to prevent any damage. The peritoneum of the post cul-de-sac on the blind cervical tissue was opened. Cervical tissue was opened and a Hegar dilator was placed inside to act as a guide for



**Figure 4.** Anastomosis of the uterus to the cervical stump by creation of a canal covered with a peritoneal graft.

the vaginal approach. The most dependent part of the uterus was incised. The openings of the cervix and uterus were anastomosed. A piece of pelvic parietal peritoneum was harvested and placed on a number 18 Foley catheter, then passed through the canal to cover the rough area. The graft was fixed between the most dependent part of the uterus and the lower portion of the dissected canal. Cystoscopy was normal after the procedure. Her hemoglobin declined to 8 g/dL and two bags of packed cells were transfused. She received ceftriaxone and metronidazole after the surgery and after three days, she was discharged from the hospital. The Foley catheter was passed spontaneously after two weeks. The patient has had spontaneous monthly menstrual bleeding since the time of the surgery until now, a period of approximately 20 months.

## Discussion

The AFS classification from the work of Buttram and Gibbons has classified various anomalies according to their clinical manifestations, treatment and prognosis.<sup>2</sup> However Rock specifically

introduced a classification for subdividing rare anomalies of the uterine cervix.<sup>3</sup> Our case may belong to class IIB in the AFS classification. However this case does not exactly match any of the presented sub-classifications of Rock.

Complete development of a genital tract is dependent upon three stages, organogenesis, lateral and vertical fusions, and septal resorption.<sup>5</sup> Up to eight weeks of embryonic life, both mesonephric (Wolffian) and paramesonephric (Müllerian) ducts coexist. In the third month, one of the duct systems persists normally and the other regresses.<sup>6</sup> In a nine-week-old embryo, the Müllerian ducts first appear as invaginations of the dorsal coelomic epithelium. They penetrate the mesenchyme lateral to each Wolffian duct.<sup>7</sup> Two Müllerian ducts fuse to form the uterine canal and cervix at the tenth week of gestation.<sup>6</sup> The fused paramesonephric ducts form the epithelium and glands of the canal, and are covered by mesenchymal cells that comprise the muscles of the uterus and its peritoneum.<sup>8</sup> The solid tip of the paramesonephric ducts and urogenital sinus fuse at the end of the third month. Canalization of the uterine cavity, cervical canal and vagina is completed by the 22<sup>nd</sup> week of pregnancy. The endometrium develops by the 20<sup>th</sup> week of pregnancy from the internal lining of fused Müllerian segments.<sup>6</sup> Vaginal fornices and the lower vagina differentiate from paramesonephric cells and the urogenital sinus, respectively.<sup>5</sup> Therefore, we have concluded that the developmental problem in this case might have occurred between the 12<sup>th</sup> to 22<sup>nd</sup> weeks of pregnancy.

Mesonephric ducts are essential for normal Müllerian duct development. In both sexes the ureters develop from the mesonephric ducts. Abnormalities of the renal system and Müllerian ducts coexist.<sup>6</sup> In this case, however there was no developmental abnormality in the urinary system. Thus it could be concluded that mesonephric duct migration and regression occurred normally.

Expression of specific genes is important for molecular development of specific structures. It has been suggested that the initial patterning is stabilized by fusion and a reciprocal interaction between the endoderm and mesoderm adjacent to the structure. Specific gene expression up regulates factors in the mesoderm that subsequently determine the type of structure that should be created.<sup>5</sup> The temporal pattern of gene expression, special relationships of developing tissues, and cell-to-cell communications are important for normal structural development.<sup>9</sup> This case had no anomaly, except for the absence of a connection between the lower uterine segment with a normal looking portio vaginalis. If fusion of the Müllerian system and the surrounding mesoderm had not occurred normally in a critical time period, canalization could be stopped in that special segment.

Complex anomalies have been described that do not exactly match AFS classifications and cannot be fully explained by the theory of embryologic development.<sup>10,11</sup> We may consider this case to have either partial cervical atresia (internal os level) or agenesis of the lower uterine segment. Generally atresia may occur due to lack of recanalization and is most likely the result of vascular accidents, which may be caused by malrotation. As a result, blood supply to that region is compromised, resulting in the lack of development of a segment<sup>5</sup> which could have been the probable etiologic factor in this case.

Hysterectomy has been recommended for patients with functional uteri and cervical agenesis or dysgenesis. However successful attempts in recanalization of the uterine cervix by laparotomy<sup>12</sup> or assisted by laparoscopy<sup>13,14</sup> have been reported. Despite the absence of normal cervical secretions in these cases successful

pregnancies have been reported.<sup>15</sup> At present the management of uterine cervical anomalies is considered controversial.<sup>3</sup> It is recommended to carefully define the anatomical anomaly taking into consideration the patient's wishes, after which decisions should be made for final management. Creation of an epithelialized endocervical tract for the passage of menstrual flow makes it possible to save the uterus. A type of graft is usually used to prevent adhesion and obstruction of the canal. Creation of the canal and dissections may cause major trauma to adjacent structures and should be performed with great care. Assisted reproductive technologies can be considered for those cases who may present with infertility in the future. Abdominal delivery is recommended for all of these cases.

This case had an isolated atresia between a normal looking vaginal portion of the cervix and a functional uterine body. The type of anomaly in our case did not exactly match any of the suggested sub-classifications for cervical dysgenesis. We concluded that the developmental problem occurred between 12–22 weeks of gestation with a defect in segmental vertical fusion or canalization of the cervix. We theorize that probably the absence of an appropriate fusion between the Müllerian duct and its underlying mesoderm, as well as loss of cell-to-cell communication and special gene expressions during a critical time period, or a vascular accident was responsible for this anomaly.

## References

1. The American Fertility Society classifications of adnexal adhesions, distal tubal occlusion, tubal occlusion secondary to tubal ligation, tubal pregnancies, müllerian anomalies and intrauterine adhesions. *Fertil Steril.* 1988; **49**: 944 – 955.
2. Buttram VC Jr., Gibbons WE. Müllerian anomalies: a proposed classification (An analysis of 144 cases). *Fertil Steril.* 1979; **32**: 40 – 46.
3. Rock JA, Roberts CP, Jones HW Jr. Congenital anomalies of the uterine cervix: lessons from 30 cases managed clinically by a common protocol. *Fertil Steril.* 2010; **94**: 1858 – 1863.
4. American Society for Reproductive Medicine. Revised American Society for Reproductive Medicine classification of endometriosis: 1996. *Fertil Steril.* 1997; **67**: 817 – 821.
5. Sadler TW. *Langmans Medical Embryology*. 11th ed. Philadelphia: Lippincott Williams & Wilkins; 2010: 89 – 262.
6. Fritz MA, Speroff L. *Clinical Gynecologic Endocrinology and Infertility*. 8th ed. Philadelphia: Lippincott Williams & Wilkins; 2011: 121 – 156 and 341.
7. Rock JA, Jones III HW. *Te Linde's Operative Gynecology*. 10th ed. Philadelphia: Lippincott Williams & Wilkins; 2008: 539 – 584.
8. Anderson JR, Genadry R. Anatomy and embryology. In: Berek JS, ed. *Berek & Novak's Gynecology*. 14th ed. Philadelphia: Lippincott Williams & Wilkins; 2007: 75 – 127.
9. Park SY, Jameson L. Minireview: transcriptional regulation of gonadal development and differentiation. *Endocrinology*. 2005; **146**: 1035 – 1042.
10. Vallerie AM, Breech LL. Update in Müllerian anomalies: diagnosis, management, and outcomes. *Curr Opin Obstet Gynecol.* 2010; **22**: 381 – 387.
11. Wright KN, Okpala O, Laufer MR. Obstructed uteri with a cervix and vagina. *Fertil Steril.* 2011; **95**: 290.e 17 – 19.
12. Alborzi S, Momtahan M, Parsanezhad ME, Yazdani M. Successful treatment of cervical aplasia using a peritoneal graft. *Int J Gynecol Obstet.* 2005; **88**: 299 – 302.
13. Fedele L, Bianchi S, Frontino G, Berlanda N, Montefusco S, Borruoto F. Laparoscopically assisted uterovestibular anastomosis in patients with uterine cervix atresia and vaginal aplasia. *Fertil Steril.* 2008; **89**: 212 – 216.
14. Roberts CP, Rock JA. Surgical methods in the treatment of congenital anomalies of the uterine cervix. *Curr Opin Obstet Gynecol.* 2011; **23**: 251 – 257.
15. Deffarges JV, Haddad B, Musset R, Paniel BJ. Utero-vaginal anastomosis in women with uterine cervix atresia: long-term follow-up and reproductive performance. A study of 18 cases. *Hum Reprod.* 2001; **16**: 1722 – 1725.