

Case Report

A Rare Presentation of Pulmonary Sarcoidosis with Massive Hemoptysis

Masoud Nazemiyeh MD¹, Farid Rashidi MD¹, Reza Gharemoammadlou MD¹

Abstract

Sarcoidosis is a multisystem disorder with unknown etiology and is characterized by noncaseating granuloma in involved organs. Sarcoidosis frequency involves the lungs. Common presenting symptoms include cough, dyspnea and chest pain. Massive hemoptysis is a rare presentation in sarcoidosis. There are a few reports on massive hemoptysis in sarcoidosis.

We are reporting the case of a 24 year old man who presented with massive hemoptysis and normal lung parenchyma. The diagnosis was made with mediastinal lymph node biopsy.

Keywords: Hemoptysis, massive, sarcoidosis

Cite this article as: Nazemieh M, Rashidi F, Gharemoammadlou R. A rare presentation of pulmonary sarcoidosis with massive hemoptysis. *Arch Iran Med.* 2014; 17(1): 84 – 85.

Introduction

Sarcoidosis is a multisystem granulomatous disorder with unknown etiology. The pathologic hallmark of sarcoidosis is the noncaseating granulomatous in the involved organ.¹

The prevalence of this disorder is not exactly known. In most cases it involves patients between the ages of 10 and 40. Almost always it involves the lungs.² The common presenting symptoms are cough, dyspnea, and chest pain. In rare cases it may present with massive hemoptysis.³

We report a 24 years old man with sarcoidosis who presented with massive hemoptysis in early course of the disease who did not have any lung parenchymal involvement.

Case Report

A 24 year old non-smoker male presented to our pulmonary clinic with a chief complaint of hemoptysis for 3 days. He did not have dyspnea. In physical examination the chest was clear bilaterally, without crackle or wheeze. Chest-X ray was normal. Chest CAT scan showed para tracheal and sub carina lymphadenopathy (Figure 1) without mass and cavitations. CAT scan did not show any evidence for pulmonary embolism.

Laboratory investigation showed: ESR = 50 mm, white blood cell count = 6500 mic/lit, Hg = 13 g/dl, Htc = 45 % and, Angiotensin-converting enzyme (ACE = 89 IU/lit (normal value < 40 IU/lit)). PPD skin test and acid fast bacilli was negative and combs wright was 1/40. Blood Culture for gram stain and fungal infection were negative. Body Box test was normal (TLC = 108 %, FEV1/FVC = 89 %, FEV1 = 90 %, RV/TLC = 112 %). DLCO did not show any specific finding and was in the normal range

(DLCO = 90 %). Skin test and sputum culture for aspergillus were negative.

One day after admission, he developed a massive hemoptysis with more than 600 ml bleeding. Emergency rigid bronchoscopy was performed. Hemoptysis source was in the right lower bronchus. After bleeding was stopped, a fiberoptic bronchoscopy was done which did not show any endobronchial lesion. Bronchoalveolar lavage for acid fast bacilli was negative. CT-angiography was negative for A_V malformation.

The patient underwent mediastinoscopy and all paratracheal and sub carina lymph nodes were removed. Pathology examination showed many granulomas composed of epithelium cell, polynuclear giant cells and lymphocytes. Asteroid bodies were seen in cytoplasm of some of the giant cells (Figure 2).

Based on the pathologic findings and high ACE level, the diagnosis of Sarcoidosis was confirmed. The patient was put on prednisolone 60 mg/day, which was slowly tapered off. Six month later there was no symptom or evidence of recurrence. Chest X-ray and chest CT was normal after 6 months.

Discussion

Sarcoidosis occurs worldwide with higher incidence in the United States and Sweden. Its incidence appears to be lower in Asia.⁴ The exact etiology and pathogenesis of Sarcoidosis remains unknown.⁵ Most frequently it involves lungs and presents with symptoms such as cough, dyspnea, and chest pain. It can also cause fatigue, malaise, fever, and weight loss. Systemic symptoms are more common in older patients.⁶ Massive hemoptysis may occur only in less than 0.5 % of the patients.⁷ Hemoptysis can occur due to a necrotic sarcoidosis lesion, which could be treated with embolization or surgery.⁸ It can also occur due to micro aneurysm in bronchial arteries or shunt to the pulmonary vein.⁹ In one report major hemoptysis was found to be due to involvement of the upper respiratory tract and ulceration of nasopharyngeal granulomata.¹⁰ Development of clinical bronchiectasis in advanced stages can also cause hemoptysis.¹¹ In one report massive hemoptysis

Authors' affiliations: ¹Tuberculosis and Lung Disease Research Center, Tabriz University of Medical Sciences, Tabriz, Iran.

Corresponding author and reprints: Farid Rashidi MD, Tuberculosis and Lung Disease Research Center, Tabriz University of Medical Sciences, Imam Reza General Hospital, 29 Bahaman St, Tabriz, Iran. Tel: +98-411-334-4021, Fax: +98-411-637-0473, E-mail: fr2652@yahoo.com.

Accepted for publication: 19 November 2013

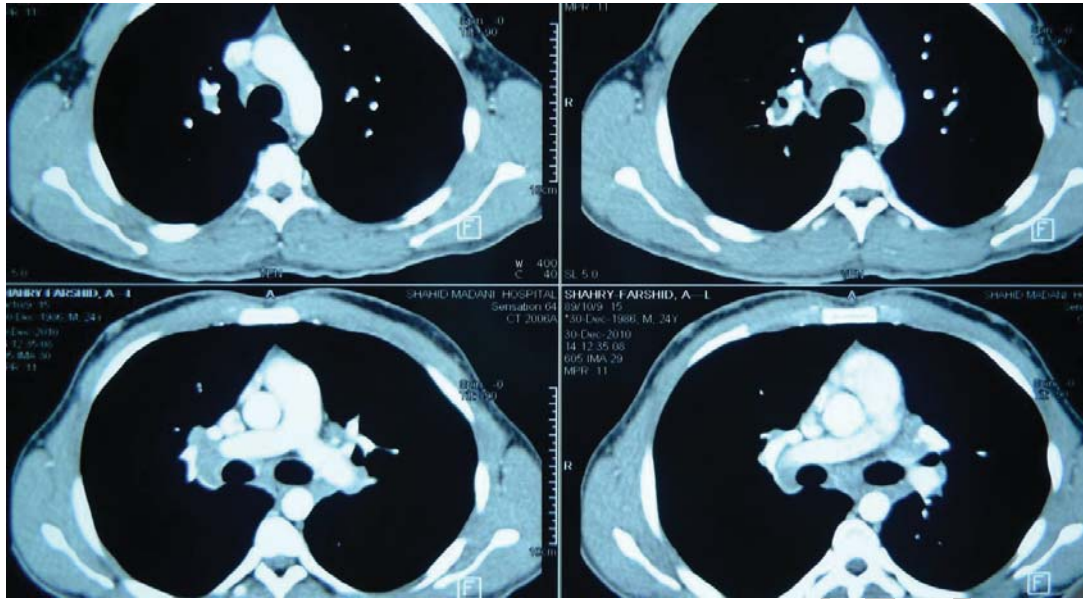


Figure 1. Para tracheal and sub carina lymphadenopathy

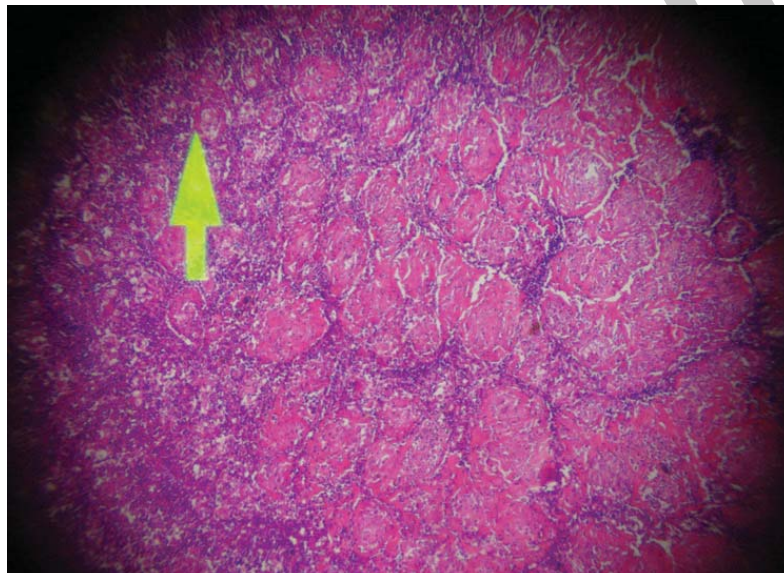


Figure 2. Granulomas composed of epithelium cell and polynuclear giant cells

was due to granulomatosis arthritis in small and medium size muscular arteries.¹²

Here we reported a case of sarcoidosis with massive hemoptysis with a favorable response to corticosteroid. Absence of lung parenchymal involvement and cavitation, differentiates our patient from other cases. We acknowledge the limitation in this report regarding the absence of lung biopsy and angiography to investigate granulomatosis arthritis and microaneurism.

Hemoptysis, especially massive hemoptysis in sarcoidosis is rare, by some patients may experience massive hemoptysis due to aspergilloma, bronchiectasis, microaneurism and rarely granulomatosis arthritis.

References

1. Iannuzzi MC, Rybicki BA, Teirstein AS. Sarcoidosis. *N Eng J Med*. 2007; **357**: 2153 – 2165.
2. Thomas KW, Hunninghake GW. Sarcoidosis. *JAMA*. 2003; **289**: 3300.
3. Sharma OP. Fatigue and sarcoidosis. *Eur Respir J*. 1999; **13**: 713.
4. Milman N, Hoffman AL. Childhood sarcoidosis: long-term follow-up.

5. Johnson LA, Edsall JR, Austin JH, Ellis K. Pulmonary sarcoidosis: could mycoplasma-like organisms be a cause? *Sarcoidosis Vasc Diffuse Lung Dis*. 1996; **13**: 38.
6. Chang JC, Driver AG, Townsend CA, Kataria YP. Hemoptysis in sarcoidosis. *Sarcoidosis*. 1987; **4**: 49 – 54.
7. Lemay V, Carette MF, Parrot A, Bazelly B, Grivaux M, Milleron B. Hemoptysis in sarcoidosis. Apropos of 6 cases including 4 with fatal outcome. *Rev Pneumol Clin*. 1995; **51**: 61 – 70.
8. Matsushima H, Oda T, Sato A, Yamamoto M, Hasejima N, Kadoyama C. A case of sarcoidosis complicated with reported hemoptysis. *Nihon Koryu Gakkai Zasshi*. 2009; **47**: 61 – 65.
9. Oluboyo PO, Awotedu AA, Onadeko BO, Ukoli CO. Sarcoidosis presenting with severe hemoptysis. *Trop Geogr Med*. 1987; **39**: 196 – 198.
10. Lewis MM, Mortelliti MP, Yeager H Jr, Tsou E. Clinical bronchiectasis complicating pulmonary sarcoidosis: case series of seven patients. *Sarcoidosis Vasc Diffuse Lung Dis*. 2002; **19**: 154 – 159.
11. Kudo M, Ito MR, Arita N, Oishi H, Miyazaki T, Suzauki J. An autopsy case of massive hemoptysis in systemic sarcoidosis with pulmonary granulomatous arteritis. *Ryumachi*. 2002; **42**: 807 – 814.
12. Kudo M, Ito MR, Arita N, Oishi H, Miyazaki T, Suzauki J. An autopsy case of massive hemoptysis in systemic sarcoidosis with pulmonary granulomatous arteritis. *Ryumachi* 2002; **42**: 807 – 814.