

Case Report

Leiomyosarcoma of the Inferior Vena Cava

Prashant S. Naphade MD DNB¹, Abhijit A. Raut MD¹, Priya Hira DNB², Pradip Vaideeswar MD³, Hemant Vadeyar MS⁴

Abstract

The purpose of this article is to present the CT features in five cases of pathologically verified Inferior vena cava (IVC) leiomyosarcoma. In this retrospective analysis, we reviewed CT features in 5 cases of clinicopathologically confirmed IVC leiomyosarcoma with respect to its location (infra renal, trans renal, supra renal), its extent (with or without involvement of renal vein, hepatic IVC with or without involvement of hepatic vein, right atrial & extra caval extension) and pattern of enhancement. CT guided biopsy was performed in four patients while the last patient underwent successful resection of the tumor.

Three male and two female patients (aged 45 to 72 years) were included in the study. Heterogeneously enhancing retroperitoneal mass involving IVC is the most common imaging feature. The intra and extra luminal extension was demonstrated excellently in all patients.

IVC leiomyosarcoma is a rare neoplasm often presenting very late with non-specific symptoms. Cross sectional imaging establishes the exact location and extension and plays a vital role in determining the resectability and planning the management.

Keywords: CT, IVC, leiomyosarcoma, retroperitoneal mass

Cite this article as: Naphade PS, Raut AA, Hira P, Vaideeswar P, Vadeyar H. Leiomyosarcoma of the inferior vena cava. *Arch Iran Med.* 2014; **17**(5): 383 – 387.

Introduction

Primary IVC leiomyosarcoma is a rare tumor arising from smooth muscle cells in the vessel wall and usually carries poor outcome. The presenting features range from non specific symptoms like pain in the abdomen to pedal edema and abdominal distension. Anecdotal reports of IVC leiomyosarcoma are available in English literature. However, only few of these reports have described the imaging features. Imaging is vital to demonstrate the origin, location within the IVC, and intra- and extra-luminal extension. This pictorial review illustrates the imaging features in five cases of pathologically verified IVC leiomyosarcoma and its role in surgical management.

Case Report

A total of five cases of IVC leiomyosarcoma (three male & two female) ranging in age from 45 to 67 years have been included in this pictorial review. A summary of age/sex, location, symptoms, intra/extracaval extension, involvement of common iliac/renal/hepatic veins/ right atrium, hepatorenal status and ascites is shown in Table 1.

Discussion

IVC leiomyosarcoma is the most common primary malignant tumor arising from the tunica media of IVC.¹ It occurs commonly in middle age females.² They are usually large in size at presenta-

tions and the symptoms can be non-specific like abdominal pain, distension, anorexia and weight loss. The location of tumor within the IVC is of paramount importance and based on this, IVC leiomyosarcoma is divided in 3 segments. Segment I - Below the level of renal vein, Segment II- Middle segment of IVC involving the renal and hepatic confluence and Segment III- Above the level of hepatic vein confluence.

Segment I tumors usually present with pedal edema and abdominal distension due to ascites. Segment II tumors can present with nephrotic syndrome due to involvement of renal veins and Budd Chiari syndrome due to hepatic vein thrombosis, either bland or tumor thrombus. Segment III involvement can be disastrous with a high risk of pulmonary embolism.

The IVC leiomyosarcoma usually grows slowly with intraluminal and/or extra luminal extension with extra luminal extension being more common.³ A predominantly hypodense retroperitoneal mass involving the IVC with heterogenous postcontrast enhancement is the most common imaging presentation. Central necrosis can be seen in the tumor. The predominant intraluminal spread of leiomyosarcoma present as a homogeneously enhancing mass lesion along the course of IVC. Multiplanar CT with sagittal and coronal reconstructions excellently reveals the craniocaudal extent of IVC leiomyosarcoma and determines the involved segment of IVC. IVC leiomyosarcoma occurs most commonly in segment II which also has the most favorable prognosis.⁴

Detection of leiomyosarcoma extension in renal, hepatic and common iliac veins alters the surgical management and can be demonstrated excellently on the contrast enhanced CT. Expansion of the involved vein and heterogeneous post contrast enhancement differentiate leiomyosarcoma extension and bland thrombus. Localized infiltration by leiomyosarcoma can occur in psoas and duodenum with or without encasement of aorta. Slow growth of tumor with IVC allows sufficient time for the development of collaterals, most commonly pericaval, paraaortic, perisplenic and abdominal wall collaterals.⁵

Surgical resection with tumor free margins is the only curative

Authors' affiliations: ¹Department of CT/MRI, E.S.I.C. hospital, Mumbai, India, ²Department of Radiology, SevenHills hospital, Mumbai, India, ³Department of Radiology, KEM hospital, Mumbai, India, ⁴Department of Pathology, KEM hospital, Mumbai, India, ⁵Department of Surgery, Kokilaben hospital, Mumbai, India.

Corresponding author and reprints: Prashant S. Naphade MD DNB, Department of CT/MRI, E.S.I.C. hospital, Andheri east, Mumbai, India.
Tel: +91-9920914963, E-mail: prashant.nafade@gmail.com.

Accepted for publication: 27 February 2014

Table 1. Summary of demographics and imaging findings in inferior vena cava leiomyosarcoma

Age/Sex/ Segment involved	Symptom	Morphology	Infiltration	Intra(I)/ Extra(E)	RV/HV/RA/IV	Liver	Kidney	Collaterals	Ascites
72/F Segment I, II	Pain/ distension abdomen pedal edema- 3 months	Heterogeneous enhancement, central necrosis	Encasing aorta, right renal vein and ureter with loss of fat planes between psoas and mass	E-I	Right RV and IV tumor thrombus HV-normal	Multiple metastasis	Right kidney- delayed nephrogram and HN	pararenal	+++
62/M Segment I, II	Backache – 2months	Heterogeneous peripheral enhancement, central necrosis	Infiltration into right psoas and posterior wall of duodenum Encasement of right renal hilum and ureter	E-I	Right RV- thrombosed HV-normal IV-normal	Normal	Right kidney- delayed nephrogram and HN	Perisplenic and pararenal	-
57/M All 3 segments	Pedal edema, distension, ascites – 4months	Heterogeneous enhancement, no necrosis	---	I	Right RV- thrombosed HV-non filling RA-normal Right IV extension	Congestive hepatomegaly	Normal	Multiple collaterals around kidney	+++
70/M All 3 segment	Abdominal distension, pain in back	Heterogeneous mass with neo vascularity	---	I	Both IV/Left RV Tumor thrombus HV-normal	Congestive hepatomegaly	Left kidney- delayed nephrogram	Retroperitoneal	+++
45/F Segment II,III	Distension/ pain abdomen, pedal edema	Heterogeneous mass	---	I	HV- Thrombosed RV-normal	Congestive hepatomegaly	Normal	Retroperitoneal	+++

RV: renal vein; HV: hepatic vein; RA: right atrium; IV: iliac vein; HN: hydronephrosis.

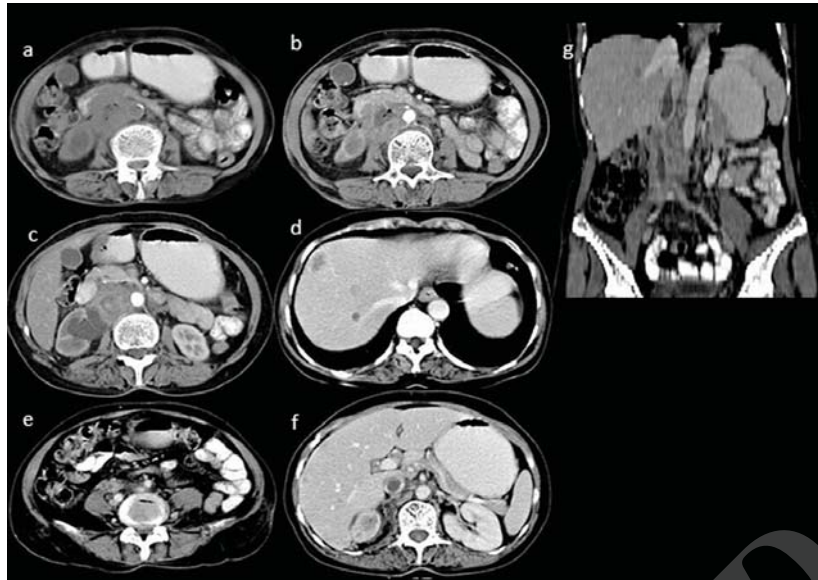


Figure 1. A 72-year female presented with pain in abdomen, distension of abdomen and pedal edema over a period of 3 months. Plain axial CT scan of abdomen; **a)** Reveals a predominantly hypodense mass lesion involving the IVC. Contrast enhanced CT scan reveals; **b)** Heterogeneous enhancement of the caval mass with central necrosis. The mass is seen infiltrating the posterior wall of third part of duodenum. Encasement of aorta is also seen; **c)** The mass lesion is encasing the right renal hilum and proximal ureter causing moderate dilatation of pelvicalyceal system of right kidney; **d)** Multiple hypodense metastatic foci are seen in the liver. All three hepatic veins are patent; **e)** Right common iliac vein thrombosis. Postcontrast axial; **f)** Coronal multiplanar reconstruction ; **g)** Reveal a hypodense non enhancing bland thrombus in the transhepatic IVC.

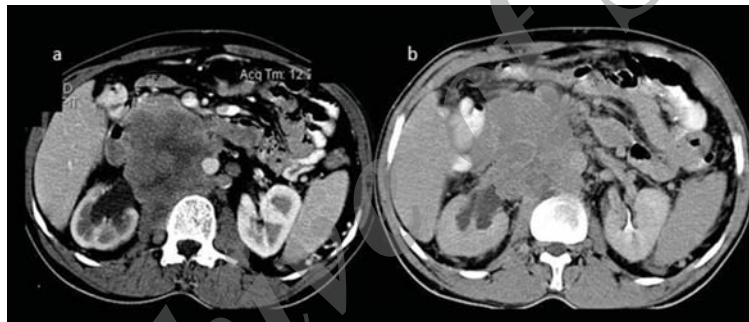


Figure 2. A 62-year male presented with backache for a period of 2 months. Postcontrast axial CT scan; **a)** Reveals a heterogeneously enhancing centrally necrotic tumor involving the segment II of IVC. The tumor infiltrates the posterior wall of duodenum and encases the abdominal aorta. Postcontrast axial CT; **b)** Reveals the sarcoma encasing the right renal hilum. Tumor thrombus is also seen involving the right renal vein. The excretion of contrast by the right pelvicalyceal system is delayed. Perisplenic collaterals are also seen.

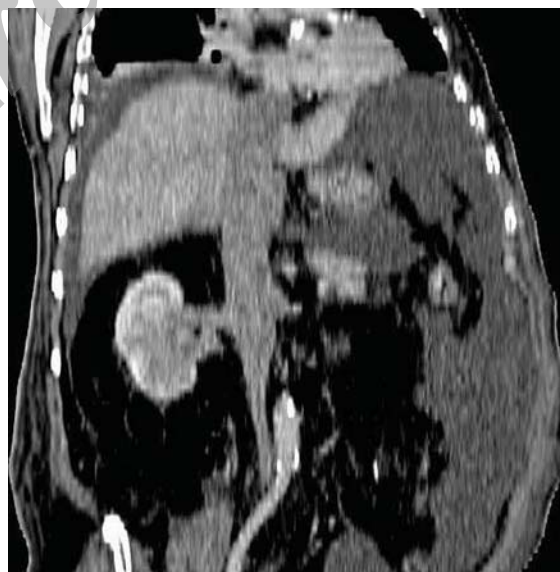

Figure 3. A 57-year male presented with distension of abdomen and pedal edema since 4 months. Coronal multiplanar reconstruction reveals a predominant endoluminal spread of IVC leiomyosarcoma involving all 3 segments of IVC. Extension of tumor thrombus is seen along the right renal vein associated with moderate ascites.

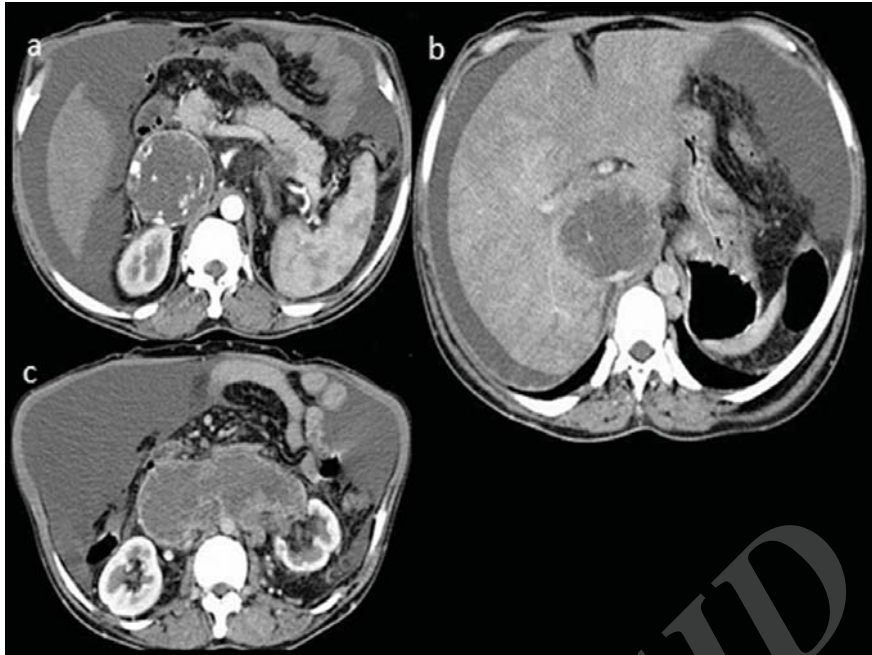


Figure 4. A 70-year male complains of abdominal distension and back pain. **a)** Arterial phase axial CT scan reveals neovascularity within IVC leiomyosarcoma; **b)** Venous phase axial CT scan reveals congestive hepatomegaly due to transhepatic IVC leiomyosarcoma; **c)** tumor thrombus extending in the left renal vein.

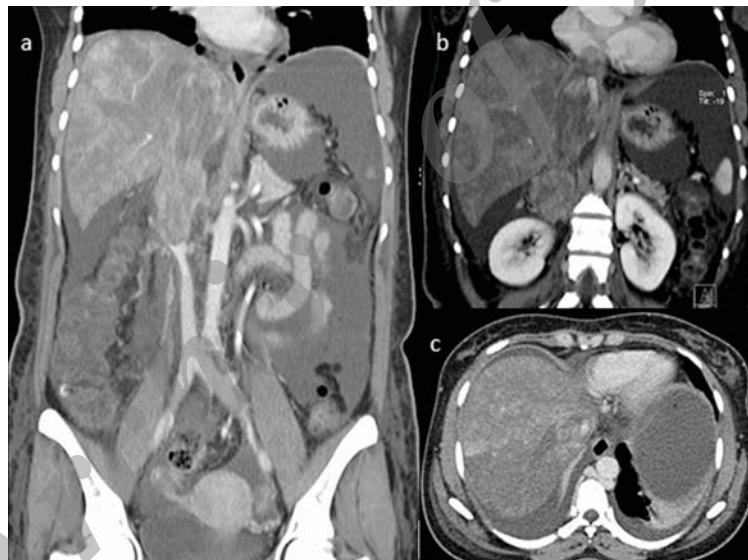


Figure 5. A 45-year female presented with pain and distension of abdomen. **a)** Coronal multiplanar reconstruction in venous phase reveals a heterogeneously enhancing mass lesion in the segment II of IVC, congestive hepatomegaly and massive ascites; **b)** Extension of leiomyosarcoma is seen in the right atrium; **c)** Post contrast axial image reveals bland thrombus in right hepatic vein and heterogeneous enhancement of liver.

treatment for IVC leiomyosarcoma.⁶ Recurrence due to incomplete removal of tumor is common.⁷ The surgical management depends upon the level of IVC involved, extension in the adjacent organs, presence of collaterals and metastasis. Primary repair of IVC can be performed if a small segment of IVC is involved. Caval ligation may suffice in segment I sarcoma if adequate collaterals have developed. Reconstruction of IVC with renal vein reconstruction should be performed in cases with segment II sarcoma.⁸ Segment III sarcoma with right atrial extension will need immediate surgical resection to avoid massive pulmonary embolism. Segment II sarcomas has favorable prognosis while Segment III involvement has the worst prognosis. Thus, feasibility of surgical resection as well as prognosis is guided by the segment of

involved IVC.

IVC leiomyosarcoma usually presents with non-specific symptoms. The possibility of IVC leiomyosarcoma should be considered whenever a heterogeneously enhancing retroperitoneal mass is seen along the course of IVC. Contrast enhanced CT with coronal and sagittal reconstructions accurately detect the origin, intra/extra luminal extension of sarcoma and metastasis. This helps in planning the surgical therapy and determining the prognosis.

References

1. Nayyar R, Panda S, Saini A, Seth A, Chaudhary SK. Leiomyosarcoma of inferior vena cava involving bilateral renal veins: Surgical challenges and reconstruction with upfront saphenous vein interposition

- graft for left renal vein outflow. *Indian J Urol.* 2010; **26(3)**: 438 – 440.
2. Reddy VP, Vanveldhuizen PJ, Muehlebach GF, Dusing RW, Birkbeck JP, Williamson SK, et al. Leiomyosarcoma of the inferior vena cava: a case report and review of the literature. *Cases J.* 2010; **3**: 71.
 3. Sheth S, Fishman EK. Imaging of the inferior vena cava with MDCT. *AJR Am J Roentgenol.* 2007; **189(5)**: 1243 – 1251.
 4. Mingoli A, Cavallaro A, Sapienza P, Di Marzo L, Feldhaus RJ, Cavallari N. International registry of inferior vena cava leiomyosarcoma: analysis of a world series on 218 patients. *Anticancer Res.* 1996; **16(5B)**: 3201 – 3205.
 5. Swaminathan TS, Srinivasaraman Govindarajan, Anand T, Senthilku-
mar AR. Leiomyosarcoma of the inferior vena cava: An uncommon cause of inferior vena caval obstruction. *Indian Journal of Surgery.* 2005; **67(3)**: 152 – 155
 6. Ceyhan M, Danaci M, Elmali M, Ozmen Z. Leiomyosarcoma of the inferior vena cava. *Diagn Interv Radiol.* 2007; **13(3)**: 140 – 143.
 7. Dew J, Hansen K, Hammon J, McCoy T, Levine EA, Shen P. Leiomyosarcoma of the inferior vena cava: surgical management and clinical results. *Am Surg.* 2005; **71(6)**: 497 – 501.
 8. Abisi S, Morris-Stiff GJ, Scott-Coombes D, Williams IM, Douglas-Jones AG, Puntis MC. Leiomyosarcoma of the inferior vena cava: clinical experience with four cases. *World J Surg Oncol.* 2006; **4**: 1.

Archive of SID