

## Case Report

# Advanced Stage Ovarian Juvenile Granulosa Cell Tumor Causing Acute Abdomen: A Case Report

Recep Bedir MD<sup>1</sup>, Afşin Rahman Mürtezaoğlu MD<sup>1</sup>, Ahmet Salih Calapoğlu MD<sup>2</sup>, İbrahim Şehitoğlu MD<sup>1</sup>, Cüneyt Yurdakul MD<sup>1</sup>

## Abstract

Ovary juvenile granulosa cell tumors (JGCT) are rare sex cord-stromal tumors that are most commonly encountered in prepubertal girls. These tumors can be of the adult type (95%) and juvenile type (5%). The main causes of complaint are abdominal distention and abdominal pain. Definitive diagnosis is confirmed by histopathological and immunohistochemical examinations. A 10-year old girl presented with massive abdominal distention, acute abdomen findings and ascites. Abdominopelvic magnetic resonance imaging showed masses with multiple cysts and solid components in the left ovary. Tumor markers were normal, but serum estradiol level was elevated. The patient underwent mass resection with left salpingo-oophorectomy and total omentectomy. Final histopathological diagnosis was JGCT. We herein report an extremely rare case of advanced stage JGCT causing massive ascites and acute abdomen.

**Keywords:** Advanced stage, juvenile granulosa cell tumor, ovary,

**Cite this article as:** Bedir R, Mürtezaoğlu AR, Calapoğlu AS, Şehitoğlu İ, Yurdakul C. Advanced stage ovarian juvenile granulosa cell tumor causing acute abdomen: A case report. *Arch Iran Med.* 2014; **17(9)**: 645 – 648.

## Introduction

Granulosa cell tumors (GCT) are rare tumors constituting only 1% – 2% of all ovarian malignancies. These tumors are originated from sex-cord stroma and divided into adult and juvenile forms. The adult type is the dominant type, constituting 95% of cases. JGCT are more rarely seen (5%) and generally appear in the first two decades of life.<sup>1-3</sup> Since JGCT are hormone active ovarian tumors, they can be determined early due to the signs of estrogen secretion. Clinically, owing to hormonal changes, pseudo puberty praecox, vaginal bleeding and irregular menstruation are commonly reported while virilisation and hirsutism are rare symptoms. Other common symptoms also include abdominal mass and pain.<sup>1,4</sup> These tumors are usually diagnosed at Stage I, but some cases are diagnosed at an advanced stage. Unfortunately it is not easy to determine their clinical behavior at the beginning. Local recurrence and metastasis demonstrate their malignancy potential.<sup>5</sup>

Herein we report, a 10-year-old girl patient admitted with acute abdominal symptoms and diagnosed with an advanced stage JGCT, by means of its histopathological and immune-histochemical findings.

## Case Report

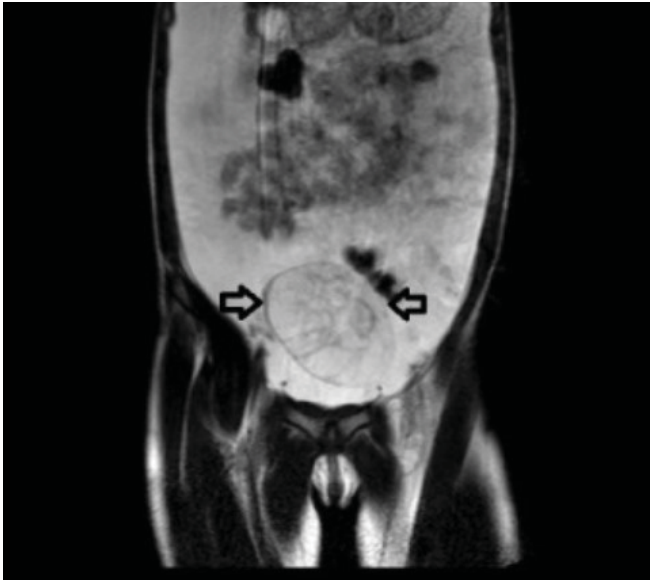A 10-year-old girl patient has been admitted to the emergency

department with a progressive abdominal distention and pain for 10 days. In the emergency department, the pediatric surgeon has examined her. In her physical examination, the abdominal region was highly distended and acute abdominal signs were observed. In abdominal ultrasonographic assessment, there was a solid lesion with a dimension of approximately 77 × 90 mm, elongating from the pelvic midline through the left half, with regular borders involving hypo-echoic, and heterogeneous cystic degenerated regions. Presence of widespread free fluid with a dense content, resulting in distension was observed in the abdomen. Magnetic resonance imaging (MRI) of the abdomen was done. In T2 weighted axial sliced sections, a mass with the dimension of approximately 76 × 87 × 75 mm, involving multiple cystic and solid components located superior of the uterus (starting from left ovary and radiating through the abdominal midline) was reported. Free fluid accumulation in the abdomen was also reported (Figure 1). In preoperative period, the levels of the tumor markers in patient serum including  $\alpha$ -feto protein (AFP), Carcino-Embriogenic Antigen (CEA),  $\beta$ -Human Coryonic Gonodotropin ( $\beta$ -hCG), CA-125 were normal, while CA19-9 level was slightly elevated [44.18 U/ml (N: 0 – 37)]. On the other hand, serum estradiol level was elevated to 2031 pg/ml (N: 11 – 44). During the operation of the patient, a frozen section of the tumor was assessed by a pathologist. The result of consultation from pathology department was reported as suspicious for malignancy since the mass was perforating the ovarian capsule and spreading through omental tissues. Due to this report, left salpingo-oophorectomy and total omentectomy was performed in the patient and approximately 4 liters of peritoneal fluid were evacuated. In the macroscopic evaluation, on the surface section of left salpingo-oophorectomy material that had the tuba uterine above, a gray- white colored tumoral mass with the dimensions of 9 × 5 × 2 cm, involving cystic and solid components that had perforated the ovarian capsule was observed (Figure 2).

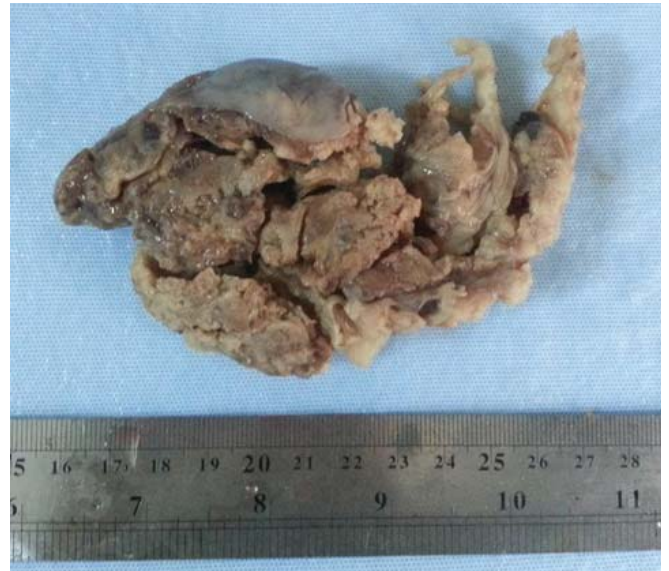**Authors' affiliations:** <sup>1</sup>Recep Tayyip Erdogan University of Medical Faculty, Pathology Department, Rize, Turkey, <sup>2</sup>Recep Tayyip Erdogan University of Medical Faculty, Pediatric Surgery Department, Rize, Turkey.

**Corresponding author and reprints:** Recep Bedir MD, Recep Tayyip Erdogan University of Medical Faculty, Pathology Department, Rize, Turkey. Tel: +904642130491, Fax: +904642170364, Mobile: +905057331695, E-mail: bedirrecep@gmail.com, afsinmurtezaoğlu@hotmail.com.

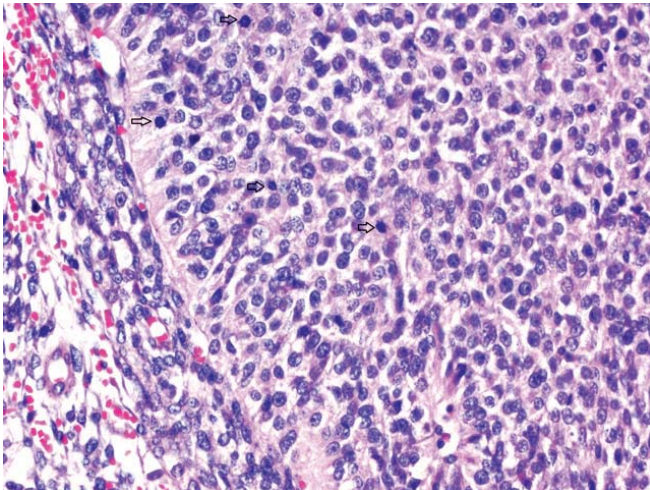
Accepted for publication: 20 June 2014



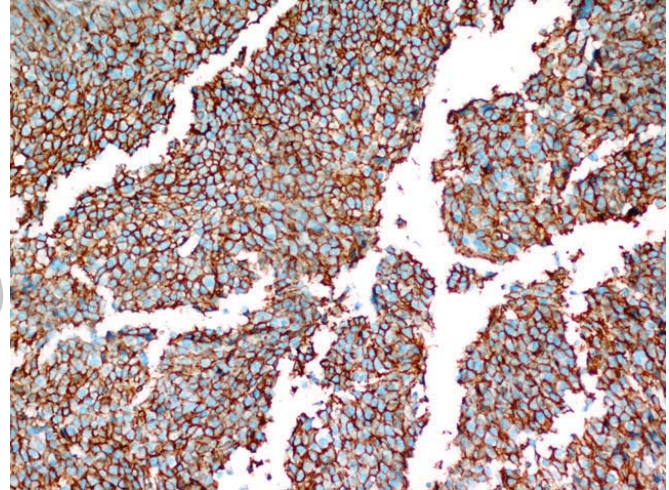
**Figure 1.** In T2 weighted axial sliced sections in MRI, mass appearance (arrows) with multiple cystic and solid components on the superior of uterus and free fluid accumulation in abdomen.



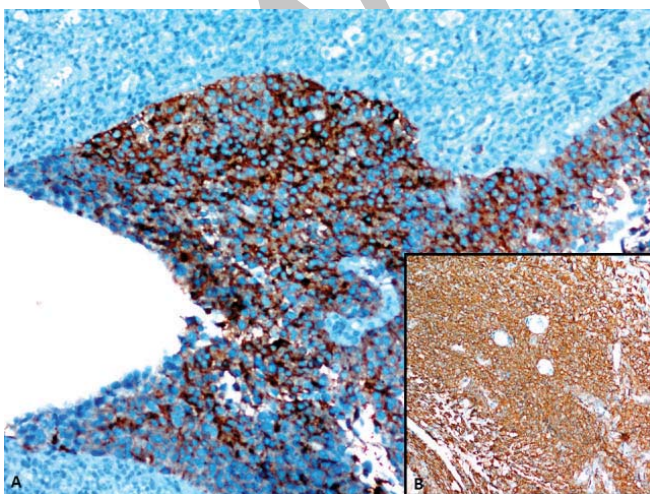
**Figure 2.** A gray/white colored tumoral mass involving cystic and solid components, that has perforated the ovarian capsule



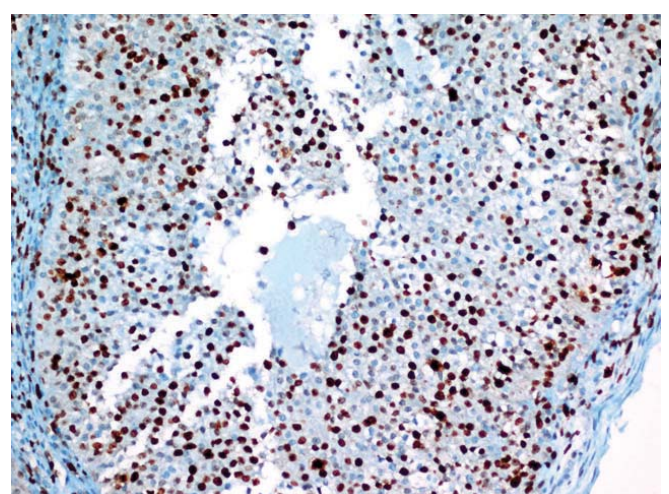
**Figure 3.** The tumor formed by atypical cells in uniform appearance with oval/rounded nuclei and scant cytoplasm with mitotic activity (arrows) (H&E, x400)



**Figure 4.** Diffuse membranous staining of neoplastic cells with CD99 (x200)



**Figure 5. A)** Positive staining of neoplastic cells with inhibin (x200); **B)** Diffuse positive staining of neoplastic cells with calretinin (x100)



**Figure 6.** High Ki-67 proliferation index of neoplastic cells (x200)

In the microscopic evaluation, inside the tumor involving solid and cystic components, there were micro-macrofollicular lesions and pseudopapillary projections in some locations. The tumor cells were having hyperchromatic nucleus and narrow cytoplasm. They were also relatively uniform in appearance (Figure 3). Clearly increased mitotic activity (mean IBBA 5 – 6 units), slight pleomorphism in some places and focal necrosis were attracting attention. In immunohistochemical examination, positively staining for CD99, inhibin, and calretinin were determined, (Figure 4 & Figure 5). In other immunohistochemical evaluations, while smooth muscle actinine (SMA), S-100, vimentin, CD56, Pan-CK and P53 were positive, NSE, GFAP, desmin, synaptophysin and EMA were negative. On the other hand, in tumor, Ki-67 proliferation index was quietly elevated (> 50%), (Figure 6). When immunohistochemical and morphological findings were evaluated together, the case was diagnosed with juvenile granulosa cell tumor. In omental sections, complete tumoral infiltration was observed. Since tumoral cells were observed in cytological evaluation and cellular block of peritoneal fluid, it was regarded as stage IIIB according to the FIGO staging system. Chemotherapy has been started for the postoperative treatment of the patient.

## Discussion

Sex-cord stromal tumors constitute for the 5% – 8% of ovarian malign neoplasms. On the other hand, JGCT (representing the 5% of all GCT) are different with their characteristic, histopathological features, and hormonal activities. Juvenile GCT is generally reported in prepubertal girls and usually result in pseudo praecox.<sup>1</sup> Juvenile GCT is typically related to isosexual development; pigmentation in breast areola, enlargement of breast, vaginal bleeding and enhancement in pubic hair development. Rarely, virilisation signs, including clitoral enlargement, hirsutismus, deepened voice, menstrual irregularities and amenorrhea can be seen due to the increased androgen hormone secretion.<sup>6</sup> However, in rare cases, abdominal distension, pain and ascite formation can be seen without the typical clinical features or it can present with acute abdomen due to torsion or rupture of tumor. In our case, signs of an acute abdomen, abdominal distension and ascite formation were present.

Generally JGCT are diagnosed in stage I level. In this stage, surgical treatment alone is enough and the prognosis is quite good. On the other hand, in advanced stages of JGCT, the prognosis is worse due to their more aggressive behavior and rapid progression. However, since most of the reported cases in the literature are in early stages and only a few JGCT in advanced stages are reported, its prognosis is controversial. In general, GCT is a tumor characterized by low malignancy potential and high survival rates, that can show local spread and late recurrence.<sup>2</sup> Although some morphological features that can be helpful in determining prognosis of GCT are revealed, this subject is still not clear. Especially increased Ki-67 proliferation index and p53 positivity were studied in the determination of prognosis. According to Costa, et al. increased Ki-67 proliferation index and p53 positivity were determined to be associated with a worse prognosis especially in JGCT.<sup>7</sup> In our case, in accordance with the literature, increased Ki-67 proliferation index (> 50%) and p53 positivity were observed.

There is no specific serum marker of JGCT. Among laboratory findings, only elevated serum estradiol level is an important finding. Though in some patients, elevation in both progesterone and

testosterone levels is observed. However, follicle stimulating hormone (FSH) and luteinizing hormone (LH) levels are usually normal.<sup>6</sup> By determining AFP and  $\beta$ -HCG levels, ovarian germ cell tumors can be excluded. Inhibin is a peptide hormone secreted by ovarian granulosa cells and its effects are regulated by FSH secretion. In both adult and juvenile types, increased serum inhibin levels may be established and after operation these values may return to normal.<sup>1</sup> In our case, serum AFP and  $\beta$ -HCG levels were normal while CA19-9 was slightly increased, and estradiol was absolutely increased. However serum inhibin level could not be studied in this case, since it was not present in our laboratory.

The golden standard method in JGCT diagnosis is histopathological evaluation, which is required for definitive diagnosis. Among the histopathological findings are:

1. Diffuse or macrofollicular pattern
2. Rare Call-Exner bodies
3. Luteinisation into granulosa and theca cells
4. Hyperchromatic and atypical nuclei
5. Common mitotic figures.

In our case, granulosa cells in uniform appearance with nuclear atypia, and common mitotic activities as well as macro and microfollicular lesions were observed in some locations. Fresh bleeding areas, cystic degeneration signs and focal necrosis in some places were present in the tumor. Call-Exner bodies were observed in a number of foci. In immunohistochemical evaluation, the most helpful parameters in the diagnosis are CD99, inhibin- $\alpha$  and calretinin.<sup>7</sup> Deavers, et al. reported that in diagnosis of JGCT, inhibin- $\alpha$  and calretinin are the markers with the highest sensitivity.<sup>8</sup> They determined inhibin- $\alpha$  with higher sensitivity than calretinin. CD99 is a marker preferred in differentiation of JGCT from low differentiated carcinomas of ovary since it reacts with normal sertoli and granulosa cells. Vimentin, SMA and S-100 are other immunohistochemical markers that help to confirm the diagnosis. In our case, in accordance with the literature, diffuse staining with CD99, inhibin- $\alpha$ , calretinin, SMA, S-100 and vimentin were observed.

In treatment of JGCT, surgery is the most important method. According to the FIGO, most of the JGCT are unilateral, capsulated and generally in stage IA, IB or IC. In treatment, unilateral oophorectomy or salpingo-oophorectomy is adequate and the prognosis is quite good. In advanced stages of JGCT, clinical picture is more aggressive with remissions, relapses or death. In treatment of advanced-stages JGCT (Stage II-IV), tumor and metastases should be extracted by cytoreductive surgery. During surgery, frozen section should be made to assess the nature and diffuseness of the tumor. In advanced disease, total omentectomy, resection of metastatic lesions on intestinal and peritoneal surfaces, unilateral/bilateral oophorectomy or salpingo-oophorectomy with/without hysterectomy as well as pelvic and paraaortic lymph node dissections should be performed as required.<sup>1,6</sup> In the studies of International Gynecology and Obstetrics Federation, it has been determined that more than 90% of patients diagnosed with stage I disease and treated with surgery alone survive. In advanced JGCT, prognosis is worse and after surgery, chemotherapy is recommended.<sup>6</sup> According to Hirakawa, et al. adding palliative radiotherapy to the treatment may be beneficial if abdominal mass and ascite are present, especially in progressing JGCT recurrences.<sup>9</sup> In our case, since malignancy suspicion was high in frozen sections, left salpingo-oophorectomy together with total omentectomy without

lymph node dissection was performed. In order to conserve the fertility of patient, total abdominal hysterectomy plus bilateral salpingo-oophorectomy were not carried out. The patient took chemotherapy postoperatively and in her six months follow-up, there was still no sign of recurrence or metastasis.

In conclusion, advanced-stage JGCT presented with acute abdominal signs, especially in young girls, should be considered in the differential diagnosis of aggressive ovarian tumors. In preoperative diagnosis, both the radiological evaluations and the increased levels of serum estradiol should alert for JGCT. However, the exact diagnosis can only be made with histological and immunohistochemical investigations.

## References

1. Ashnagar A, Alavi S, Nilipour Y, Azma R, Falahati F. Massive ascites as the only sign of ovarian juvenile granulosa cell tumor in an adolescent: a casereport and a review of the literature. *Case Rep Oncol Med.* 2013; **2013**: 386725.
2. Aybathli A, Kaplan PB. Advanced stage juvenile granulosa cell tumor of the ovary detected shortly after term pregnancy. *Turkish Journal of Oncology.* 2010; **25**: 157 – 160.
3. Adachi T, Sato H, Nakayama S, Shimizu S, Matsui H, Nakabayashi M. Primary amenorrhea due to juvenile granulosa-cell tumor of the ovary: A casereport. *J Obstet Gynaecol Res.* 2012; **38**: 597 – 600.
4. Schumer ST, Cannistra SA. Granulosa cell tumor of the ovary. *J Clin Oncol.* 2003; **21**: 1180 – 1189.
5. Kalfa N, Philibert P, Patte C, Ecochard A, Duvillard P, Baldet P, et al. Extinction of FOXL2 expression in aggressive ovarian granulosa cell tumors in children. *Fertil Steril.* 2007; **87**: 896 – 890.
6. Wang Y, Wang W, Xu C, Huang X, Zhong L, Kang X, et al. Childhood ovarian juvenile granulosa cell tumor: a retrospective study with 3 cases including clinical features, pathologic results, and therapies. *J Pediatr Hematol Oncol.* 2011; **33**: 241 – 245.
7. Costa MJ, Walls J, Ames P, Roth LM. Transformation in recurrent ovarian granulosa cell tumor: Ki-67 (MIB-I) and p53 immunohistochemistry demonstrates as possible molecular basis for the poor histopathologic prediction on clinical behavior. *Hum Pathol.* 1996; **27**: 274 – 281.
8. Deavers MT, Malpica A, Liu J, Broaddus R, Silva EG. Ovarian sex-cord-stromal tumors: an immunohistochemical study including a comparison of calretinin and inhibin. *Mod Pathol.* 2003; **16**: 584 – 590.
9. Hirakawa M, Nagai Y, Yagi C, Nashiro T, Inamine M, Aoki Y. Recurrent juvenile granulosa cell tumor of the ovary managed by palliative radiotherapy. *Int J Gynecol Cancer.* 2008; **18**: 913 – 915.

Archive of SID