

## Original Article

# Combination Therapy of Infantile Hemangioma with Pulsed Dye Laser with Topical Propranolol: A Randomized Clinical Trial

Amir Hooshang Ehsani MD<sup>1</sup>, Pedram Noormohammadpoor MD<sup>1</sup>, Mona Abdolreza MD<sup>1</sup>, Kamran Balighi MD<sup>1</sup>, Zaynab Arianian MD<sup>1</sup>, Soroush Daklan MD<sup>1</sup>

## Abstract

**Background:** The combination of pulsed dye laser (PDL) and topical propranolol are used with variable effectiveness for the treatment of infantile hemangiomas (IH), particularly for superficial lesions.

**Objective(s):** The aim of this study was to investigate whether the therapeutic efficacy of prescribing topical propranolol along with PDL was superior to PDL therapy alone in the treatment of IH.

**Methods:** A total of 19 patients with IH were recruited to the study. Among them, nine patients were treated with PDL, 3 sessions 4 weeks apart, and 10 patients underwent PDL treatment alongside with topical propranolol for 12 weeks. The therapeutic efficacies of each regimen were assessed by comparing photographs of skin lesions before and after the treatment based on the cessation of the lesion growth, reduction in the lesion size, and lightening of the lesion color.

**Results:** No side-effect was reported by the parents. Among nine patients in PDL group, only two (22%) had excellent clearance, one (11%) had good, three (30%) had weak, and three (30%) had no responses. On the other hand, among 10 patients who were treated with both the PDL and topical propranolol, five (50%) showed excellent responses and five (50%) displayed good responses. Statistical data analysis with Mann-Whitney test revealed a significant difference in the clinical response between two treatment groups.

**Conclusion:** The combination of PDL and topical propranolol seem to be a safe and effective therapy, and results in better clinical responses in the treatment of IH than PDL therapy alone.

**Key words:** Infantile hemangioma, pulsed dye laser, topical propranolol

**Cite this article as:** Ehsani AH, Noormohammadpoor P, Abdolreza M, Balighi K, Arianian Z, Daklan S. Combination Therapy of Infantile Hemangioma with Pulsed Dye Laser with Topical Propranolol: a Randomized Clinical Trial. *Arch Iran Med.* 2014; **17**(10): 657 – 660.

## Introduction

Infantile hemangioma (IH) is the most common vascular tumor in children.<sup>1</sup> It occurs commonly in Caucasian females, with increased prevalence in low-birth-weight infants.<sup>2</sup> Other risk factors include prematurity, multiple gestation, increased maternal age, and chorionic villus sampling.<sup>1</sup> Most frequently, IH undergoes a growth phase in the first 6–9 months of life, followed by a phase of regression in a period of 2–10 years.<sup>3</sup> Because of its self-regression, patients with uncomplicated IH lesions can be closely surveilled without any treatment.<sup>4</sup> However, some lesions may cause parents distress, disfigurements, and disabilities.<sup>2</sup> Additionally, there may be functional impairments of vital organs like airways and eyes, as well as ulceration, and bleeding.<sup>4</sup> In the presence of larger lesions, heart failure and hypothyroidism may occur.<sup>5</sup> In such cases, treatment modalities are primarily focused on prevention of further enlargement, fastening the involutions, and maintaining the normal organs functions.<sup>6</sup>

Pulsed dye laser (PDL) as a modality of treatment for IH shows some controversies, but it is widely accepted for management of ulcerated hemangiomas. Particularly, it has a better efficacy than for lesions more than 3 mm thickness.<sup>7</sup> Only limited number of

reports on the effectiveness of topical propranolol in the treatment of IH lesions exist.<sup>6,8,9</sup> In 2008, Bonafazi, et al., reported that administration of topical propranolol 1% in 6 infants with IH led to a significant clearance of superficial portions in 4 patients.<sup>10</sup>

Since comparative studies between topical beta-blockers and other modalities are lacking, this randomized clinical trial was carried out to assess the possible better therapeutic responses to topical propranolol combined with PDL than to PDL therapy alone in the treatment of IH lesions.

## Patients and Methods

### Patient selection

The present study was a single-blind randomized clinical trial carried out at Razi Hospital, Tehran, Iran. All infants with superficial and mixed IH referred to our center from January 2011 to July 2012 were recruited to the study if they were well-matched with the following inclusion criteria: less than 2 years of age, having hemangioma in non-vital parts of the body including eyelids, ears, lips, and nose, and no previous treatment with systemic steroids or other modalities over the last 3 months. Patients with congenital heart or renal disease were excluded from the study. Additionally, patients with no clinical response in the first 4 weeks of the treatment, and those presenting side effects like erythema, pruritus, bradycardia, and hypoglycemia were withdrawn from the study. All parents gave written informed consent to participate in the study.

Approval by the Ethics Committees of Tehran University of

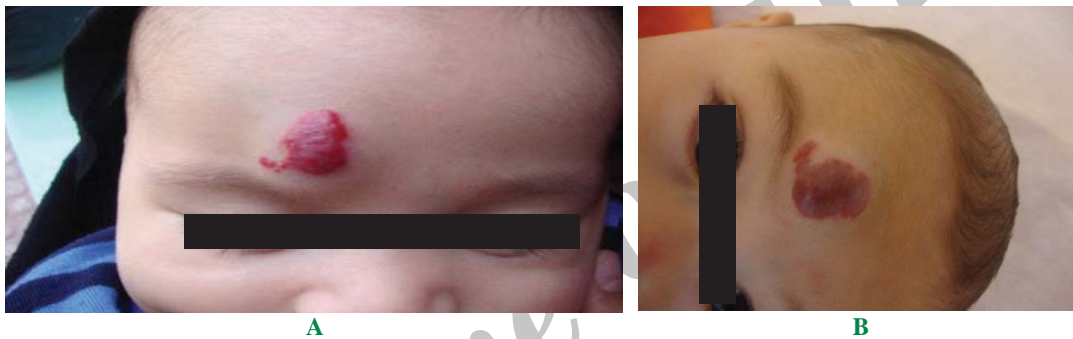
**Authors' affiliation:** <sup>1</sup>Razi hospital, Tehran University of Medical Sciences, Tehran, Iran.

**Corresponding author and reprints:** Mona Abdolreza MD, Razi Hospital, Tehran University of Medical Sciences, Tehran 1199663911, Iran.  
Tel: +98-21-55618989, E-mail: abdolreza@tums.ac.ir, Mona.abdolreza@yahoo.com  
Accepted for publication: 16 July 2014

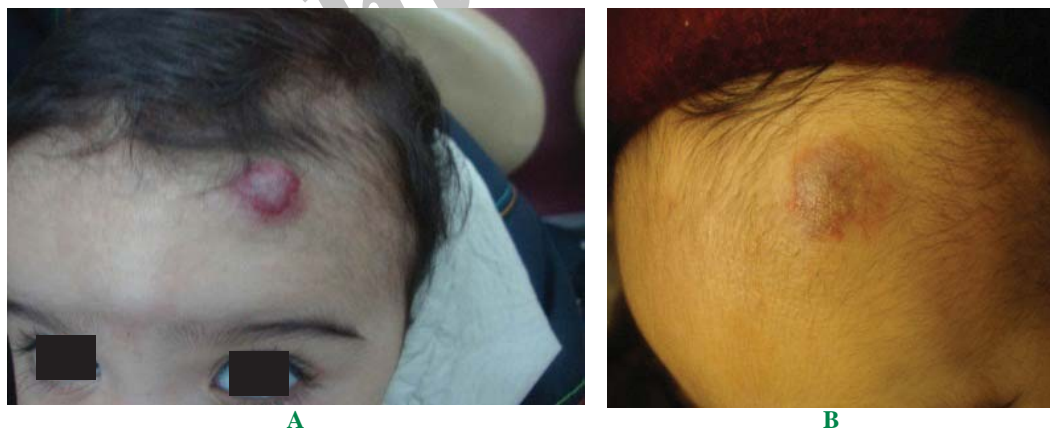**Table 1.** Basal clinical characteristics of the patients, the treatment regimens and outcomes.

Patients Number	Gender	Age (months)	Location of lesion	Treatment regimen	Improvement score
1	Male	6	Arm	PDL + Pro	4
2	Female	2.5	Hand	PDL + Pro	3
3	Female	2.5	Arm	PDL + Pro	4
4	Female	9	Forearm	PDL + Pro	3
5	Female	17	Mid-face	PDL + Pro	3
6	Female	11	Scalp	PDL + Pro	3
7	Female	3	Forehead	PDL + Pro	4
8	Female	6	Genitalia	PDL + Pro	4
9	Female	13	Scalp	PDL + Pro	3
10	Female	10	Cheek	PDL	2
11	Male	9	Forehead	PDL	1
12	Female	8	Chest	PDL	2
13	Female	13	Buttock	PDL	3
14	Female	13	Arm	PDL	4
15	Male	6	Genitalia	PDL	1
16	Female	8	Cheek	PDL	4
17	Female	9	Forehead	PDL	2
18	Female	6	Cheek	PDL + Pro	4
19	Female	4	Cheek	PDL	1

PDL = pulsed dye laser; PDL + Pro = pulsed dye laser and topical propranolol.



**Figure 1.** (A) A nine-month-old girl with an IH lesion on her forehead before PDL therapy. (B) The same patient after receiving three sessions of PDL therapy once every four weeks. No response to the treatment was observed, and the lesion even enlarged after the treatment course.



**Figure 2.** (A) A 9-month-old girl with an IH lesion on her forehead before the treatment. (B) The same patient after 16 weeks of combined PDL and topical propranolol therapy.

Medical Sciences was obtained and all Parents provided informed Consent. Before study set up we registered it in Iranian Registry of Clinical Trials, available at: URL: <http://www.irct.ir/> (Identifier: IRCT 201110137787N1).

#### Treatment protocols

A total of 19 patients with IH were recruited to the study, and randomly divided into two treatment groups using a randomized number table. Nine patients were treated with PDL (spot size 7 mm, fluence 12 J/cm<sup>2</sup>, pulse duration 1.5 ms, dynamic cooling

device 40/40), three sessions, once every 4 weeks, with 50% overlapped shuts. The number of shuts varied according to the size of lesions. In the other group, 10 patients were treated with the same PDL sessions together with topical propranolol 1%, applied twice a day in a thin layer onto the lesion for at least 12 weeks. A pediatric cardiologist warranted the use of topical propranolol in these patients after careful examinations. The topical propranolol was prepared by the hospital pharmacy as a lipid-based formulated ointment of propranolol hydrochloride 1%. Before initiation of the treatment, a photograph of the lesion demonstrating the location, color, and size of the lesion was taken. Patients were examined at 4, 8, 12, and 16 weeks of treatment course where parents were also enquired about the side effects from the medication and the degree of clinical improvements in terms of the lesions color, size, and protrusions. Additionally, serial photographs were taken from lesions at each visit.

#### Clinical evaluations

Clinical responses to the treatment regimens were evaluated with respect to the cessation of the growth, decreases in the size, and lightening of the color of lesions. The clinical improvements of IH lesions were quantified using a visual score system after comparing pre- and post-treatment lesion photographs by two dermatologists who were blind to treatment regimens. The visual scores were classified into four categories as follows: score 1, 0–25% improvement (no response); score 2, 25–50% improvement (poor response); score 3, 50–75% improvement (good response); and score 4, 75–100% improvement (excellent response).

#### Statistical analysis

Scores of clinical improvements following the treatments were analyzed using the Mann-Whitney U test. The IBM SPSS statistical software was used for data analysis. Chi-square and the student *t*-test were used for categorical and quantitative variables, respectively. Differences were considered significant if *P* values were less than 0.05.

## Results

All the 19 patients who were included to the study completed the treatment course. Table 1 shows the basal clinical characteristics of study subjects, the treatment regimen they received, and the outcome of the treatment. The IH lesions were located at the head and face (*n* = 10, 62.6%), the limbs (*n* = 5, 26.3%), the trunk (*n* = 2, 10.5%), and the genitalia (*n* = 2, 10.5%). The mean age ( $\pm$  standard deviation) in the PDL treatment group was  $8.9 \pm 2.9$  months and in the PDL and topical propranolol treatment group was  $7.6 \pm 4.8$  months. No statistically significant difference was observed between these two treatment groups with respect to the age (*P* = 0.5). Out of nine patients who were treated with PDL alone, seven (78%) were female and two (22%) were male. From the 10 patients treated with both the PDL and topical propranolol regimen, 9 (90%) were female and 1 (10%) was male. No significant difference in terms of gender (*P* = 0.58) was found between two treatment groups. Moreover, duration of the disease (lesion) did not significantly differ between two treatment groups (Mean ranks were 11.72 and 8.45 for PDL alone and PDL plus propranolol treatment groups respectively, *P* = 0.20). No significant correlation was found between the sizes of lesions and the clinical responses to the different treatment regimens (*P* = 0.77).

Parents in both groups reported no side effect from the prescribed medications. Clinical improvements in patients treated with PDL regimen alone were as follow: 2 patients (22%) had excellent improvements (75–100%), 1 (11%) had good (50–75%), 3 (30%) had poor (25–50%), and 3 (30%) had no (0–25%) clearance of the lesion. One of the three patients who had no clearance of the lesions, even showed enlargement of the lesion over the treatment course (Figure 1). One patient in this treatment group had ulcerated lesion, which displayed signs of recovery after two sessions of PDL therapy.

Treatment outcomes among the patients who received the combination of topical propranolol and PDL therapy were as follow: 5 patients (50%) showed excellent improvements (75–100%) and 5 (50%) showed good (50–75%) clinical responses (Figure 2). One patient in this group had an ulcerated hemangioma that showed complete recovery after one session of the joint therapy.

Statistical analysis of improvement scores with Mann-White U test revealed a significant difference between clinical responses and the different treatment regimens (Mean ranks were 6.94 in the PDL only group versus 12.75 in the joint PDL and propranolol group; *P* = 0.02). There was no significant difference between the clinical responses and the treatment regimens with respect to location of lesions (Mean ranks for lesions at different locations on the body surface: trunk, 25.7; head and face, 9.05; limbs, 13.40; and genitalia, 9; *P* = 0.40). Furthermore, no significant difference was found between clinical responses and different treatment regimens based on the duration of having the lesions (Mean ranks were 11.72 and 8.45 for the PDL alone and the combined PDL and propranolol treatment groups respectively, *P* = 0.20).

## Discussion

The use of PDL in the treatment of IH remains controversial, because of the natural course of the IH, limited depth of beam penetration, and higher risk of scarring and hypopigmentation in lesions treated with PDL. However, it is accepted for management of ulcerated hemangiomas, since it enhances re-epithelialization as well as diminishes pain, infection and bleeding.<sup>7,11</sup> PDL beams are absorbed mainly by hemoglobin in blood vessels<sup>7,11</sup> and cause changes in the levels of mediators involved in angiogenesis, including basic fibroblast growth factor, angiopoietin-2, and matrix metalloproteinase-9.<sup>12</sup>

To date, no clinical trial was performed to investigate the clinical responses of IH lesions treated with a joint PDL and topical propranolol therapy. In 2008, for the first time Léauté-Labrèze, et al., reported that oral propranolol may have therapeutic benefits in treatment of IH. Since then, a few number of case reports and series supported its effectiveness in treatment of IH.<sup>1,8</sup>

The underlying mechanism of propranolol action is still unknown, however, it may induce vasoconstriction, inhibit angiogenesis and stimulate apoptosis.<sup>5,9</sup> Topical propranolol was demonstrated to be effective and safe for the treatment of IH with little or no side effects.<sup>6,10,13</sup> Therefore, in this study we assessed the effect of administering a combination of topical propranolol and PDL in a group of patients with IH to investigate if it adds on the treatment outcome relative to the PDL therapy alone. In our study, 33% of patients treated with PDL alone showed significant clearance of their lesions (22% showed excellent and 11% showed good improvements). These results are in agreement with those obtained by other studies showing significant to complete clear-

ance of IH lesions in approximately 30% of study subjects.<sup>14,15</sup> However, we observed considerably better clearance of IH lesions when topical propranolol followed by PDL therapy. As 50% of lesions showed excellent responses and the remaining 50% displayed good responses. No poor response or enlargement of lesions was observed in patients treated with this protocol. These results are relatively consistent with clinical responses observed in patients treated with topical propranolol by Guangqi, et al., reporting that 57% of patients showed good responses, 33% showed partial responses, and 10% displayed no response.<sup>6</sup> In another study, the IH lesions regressed in 59% of patients and showed no growth in 26% and no response in 15%.<sup>13</sup> However, in our study all patients who received combined treatment showed 50–100% improvements. Similarly, in a study by Reddy, et al., 50% of patients with IH lesions treated with PDL and oral propranolol showed complete and 50% showed near-complete clearances, whereas 13% of patients who received propranolol alone achieved complete, 25% near-complete clearances and 63% achieved partial clearance.<sup>16</sup>

In our study, no side effects from the medication reported by the parents. Considering safety profile, propranolol is a nonselective beta blocker which causes hypoglycemia by its action on  $\beta_2$ -adrenoceptors and hides hypoglycemia related symptoms like tachycardia, anxiety and sweating via  $\beta_1$  blocking effects. It may also cause diarrhea, bronchospasm, seizure and other neurological symptoms.<sup>8</sup> *In vitro* experiments on human skin revealed that 10.4–36.6% of the dose of topical propranolol applied to the skin accumulate in the skin tissue and only a small amount (4.1–16.1%) of the dose entered the systemic circulation.<sup>17</sup> In rats, 24 hr after topical application of 200  $\mu$ L of 0.4% propranolol hydrochloride on 1 cm<sup>2</sup> of the dorsal skin, the maximum plasma concentrations of the drug was as low as  $25 \pm 5.0$  ng/mL.<sup>18</sup> However, it has been shown that 24 hr after the topical administration of propranolol, the drug concentrations in the eyelids and extraocular muscles were 0.4  $\mu$ g/g or higher, that may even exceed local periocular concentrations of the drug when it is orally or intravenously administered.<sup>19</sup>

In conclusion, it seems that using a combination of topical propranolol and PDL is a more effective and safe modality in the treatment of IH lesions. Further randomized controlled clinical trials with more patients are needed to confirm this claim.

## References

1. Callahan AB, Yoon MK. Infantile hemangiomas: a review. *Saudi J Ophthalmol*. 2012; **26**: 283 – 291.
2. Holland K, Drolet B. Infantile hemangioma. *Pediatr Clin N Am*. 2010; **57**: 1069 – 1083.
3. Chakkittakandiyil A, Phillips R, Frieden I. Timolol maleate 0.5% or 0.1% gel-forming solution for Infantile Hemangiomas: A Retrospective, Multicenter, Cohort Study. *Pediatr Dermatol*. 2012; **29**: 28 – 31.
4. Kim L, Hogeling M, Wargon O. Propranolol: useful therapeutic agent for the treatment of ulcerated infantile hemangiomas. *J Pediatr Surg*. 2011; **46**: 759 – 763.
5. Storch C, Hoeger P. Propranolol for infantile hemangioma: Insights into the molecular mechanisms of action. *Br J Dermatol*. 2010; **163**: 269 – 274.
6. Guangqi XU, Renrong LV, Zhongfang Z. Topical propranolol for treatment of superficial infantile hemangiomas. *J Am Acad Derm*. 2012; **67**: 1210 – 1213.
7. Stier M, Glick S, Hirsch R. Laser treatment of pediatric vascular lesions: port wine stains and hemangiomas. *J Am Acad Dermatol*. 2008; **58**: 261 – 285.
8. Ming M, Fan X, Su L. Propranolol for problematic head and neck hemangiomas: an analysis of 37 consecutive patients. *Int J Pediatr Otorhinolaryngol*. 2012; **76**: 574 – 578.
9. Awadein A, Fakhry MA. Evaluation of intralesional propranolol for periocular capillary hemangioma. *Clin Ophthalmol*. 2011; **5**: 1135 – 1140.
10. Bonifazi E, Colonna V, Mazzotta F. Propranololo negli emangiomi a rapida crescita. *Eur J Pediatr Dermatol*. 2008; **18**: 185 – 192.
11. Tay Y, Tan S. Treatment of infantile hemangiomas with the 595-nm pulsed dye laser using different pulse widths in an Asian population. *Lasers Surg Med*. 2012; **44**: 93 – 96.
12. Laquer V, Dao B, Pavlis. Immunohistochemistry of angiogenesis mediators before and after pulsed dye laser treatment of angiomas. *Lasers Surg Med*. 2012; **44**: 205 – 210.
13. Kunzi-Rapp K. Topical propranolol therapy for infantile hemangiomas. *Pediatr Dermatol*. 2012; **29**: 154 – 159.
14. Batta K, Goodyear H, Moss C. Randomized controlled study of early pulsed dye laser treatment of uncomplicated childhood hemangiomas: results of a 1-year analysis. *The Lancet*. 2003; **361**: 348 – 349.
15. Hohenleutner S, Badur-Ganter E, Landthaler M. Long-term results in the treatment of childhood hemangioma with the flashlamp-pumped pulsed dye laser: an evaluation of 617 cases. *Lasers Surg Med*. 2001; **28**: 273 – 277.
16. Reddy KK, Blei F, Brauer JA. Retrospective study of the treatment of infantile hemangiomas using a combination of propranolol and Pulsed Dye Laser. *Dermatol Surg*. 2013; **39**: 923 – 933.
17. Ademola J, Chow C, Wester R. Metabolism of propranolol during percutaneous absorption in human skin. *J Pharm Sci*. 1993; **82**: 767 – 770.
18. Mishra D, Garg M, Dubey V. Elastic liposomes mediated transdermal delivery of an anti-hypertensive agent: propranolol hydrochloride. *J Pharm Sci*. 2007; **96**: 145 – 155.
19. Hao J, Yang MB, Liu H. Distribution of propranolol in periocular tissues: a comparison of topical and systemic administration. *J Ocul Pharmacol Ther*. 2011; **27**: 453 – 459.

1. Callahan AB, Yoon MK. Infantile hemangiomas: a review. *Saudi J*