

Original Article

Long-Term Follow-up of Intra-articular Injection of Autologous Mesenchymal Stem Cells in Patients with Knee, Ankle, or Hip Osteoarthritis

Mohsen Emadedin MD^{1#}, Maede Ghorbani Liastani MD^{2#}, Roghayeh Fazeli MD¹, Fatemeh Mohseni MD¹, Reza Moghadasali PhD¹, Soura Mardpour MSc¹, Seyyedeh Esmat Hosseini BS¹, Maryam Niknejadi MD¹, Fatemeh Moeininia MD¹, Aslan Aghahosseini Fanni MSc¹, Reza Baghban Eslaminejhad PhD¹, Ahmad Vosough Dizaji MD^{1,2}, Narges Labibzadeh MD¹, Ali Mirazimi Bafghi MD¹, Hossein Baharvand PhD¹, Nasser Aghdami MD PhD¹

Abstract

Background: Osteoarthritis (OA) is a debilitating disease that typically affects a large number of the middle-aged and elderly population. Current treatment strategies have had limited success in these patients. This study aims to investigate the safety of treatment with autologous bone marrow (BM)-derived mesenchymal stem cells (MSCs) transplanted in patients with OA of the knee, ankle, or hip.

Methods: We enrolled 18 patients with different joint involvements (knee, ankle, or hip OA) and one was lost to follow-up. BM samples were taken from the patients, after which BM-derived MSCs were isolated and cultured. Each patient received one MSC injection. Patients were followed with clinical examinations, MRI and laboratory tests at 2, 6, 12, and 30 months post-transplantation.

Results: We observed no severe adverse events such as pulmonary embolism, death, or systemic complications. A limited number of patients had very minor localized adverse effects such as rash and erythema. There were no changes in liver function, hematology, or biochemistry analyses before and after cell therapy. There was no evidence of tumor or neoplastic changes in the patients during the 30-month follow-up period. All patients exhibited therapeutic benefits such as increased walking distance, decreased visual analog scale (VAS), and total Western Ontario and McMaster Universities OA Index (WOMAC) scores which were confirmed by MRI.

Conclusions: Our study has shown that injection of MSCs in different OA affected joints is safe and therapeutically beneficial. However, further studies are needed with larger sample sizes and longer follow-up periods to confirm these findings.

Keywords: Ankle osteoarthritis, autologous mesenchymal stem cell transplantation, hip osteoarthritis, knee osteoarthritis, safety

Cite this article as: Emadedin M, Ghorbani Liastani M, Fazeli R, Mohseni F, Moghadasali R, Mardpour S, Hosseini SE, Niknejadi M, Moeininia F, Aghahosseini Fanni A, Baghban Eslaminejhad R, Vosough Dizaji A, Labibzadeh N, Mirazimi Bafghi A, Baharvand H, Aghdami N. Long-Term Follow-up of Intra-articular Injection of Autologous Mesenchymal Stem Cells in Patients with Knee, Ankle, or Hip Osteoarthritis. *Arch Iran Med.* 2015; **18(6)**: 336 – 344.

Introduction

Osteoarthritis (OA) is a progressive, debilitating disorder that affects a large number of the elderly and middle-aged population.¹ In 2012, approximately 8 million people in the United Kingdom and 27 million in the United States were affected by OA.² Although current treatment strategies such as non-pharmacological, pharmacological, and surgical procedures² decrease symptoms and improve function, they do not affect cartilage destruction. It is well known that mesenchymal stem cells (MSCs) have the potential to proliferate and differentiate into cartilage and bone. In addition, MSCs are well recognized for their immunomodulatory and anti-inflammatory capabilities.³ Several studies have been performed on the safety and efficiency of MSCs in joints of animal models with OA.⁴⁻⁶

In 2008, a case series study reported intra-articular injection of

MSCs to be a safe treatment that lacked complications.⁵ In a second report, Davatchi, *et al.* emphasized the safety of this method. Their group examined the potential of cultured MSCs on four OA patients with a six-month follow-up after cell injection.⁶ Tumor formation and risk of infection were evaluated in 41 patients with knee OA who received MSC injections and were followed for 11 years. The results showed no tumor formation and the risk of infection was less than 0.1%.⁷ Another study that followed 213 patients undergoing intra-articular injection of cultured MSC cells for two years reported no neoplastic adverse events.⁸

Although there are studies of MSC injections in OA patients,^{8,9} additional studies should be performed in different locations other than the knee. This study has sought to determine the safety of intra-articular MSC transplantation in patients with OA of the knee, hip and ankle joints.

Materials and Methods

Patients

We conducted three separate studies according to the principles of the Declaration of Helsinki which were approved by the Ethics Committee of Royan Institute. This study was registered in NIH clinical trial site as NCT01207661 for OA of the knee, NCT01436058 for ankle OA and NCT01499056 for OA of the hip. An orthopedist examined 150 patients diagnosed with either

Authors' affiliations: ¹Department of Regenerative Biomedicine at Cell Science Research Center, Royan Institute for Stem Cell Biology and Technology, ACECR, Tehran, Iran. ²Department of Reproductive Imaging at Reproductive Biomedicine Research Center, Royan Institute for Reproductive Biomedicine, ACECR, Tehran, Iran.

Corresponding author and reprints: Nasser Aghdami MD PhD, Department of Regenerative Medicine at Cell Science Research Center, Royan Institute for Stem Cell Biology and Technology, ACECR, Tehran, Iran. Tel: +98 21 22306485, Fax: +98 21 22310406, E-mail: Nasser.Aghdami@RoyanInstitute.org.

These authors contributed equally in this work.

Accepted for publication: 20 May 2015

OA of one ankle (n = 40), hip (n = 40) or knee (n = 70) joint, who were between 18 and 65 years of age. We enrolled six patients per affected joint according to MRI images and antero-posterior X-rays of the affected joints. All patients in the three OA groups had moderate to severe disease at baseline (grades III, IV). Informed consent was obtained from all patients. Key exclusion criteria for study participants of all groups were the presence of diseases of the central nervous system and peripheral nerves; any end-organ damage such as organ failure, organ transplantation or cancer; uncontrolled diabetes or thyroid diseases; sensitivity to anesthesia or materials used in the culture process; respiratory diseases; and patients who were breast feeding or pregnant. All patients underwent clinical examinations that included kidney and liver assays, and completed the Visual Analog Scale (VAS) and Western Ontario and McMaster Universities OA Index (WOMAC). In addition, patients with hip OA completed the Harris Hip Score (HHS) and those with ankle OA completed the Foot and Ankle Outcome Score (FAOS).

Isolation and expansion of BM-MSCs

In the operating room, an oncologist aspirated 150 ± 5 mL of BM by puncturing both iliac crests under local anesthesia (2% lidocaine). Patients were sedated with intravenous (IV) midazolam (0.1 mg/kg) and fentanyl (25–50 mg). Mononuclear cells were aseptically isolated in clean room under a laminar safety cabinet Safe Flow 1.2 (JAL Tajhiz, Iran) which was specifically designed for this purpose and fulfilled the safety criteria.

We added BM aspirate to the same volume of phosphate-buffered saline-EDTA (PBS/EDTA; pH 7.2; 700-25, ClineMACS, Germany). Then, samples were loaded into a Lymphodex (D-61476, Inno-Train, Germany) and centrifuged at 1100 rpm for 20 minutes. Mononuclear cells (MNCs) were gently collected and counted with a nucleo-counter (Chemometec, USA). Afterwards, MNCs were washed with PBS-EDTA and plated at $5-10 \times 10^5$ cells/cm² in 150-cm² culture flasks that contained 25–30 mL of alpha modified eagle's medium (alpha MEM; 22571-020, Gibco, Germany) supplemented with 100 IU penicillin and 100 IU streptomycin (15070-063, Gibco, Germany), 10% Hyclon fetal bovine serum (SH30070.03, Thermo Scientific, USA) and 1% L-glutamine (25030-024, Gibco). Seven days after culture initiation, floating cells were removed by medium replacement. The attached cells were expanded in the culture as BM-MSCs and the primary cells were prepared for injection. Phase-contrast microscopy of the BM-MSCs culture demonstrated a low heterogeneous population of cells that were composed predominately of long, spindle-shaped cells. For each patient, the cells were characterized for immunophenotypic properties with expression of surface markers for MSCs. Prior to injection, the cells were tested for possible microbial contamination.

Flow cytometry

Phycoerythrin (PE)-conjugated CD105, CD44, CD73 (Becton Dickinson, USA) and fluorescein isothiocyanate (FITC)-conjugated CD90 (Dako) antibodies were used for expression of membranous antigens on BM-MSCs. Approximately 1×10^5 harvested cells were placed into the flow cytometry vials, washed with PBS (21600-051, Gibco) and centrifuged at 1500 g for 5 minutes. Next, antibodies were added to the cells and the mixture was allowed to incubate in dark for 30–45 minutes, after which they were washed with PBS. We used nonspecific mouse IgG1-FITC/

IgG1-PE and IgG2a-FITC as isotype controls. All samples were analyzed by flow cytometry (BD FACS Caliber, BD Biosciences, San Jose CA, USA) and Win-MDI 2.9 software.

Quality control tests

The quality control tests (QCT) were chosen in accordance with the recommendations for cell and tissue therapy promotion and validation tests of the Iranian Health Ministry Pharmacopoeia Commission and the Department of Health and Human Services Food and Drug Administration.

Samples for the microbial test

Microbial samples were taken from the BM aspirations, discarded fractions of the culture medium during the medium change, and the final products after cell harvest. Using an aseptic technique in a biological safety cabinet, the 2 mL samples were inoculated into the following culture bottles that contained: BACTEC plus Aerobic, Anaerobic and PEDS Plus/F Culture, and BACTEC MYCO/F Lytic. The bottles were loaded into a BACTEC 9120 continuous blood culture monitoring system (BD Company) per the manufacturer's instructions. The samples were incubated for a minimum of five days. Positive bottles were unloaded and used to create subcultures on the appropriate agar plates in a standard microbiologic laboratory.

Limulus amoebocyte lysate (LAL) gel clot assay

In order to detect the presence of any endotoxin in the final products, we used the limulus amoebocyte lysate (LAL) gel clot assay. This highly sensitive test can detect down to 0.125 endotoxin units (EU)/mL. In this test, the activated preclotting enzyme cleaves the coagulogen protein to form a gelatinous clot. The LAL kit was purchased from Lonza (N289-125) and measurements were performed according to the manufacturer's instructions. We added the LAL reagent to an equal volume of each sample and after 60 minutes of incubation, the formation of clots was determined. The samples were spiked with endotoxin (*E. coli* strain O55:B5) concentrations at half of the assay sensitivity (0.5 mL: 0.0625 EU/mL), at the assay sensitivity (1 mL: 0.125 EU/mL) and at double the assay sensitivity (2 mL: 0.25 EU/mL).

Mycoplasma detection

Mycoplasma contamination is one of the major problems in cell culture. Mycoplasmas are the smallest endosomal bacteria that can cause widespread contaminants reported in cell cultures. The nested Polymerase Chain reaction (PCR) is a rapid and sensitive technique for detecting Mycoplasma contamination. The DNA of each cell or supernatant was extracted using a QIAamp DNA Blood Mini Kit (51306, Qiagen, Hilden, Germany) according to the manufacturer's instructions. The presence of Mycoplasma was investigated using a PCR Mycoplasma Detection Set (#6601, Takara, Shiga, Japan). In the nested PCR method, two pairs of primers were used for two consecutive PCR Tests. In the first run of PCR was amplified the spacer region between the 16S and 23S mycoplasma rRNA, by the forward primer (5'-ACACCATGGGAGCTGGTAAT-3') and reverse primer (5'-CTTCATCGACTTTCAGACCCAAGGCAT-3'). The second run of nested PCR was then performed using a forward primer (5'-GTTCTTTGAAAACACTGAAT-3') that hybridized with a conservative sequence for the spacer region and a reverse primer (5'-GCATCCACCAAAAACACTCT-3') that hybridized with 23S

rRNA. Depending on the different *Mycoplasma* species, the product length of the first PCR ranged from 369 to 681 bp and from 145 to 237 bp for the second PCR. For each cell, we used 200-900 ng of extracted DNA or 10 µg/mL of medium collected from the cells that had been cultured for at least three days as PCR templates. To ensure the absence of contamination, each PCR experiment included negative controls. Taq polymerase from AxiTaq (GX090250, Inno-Train), and a thermocycler (Applied Biosystems Veriti™ Thermal Cycler) were used. PCR products were analyzed using agarose gel electrophoresis (2% and 3% for the first and the second PCR runs, respectively) and erythro-gel staining.

Karyotyping analysis

BM-MSCs of primary passages were analyzed based on their proliferation using PHA (10576-015, Gibco) within 15–17 hours. Adherent cells were treated with colcemid (15210-057, Gibco) and detached using 0.125 µL trypsin (Gibco BRL, Grand Island, NY, USA). Cells were treated with 0.075 mol/L KCl in a 37°C water bath after which they were fixed and spread onto slides. Air-dried slides were stained with freshly prepared 10% Giemsa stain in a Gurr buffer (Invitrogen, Carlsbad, CA, USA) for 30 minutes. Before printing out each karyotype and counting each chromosome by writing a number on each sister chromatid pair, the slides were observed under a light microscope at 10 and 100× magnifications.

Preparation of cells for injection

Primary cultures of MSCs were washed with PBS and trypsinized with trypsin/EDTA (0.05%; 25300-062, Gibco). The cells were suspended in normal saline and loaded into 10-mL sterile syringes. For each patient, approximately 5×10^5 cells/kg/bw were prepared and transported to the hospital in a box maintained at a temperature of approximately 0–4°C. Cell injections were performed under fluoroscopy guide in hip and ankle OA patients. In the knee OA group, intra-articular injections were performed without the fluoroscopy guide.

Evaluations

Patients were selected according to inclusion and exclusion criteria. Each patient received a single intra-articular MSC injection in the affected joint. All patients were evaluated before injection and at 2, 6, 12, and 30 months intervals after treatment. VAS, WOMAC, HHS, and FAOS were used for the clinical assessments. The WOMAC consists of 24 items, which are divided into three subscales: pain, stiffness and physical function. The global score has a range of 0 (no symptoms) to 96 (worst symptoms) when standardized in the range of 0 to 100 mm. A lower score indicates a better status.

The FAOS consists of five subscales: pain, activities of daily living (ADL), function in sport and recreation [sport (rec)], and foot and ankle-related quality of life (QOL). When answering the questionnaire, only the previous week was taken into consideration. Standardized answer options were given (% Likert boxes) and each question was assigned a score from 0 to 4.

The HHS was developed for assessing the result of hip surgery and intended to evaluate various hip disabilities and methods of treatment. The HHS score has a maximum of 100 points, as follows: pain (44 points), function (47 points), range of motion (5 points), and deformity (4 points). HHS total score of <70 is considered poor, 70–80 is fair, 80–90 is good and 90–100 is excellent.

No normative values are available.

Evaluation of adverse effects

Patients from all three groups underwent clinical examinations and a number of tests were performed. Clinical examinations assessed both local adverse effects; those limited to the joints, and systemic adverse effects. We also assessed for the presence of any severe adverse effects such as tumor formation or neoplastic changes, infections, pulmonary embolisms, leukemia, or anaphylactic shock in the transplanted patients. The tests included a complete blood count with differential (CBC-Diff), erythrocyte sedimentation rate (ESR), C-reactive protein (CRP), coagulation tests (PT, PTT, INR), liver, kidney and thyroid function tests, urine analysis and urine cultures. Tumor and neoplastic changes were evaluated by MRI. Local adverse events such as swelling and joint tenderness, joint range of motion, skin rash and erythema were also evaluated. All tests were performed over 30 months of follow-up at specific intervals (baseline, 6, 12, and 30 months after MSCs transplantation). Specified physicians obtained all data related to adverse effects.

Radiological evaluations

All analyses were performed on a 1.5 Tesla MRI unit (VB33D Vision Plus; Siemens, Erlangen, Germany) using an extremity coil for signal reception and delivery. FS 3D FLASH MRI parameters were defined as TR/TE: 60/11 and FA: 40°; gradient-echo images were obtained in axial, sagittal and coronal planes. Wide slice thickness was 65 mm in the axial, 70 mm in the sagittal and 80 mm in the coronal planes.

Slice thickness was 2.5 mm for axial, sagittal and coronal planes. An imaging area of 25 cm, a spatial resolution of 1.2×1 mm and a matrix of 256×192 were used to minimize the artifacts. Sequence imaging time was 6.28 minutes and fat suppression prolonged the total scan time by approximately 3 minutes. MRIs of the knees, ankles and hips were obtained from all patients at baseline and at 6 and 12 months after MSCs transplantation. Antero-posterior and lateral X-ray views were taken from all joints in all patient groups before transplantation.

Statistical analysis

We have reported data as mean \pm standard deviation (SD). Data were analyzed using SPSS 16.0. Statistical analysis was performed with paired *t*-test. An alpha value of $P < 0.05$ was regarded as statistically significant.

Results

Patient treatment

This study enrolled 18 patients with either OA of an ankle ($n = 6$), hip ($n = 5$), or knee ($n = 6$) joint. One patient from the hip OA group was lost during follow-up because of fractures in the lower limb due to an accident. Demographic characteristics of the OA patients are shown in Table 1.

Patients were recruited between August 2010 and January 2011 and treated between September 2010 and February 2011. There were no systemic adverse events observed during MSCs transplantation or the 30-month follow-up period after transplantation in patients. Local adverse effects such as mild erythema and skin rash were seen in a few patients (Supplementary Table 1). There were no changes observed in laboratory data at baseline and af-

ter MSCs injection at the post-treatment evaluation. During the 30-month follow-up, there were no severe adverse events and none of the patients were lost to follow-up because of any adverse events. Tumor or neoplastic changes were not seen in the MRIs of patients during 30 months of follow-up. Most patients expressed satisfaction with the results of this treatment.

Expansion and characterization of MSCs

The following cell parameters were used for patients (n = 17): BM volume: 150 ± 5 mL; number of MNCs obtained (ankle: $1.2 \pm 0.7 \times 10^9$; hip: $0.7 \pm 0.5 \times 10^9$; and knee: $0.3 \pm 0.0 \times 10^9$); expansion time: 1–1.5 months; and number of MSCs for the ankle: $5.7 \pm 4.7 \times 10^7$, hip: $2.4 \pm 0.4 \times 10^7$, and knee: $5.5 \pm 0.8 \times 10^7$. The cells were suspended in Ringer-lactate at 5×10^6 cells/mL. Viability was reported as $96.6 \pm 1.1\%$ for the ankle, $94.4 \pm 2.7\%$ for the hip, and $97.1 \pm 1.4\%$ for the knee. After 7 to 10 days in culture, the cells became relatively homogeneous. The cells had a fibroblastic appearance when approaching confluence until use (Figure 1, Supplementary Table 2). The antigenic profile conformed to the International Society for Cellular Therapy criteria for MSCs.¹⁰

The clinical and imaging outcomes of all patients

Significant improvements were noted in walking distance for all groups of OA patients during the 30 months of follow-up ($P < 0.008$, Figure 2). All OA groups showed improvements in the total WOMAC score and sub-scores that included stiffness as well as pain and physical functions (Figure 2). The mean VAS scores

of all OA patients decreased six months after treatment (47.0 vs. 17.0; $P < 0.000$). Although this improvement continued for 12 months (47.1 vs. 17.1, $P < 0.002$), VAS scores increased after twelve months in all OA groups (Figure 2).

Knee OA group

The mean walking distance in the knee OA group was 88.3 ± 93.2 m at baseline which increased significantly at months 6 (400.0 ± 427.2 m) and 30 (1222.0 ± 1032.9 m) after MSC treatment. The total WOMAC score reduced in these patients at months 6 (45.5 vs. 72.7; $P < 0.008$), 12 (47.2 vs. 72.7, $P < 0.002$), and 30 (43.4 vs. 72.7; $P < 0.05$) after treatment compared with baseline (Figure 3A). Mean WOMAC stiffness sub-scores were (31.2 vs. 10.6; $P < 0.05$) at six months after treatment. They were 14.5 ± 0.4 at 12 months and 20.0 ± 1.1 at 30 months after treatment (Figure 3A). There was a reduction in WOMAC physical function sub-scores at months 6 (46.5 ± 16.4 ; $P < 0.05$) and 12 (48.7 ± 8.2 ; $P < 0.05$) after cell therapy (Figure 3A).

Hip OA group

The means walking distances in hip OA patients were 1170 m at 6 and 1000 m at 30 months after MSC treatment compared with 370 m at baseline (Figure 3B).

The mean total WOMAC scores were 27.9 ± 20.8 at 6 months, 26.3 ± 11.6 at 12 months and 29.1 ± 18.9 at 30 months after treatment compared to the baseline score of 45.2 ± 10.0 (Figure 3B). The WOMAC pain sub-scores were at months 6 (25.0 ± 24.2)

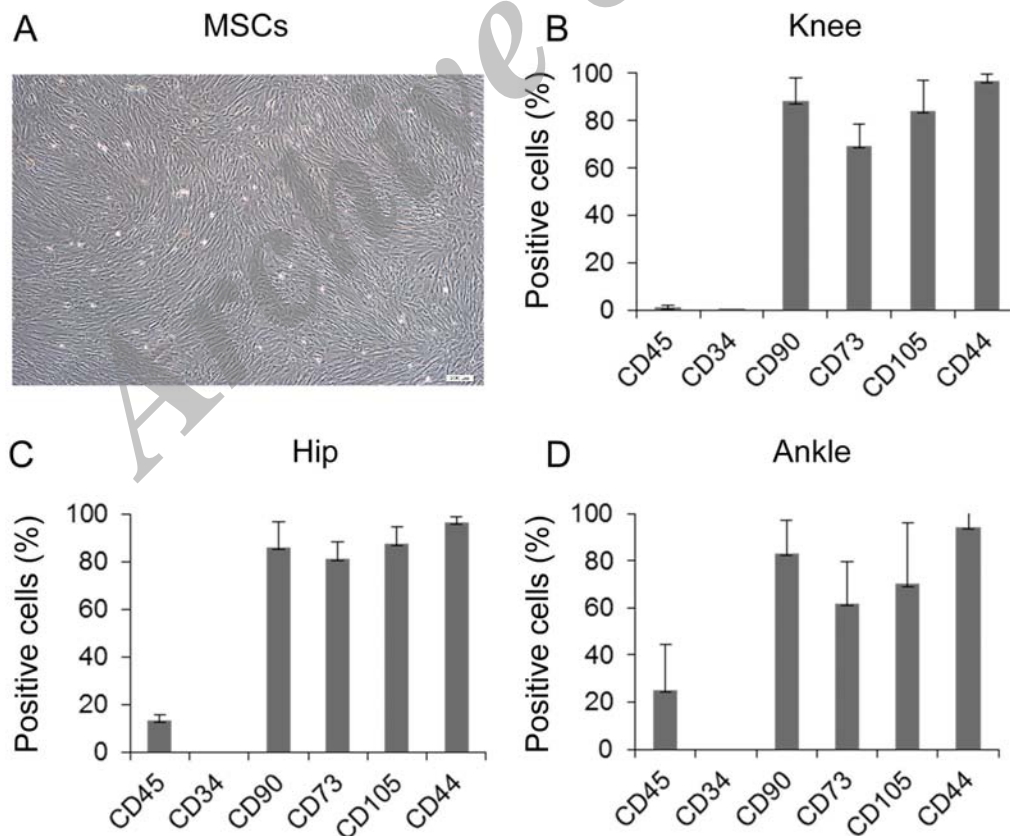


Figure 1. Morphological feature and immunophenotype characterization of mesenchymal stem cells (MSCs).

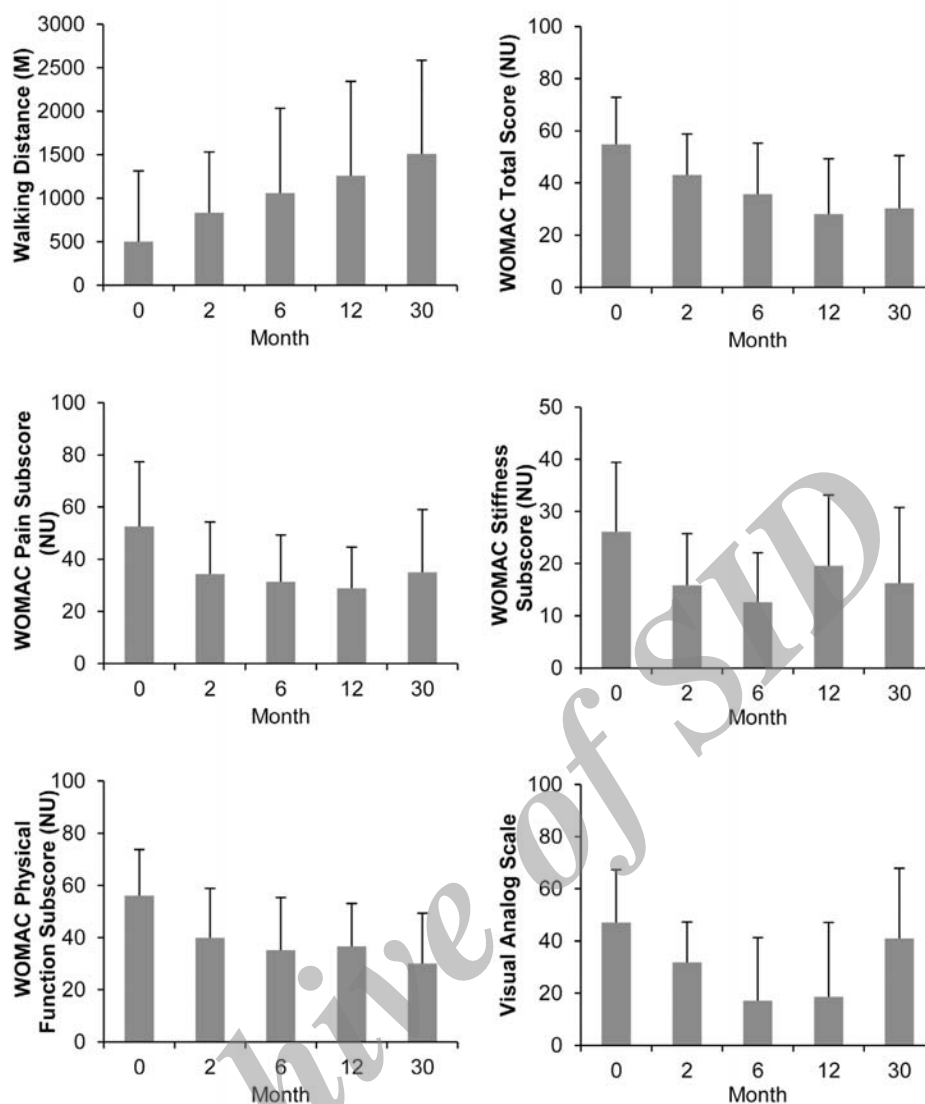


Figure 2. Change from baseline after cell transplantation in evaluated clinical parameters in all osteoarthritis (OA) patients.

and 12 (15.9 ± 14.4) after treatment, and were (24.7 ± 14.1) at 30 months following treatment (Figure 3B). Mean WOMAC stiffness sub-scores were 15.0 ± 13.6 in these patients at 6 months after treatment. They were 28.12 ± 19.4 at 12 months and 25.0 ± 17.6 at 30 months after treatment (Figure 3B). The WOMAC physical function sub-scores were 28.4 ± 18.6 at 6 months and 30.8 ± 11.2 in twelve and 30.8 ± 20.6 thirty months after treatment. The baseline score was 52.7 ± 11.2 (Figure 3B). We observed improvement in HHS scores at 6 months (79.8 ± 16.8 ; $P < 0.05$) after MSC treatment compared with baseline (57.0 ± 3.2 ; Figure 3B).

Ankle OA group

The mean walking distance in ankle OA patients was 1625 m at 6 months and 2333 m at 30 months after MSC treatment compared to 1010 m at baseline (Figure 3C).

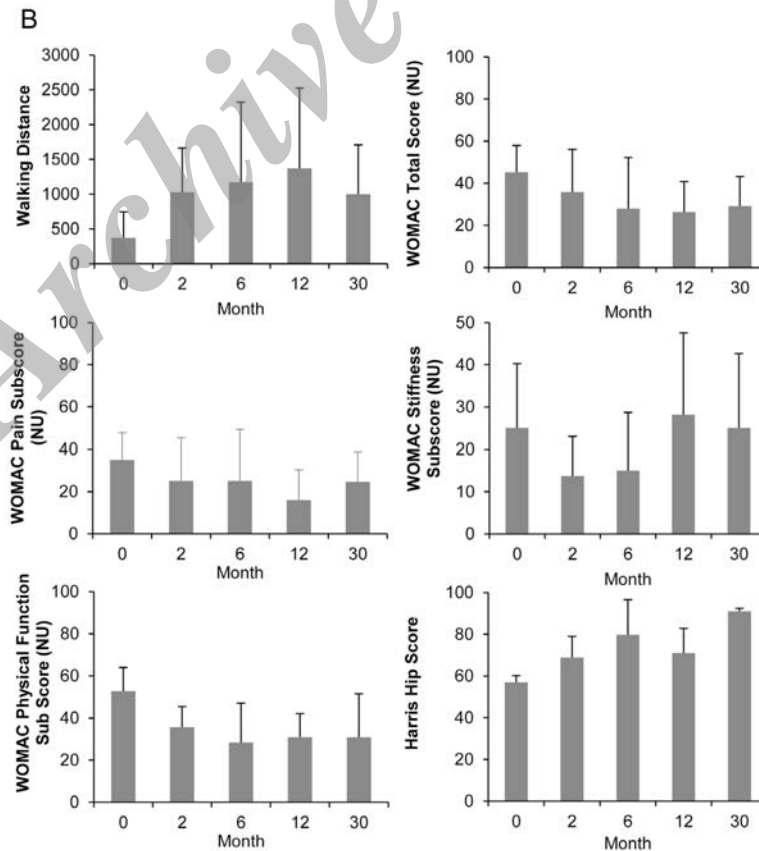
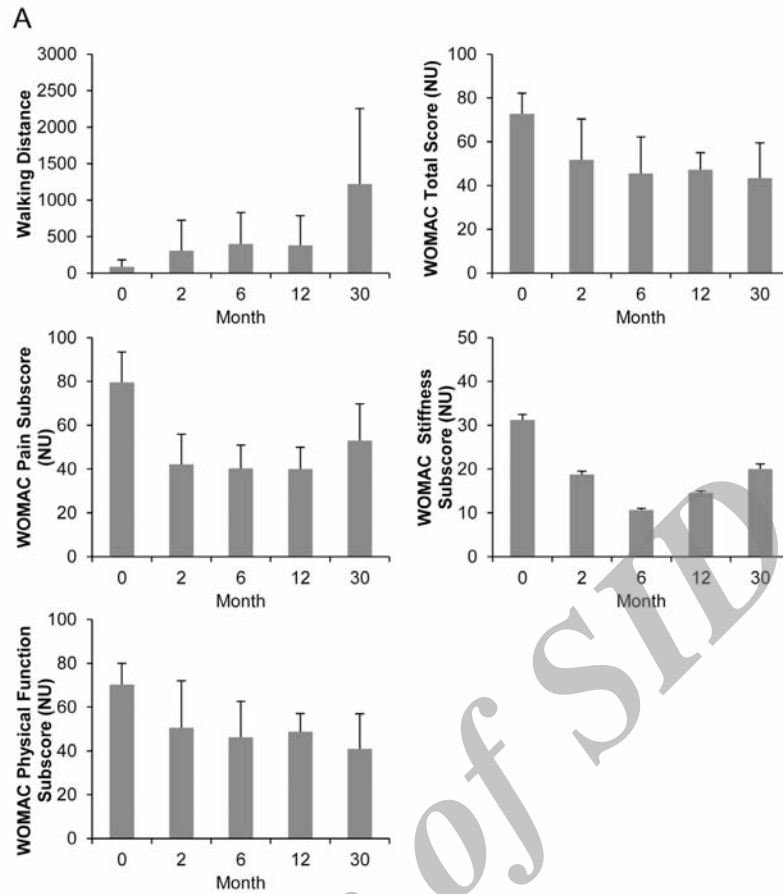
Reductions were observed in mean total WOMAC scores at 12 months ($P < 0.05$) and 30 months ($P < 0.05$) after treatment (Figure 3C). WOMAC stiffness sub-scores were 14.0 ± 8.3 at 6 months, 18.7 ± 14.8 at 12 months, and 4.1 ± 3.6 at 30 months

after treatment (Figure 3C). The WOMAC pain sub-scores were 40.0 ± 16.7 at baseline, 29.0 ± 16.9 at 6 months, 25.0 ± 14.8 at 12 months, and 8.3 ± 5.7 at 30 months after treatment (Figure 5). The WOMAC physical function sub-scores were 35.5 ± 20.0 at 6 months and 24.3 ± 19.7 at 12 months after treatment with MSCs in these patients (Figure 3C).

FAO scores were 55.6 ± 10.4 at 6 months and 58.3 ± 4.9 at 12 months after transplantation compared to a baseline score of 48.9 ± 10.1 . There was an improvement in FAO scores after 30 months (78.7 vs. 48.9 ; $P < 0.05$; Figure 3C).

Imaging outcomes

There was reduced subchondral edema in three of the six patients with knee OA who were treated with MSCs. Articular cartilage repair was seen in three of the five patients with hip OA. Decreased signal intensity related to subchondral edema was seen in four of the six patients with ankle OA at six months after the injections. Radiological analysis, as confirmed by clinical response, reported improvements in all patients which were mainly observed during the first six months after transplantation (Figure 4).



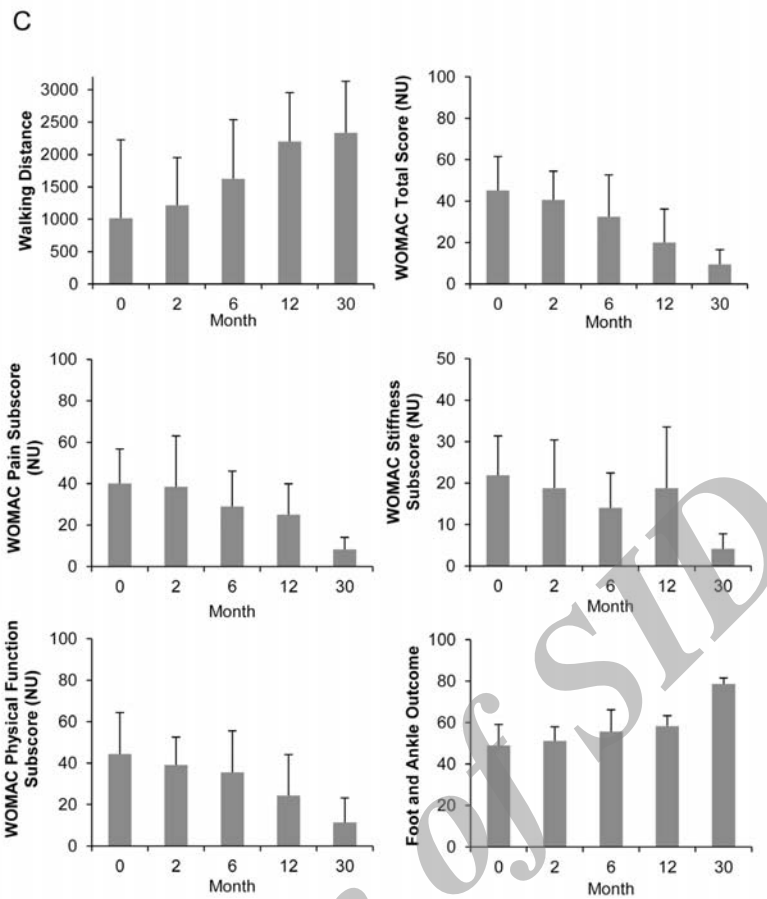


Figure 3. Change from baseline in evaluated indices according to the Western Ontario and McMaster Universities OA Index (WOMAC) measures of total score and pain and stiffness, physical function, and visual analog scale (VAS) in ankle (A), hip (B), and knee (C) osteoarthritis (OA) patients.

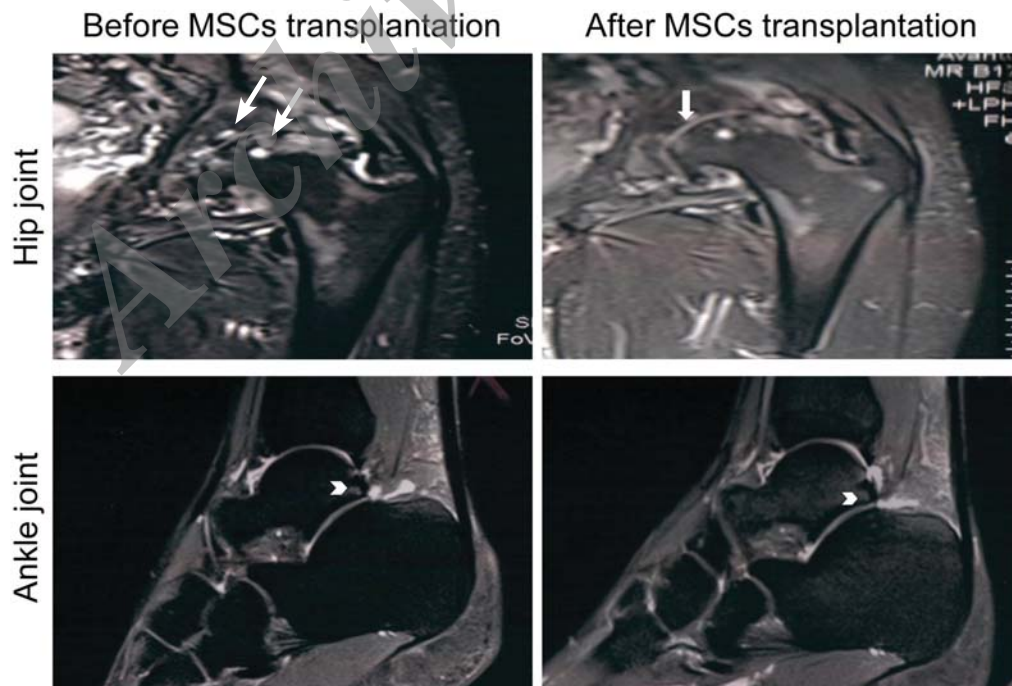


Figure 4. MRI analysis. (A) Sagittal T2 weighted MR image of patient with hip OA shows cartilage surface before MSC transplantation (arrow). (B) Note the predominant increase in cartilage thickness after MSC transplantation (arrow). (C) Sagittal T2 weighted MRI photograph of patient with ankle osteoarthritis (OA). Note the patchy subchondral edema (arrowhead). (D) Arrowhead shows decreased subchondral edema signal at six months after MSC transplantation.

Discussion

Although the metabolism of normal cartilage is comprised of a highly regulated balance between synthesis and degradation of various matrix components, the equilibrium between anabolism and catabolism is weighted in favor of degradation in OA cartilage. The potential for MSCs to restore balance in the affected joint can prevent further destruction.^{11, 12}

OA is a chronic, progressive and debilitating disease. The goal of OA treatment is to reduce pain and increase range of motion in addition to improving QOL for patients.¹³ Thus far, current treatments have not been successful in repairing damaged joints. Destruction of articular tissues increases with age and it is important to note that cartilage does not have the capability for renewal. Therefore, the process of articular tissue destruction is progressive. As it proceeds, daily movement becomes very difficult and is accompanied by tremendous pain.¹⁴⁻¹⁶ As MSCs have the ability to differentiate into chondrocytes and repair damaged cartilage tissues, different studies have been performed to demonstrate the safety of MSCs in repairing articular cartilage.¹⁴⁻¹⁶ The current study has investigated the safety of intra-articular MSC transplantation in patients who suffered from ankle, hip or knee OA and followed them until 30 months. Our results demonstrated a lack of adverse effects for MSC transplantation in these patients. No serious changes from baseline occurred in the biochemical data during the follow-up period.

In 2002, the first study was conducted on transplantation of BM cells in humans. In that study, 24 patients with knee OA were enrolled who were scheduled to undergo high tibial osteotomy. Patients were divided into two groups of 12 patients who underwent transplantation and 12 who formed the control group. Although histological and arthroscopic findings in this study indicated improvements in the treated group, the differences between the two groups were not clinically significant.⁴ Wakitani, *et al.* conducted a study on two patients who had full thickness defects in their patella.¹⁷ In this study, cells from BM aspirates of the patients were isolated and cultured. The cells were subsequently injected into the patellar lesions, which were covered with a periosteum coat. The lesions were completely covered with cartilage two months after the transplantation. The patients' clinical symptoms and pain improved significantly six months after transplantation.¹⁷ In 2006, a Japanese study addressed the effect of BM cell transplantation in a patient with full thickness injury of the medial femoral condyle. As with other studies, the results were satisfactory. In addition, histological examination of the condyle in the patient seven months after transplantation showed that replaced tissues were comprised of hyaline cartilage. This result contrasted previous studies where tissues were replaced by a softer material than the surrounding tissues (fibrocartilage).¹¹ Following the earlier studies, Centeno, *et al.* performed a study in 2006 in which a patient with hip OA had two injections of autologous mononuclear BM cells in the hip joint within one month. At eight weeks after the injections, articular cartilage was seen in the MRI images. The patient's hip joint range of motion improved significantly.¹² Another study investigated transplantation of BM cells in three patients who suffered from patello-femoral joint cartilage lesions. In this study, as well as in previous studies, the results were satisfactory and indicated the effectiveness of this approach for the treatment of joint destruction.¹⁸ Centeno, *et al.* conducted a 2-year follow-up

of 213 patients who underwent intra-articular injections of cultured MSCs. No neoplastic complications were reported in these patients.⁸ Emadedin, *et al.* performed a study in 2008 in which six patients with late stage OA were selected for BM aspiration.⁹ In this study, MSCs were isolated, cultured, and injected intra-articularly into the knees. No adverse systemic or localized events were observed in the patients within six months of follow-up. The VAS scores were reduced from 98 to 63 in these patients during six months. The WOMAC questionnaire was used for assessment of pain, daily activities and social functioning. During six months of follow-up, the mean WOMAC score reduced from 2.95 to 1.97, which indicated improvement within the six month period. In 2012, another study investigated transplantation of allogenic mesenchymal stem cell in knee joint of 55 patients, seven to ten days after partial medial meniscectomy operation. No neoplastic changes occurred after one year of follow up and regeneration of meniscus was seen in the MSC transplanted group.¹⁹

Our findings showed improvement in all evaluated parameters which included walking distance, clinical data, total WOMAC scores, and VAS during 12 months after cell therapy in all OA groups. In addition, treatment effects on OA symptoms remained stable for up to 12 months after treatment. According to our clinical findings, MRI images showed that intra-articular transplantation of MSCs caused repair and thickening of joint cartilage in all OA groups six months after treatment in comparison with baseline. For example, one patient from the ankle OA group was a 45-year-old male who had a five-year history of severe ankle OA. The patient had a single intra-articular injection of 6.5×10^7 MSCs. The walking distance of this patient increased more than thirty-fold after the transplantation of MSCs and the total WOMAC score improved at least 48%. The results were completely consistent with his MRI findings. In the patient's MRI, severe destruction of ankle cartilage and subchondral edema was seen before MSC transplantation. After the MSC transplantation, subchondral edema decreased and the cartilage thickness increased. MSC transplantation is a non-invasive procedure which is less expensive and easier to perform compared to current OA treatments such as joint replacement.

Our clinical results have shown improvements of healing conditions in patients with OA. However, although improvements were observed, the standard numbers of MSCs have not been identified for each injection. In our study, the patients underwent single intra-articular injections of MSCs. During the 30 months of follow-up, we observed increased recovery process for 12 months after treatment; however, there was a decrease after the twelfth month. Possibly, subsequent injections of MSCs at specific intervals would help to achieve better therapeutic effects. It is reasonable to consider that the MSC intra-articular transplantation technique might represent a promising therapeutic approach for the treatment of ankle, hip or knee OA.

Because our study investigates the safety of MSC transplantation in OA patients, further studies are necessary with larger numbers of participants for additional statistical analyses in order to determine the therapeutic effects of this approach. In addition, future studies should be performed to determine the standard number of MSCs required for each injection, whether subsequent injections are necessary at specific intervals to assist with the recovery process, the different factors that have an effect on treatment outcomes, and to establish standard methods for treatment procedures.

In conclusion, our study demonstrated that transplantation of BM-derived autologous MSCs in patients with knee, hip or ankle OA lacked adverse effects and was completely safe. Evidence showed that this method had therapeutic benefits such as decreased pain and WOMAC scores, and improved walking distance.

Funding

This study was supported by Royan Institute.

Declaration of conflicting interests

The author(s) declare no potential conflicts of interest with respect to the research, authorship, and/or publication of this article.

Author contributions

Mohsen Emadedin confirmed the enrollment of patients who were screened and performed intra-articular injections.

Maede Ghorbani Liastani performed patient screening for enrollment, patient follow-up after cell transplantation, monitored the clinical evaluation, data collection and statistical analysis.

Roghayeh Fazeli, Fatemeh Mohseni, Narges Labibzadeh and Ali Mirazimi Bafghi performed patient screening for enrollment.

Reza Moghadasali and Soura Mardpour performed MSCs isolation, cell culturing, and flow cytometry.

Seyyede Esmat Hosseini assisted in the operation room for bone marrow aspiration and sample preparation.

Maryam Niknejadi performed image analyses.

Fatemeh Moeininia performed bone marrow aspirations.

Aslan Aghahosseini Fanni performed quality control tests for cultured cells.

Reza Baghban Eslaminejhad and Ahmad Vosough Dizaji supervised some parts of study.

Hossein Baharvand was involved in writing the manuscript.

Nasser Aghdami designed the study, oversaw data acquisition and analysis, and is the principal editor of this article.

Acknowledgment

The authors wish to express their appreciation to the staff of the Department of Regenerative Medicine.

References

- Harrington L, Schneider JI. Atraumatic joint and limb pain in the elderly. *Emerg Med Clin North Am.* 2006; **24**: 389 – 412, vii.
- Van Manen MD, Nace J, Mont MA. Management of primary knee osteoarthritis and indications for total knee arthroplasty for general practitioners. *J Am Osteopath Assoc.* 2012; **112**: 709 – 715.
- Le Blanc K, Ringden O. Immunomodulation by mesenchymal stem cells and clinical experience. *J Intern Med.* 2007; **262**: 509 – 525.
- Wakitani S, Imoto K, Yamamoto T, Saito M, Murata N, Yoneda M. Human autologous culture expanded bone marrow mesenchymal cell transplantation for repair of cartilage defects in osteoarthritic knees. *Osteoarthritis Cartilage.* 2002; **10**: 199 – 206.
- Centeno CJ, Busse D, Kisiday J, Keohan C, Freeman M, Karli D. Regeneration of meniscus cartilage in a knee treated with percutaneously implanted autologous mesenchymal stem cells. *Med Hypotheses.* 2008; **71**: 900 – 908.
- Davatchi F, Abdollahi BS, Mohyeddin M, Shahram F, Nikbin B. Mesenchymal stem cell therapy for knee osteoarthritis. Preliminary report of four patients. *Int J Rheum Dis.* 2011; **14**: 211 – 215.
- Wakitani S, Okabe T, Horibe S, Mitsuoka T, Saito M, Koyama T, et al. Safety of autologous bone marrow-derived mesenchymal stem cell transplantation for cartilage repair in 41 patients with 45 joints followed for up to 11 years and 5 months. *J Tissue Eng Regen Med.* 2011; **5**: 146 – 150.
- Centeno CJ, Schultz JR, Cheever M, Freeman M, Faulkner S, Robinson B, et al. Safety and complications reporting update on the re-implantation of culture-expanded mesenchymal stem cells using autologous platelet lysate technique. *Curr Stem Cell Res Ther.* 2011; **6**: 368 – 378.
- Emadedin M, Aghdami N, Taghiyar L, Fazeli R, Moghadasali R, Jahangir S, et al. Intra-articular injection of autologous mesenchymal stem cells in six patients with knee osteoarthritis. *Arch Iran Med.* 2012; **15**: 422 – 428.
- Dominici M, Le Blanc K, Mueller I, Slaper-Cortenbach I, Marini F, Krause D, et al. Minimal criteria for defining multipotent mesenchymal stromal cells. The International Society for Cellular Therapy position statement. *Cytotherapy.* 2006; **8**: 315 – 317.
- Kuroda R, Ishida K, Matsumoto T, Akisue T, Fujioka H, Mizuno K, et al. Treatment of a full-thickness articular cartilage defect in the femoral condyle of an athlete with autologous bone-marrow stromal cells. *Osteoarthritis Cartilage.* 2007; **15**: 226 – 231.
- Centeno CJ, Kisiday J, Freeman M, Schultz JR. Partial regeneration of the human hip via autologous bone marrow nucleated cell transfer: A case study. *Pain Physician.* 2006; **9**: 253 – 256.
- Brittberg M, Lindahl A, Nilsson A, Ohlsson C, Isaksson O, Peterson L. Treatment of deep cartilage defects in the knee with autologous chondrocyte transplantation. *N Engl J Med.* 1994; **331**: 889 – 895.
- Hjelle K, Solheim E, Strand T, Muri R, Brittberg M. Articular cartilage defects in 1,000 knee arthroscopies. *Arthroscopy.* 2002; **18**: 730 – 734.
- Mankin HJ. The response of articular cartilage to mechanical injury. *J Bone Joint Surg Am.* 1982; **64**: 460 – 466.
- Hunziker EB. Articular cartilage repair: basic science and clinical progress. A review of the current status and prospects. *Osteoarthritis Cartilage.* 2002; **10**: 432 – 463.
- Wakitani S, Mitsuoka T, Nakamura N, Toritsuka Y, Nakamura Y, Horibe S. Autologous bone marrow stromal cell transplantation for repair of full-thickness articular cartilage defects in human patellae: two case reports. *Cell Transplant.* 2004; **13**: 595 – 600.
- Wakitani S, Nawata M, Tensho K, Okabe T, Machida H, Ohgushi H. Repair of articular cartilage defects in the patello-femoral joint with autologous bone marrow mesenchymal cell transplantation: three case reports involving nine defects in five knees. *J Tissue Eng Regen Med.* 2007; **1**: 74 – 79.
- Vangsnest CT Jr, Farr J 2nd, Boyd J, Dellaero DT, Mills CR, LeRoux-Williams M. Adult Human Mesenchymal Stem Cells Delivered via Intra-Articular Injection to the Knee Following Partial Medial Meniscectomy: A Randomized, Double-Blind, Controlled Study. *J Bone Joint Surg Am.* 2014; **96**: 90 – 98.