

## Case Report

## Refractory Hyperlactatemia with Organ Insufficiency in Lipid Storage Myopathy

Yuanda Xu<sup>1</sup>, Li Zhou<sup>1</sup>, Weibo Liang<sup>1</sup>, Weiqun He<sup>1</sup>, Xiaoqing Liu<sup>1</sup>, Xiuling Liang<sup>1</sup>, Nanshan Zhong<sup>1</sup>, Yimin Li MD PHD<sup>1</sup>

### Abstract

Lipid storage myopathy is a metabolic disorder characterized by abnormal lipid accumulation in muscle fibers and progressive muscle weakness.

Here, we report the case of a 17-year-old woman with progressive muscle weakness, refractory hyperlactatemia, and multiple organ insufficiency. Severe pneumonia was the initial diagnosis. After anti-infective treatment, fluid resuscitation, and mechanical ventilation, the patient's symptoms improved but hyperlactatemia and muscle weakness persisted. She was empirically treated with carnitine. Biochemical tests, electromyography, and muscle biopsy confirmed lipid storage myopathy. After 7 weeks of treatment, the patient resumed normal daily life.

An empirical treatment with carnitine may be beneficial for patients before an accurate diagnosis of lipid storage myopathy is made.

**Key words:** Carnitine, hyperlactatemia, lipid storage myopathy, respiratory failure, septic shock

**Cite this article as:** Xu Y, Zhou L, Liang W, He W, Liu X, Liang X, et al. Refractory Hyperlactatemia with Organ Insufficiency in Lipid Storage Myopathy. *Arch Iran Med.* 2015; 18(8): 545 – 548.

### Introduction

Circulating free fatty acids are the major energy source for the muscle. Disorders of lipid metabolism can result in various metabolic myopathies and lead to muscle dysfunction. An example is lipid storage myopathy (LSM), which presents clinically as a globally progressive muscle weakness, sometimes accompanied by muscle atrophy. Pathologically, LSM is characterized by prominent lipid accumulation in muscle fibers.<sup>1</sup> Without typical symptoms, LSM is often misdiagnosed and mistreated. A definitive diagnosis requires careful pathological examinations that may take much time.

Here, we report the case of a 17-year-old woman with refractory hyperlactatemia, septic shock, multiple organ insufficiency, and progressive muscle weakness history. The patient was empirically treated with carnitine before LSM was histologically confirmed. The patient fully recovered after 7 weeks of treatment. Based on our experience, we recommend early empirical treatment with carnitine for patients suspected of LSM, prior to the pathologically confirmed diagnosis. Most metabolic myopathies respond poorly to treatment, but LSM can be effectively cured if diagnosed in a timely fashion. Timely treatment can effectively shorten the disease process, reduce complications, and decrease the economic burden of patients.

### Case report

A 17-year-old female was admitted to our hospital after an 8-month history of pitting edema and weakness in the lower limbs

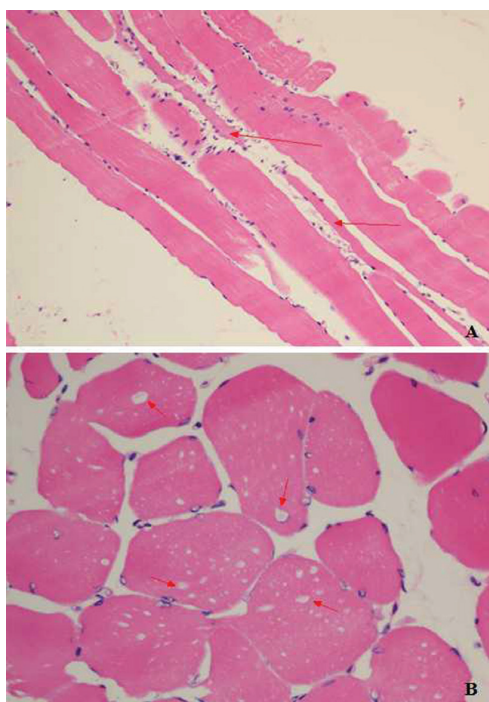
**Authors' affiliation:** <sup>1</sup>State Key Laboratory of Respiratory Disease, The First Affiliated Hospital of Guangzhou Medical University, No.151 Yanjiang Road West, Guangzhou 510120, Guangdong, China.

**Corresponding author and reprints:** Yimin Li MD PHD, State Key Laboratory of Respiratory Disease, The First Affiliated Hospital of Guangzhou Medical University, No.151 Yanjiang Road West, Guangzhou 510120, Guangdong, China. Tel: +86-020-83062608, E-mail: dryiminli@vip.163.com, liyimin1308151@163.com. Accepted for publication: 22 July 2015

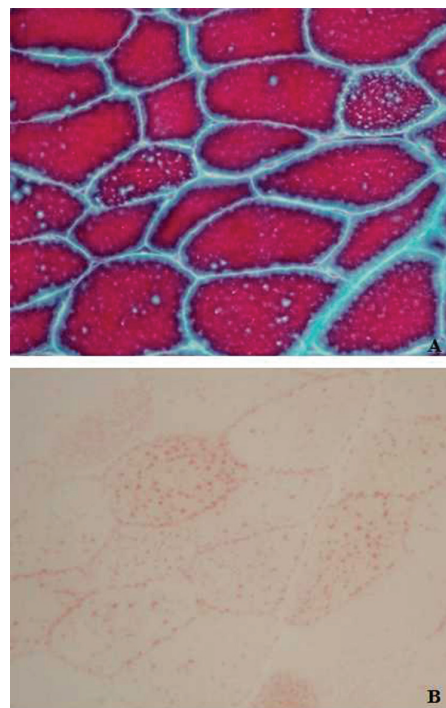
with muscle soreness and occasional palpitation, exacerbated since one week ago. During the eight months, her blood creatine kinase (CK) levels were consistently elevated. A myogram suggested peripheral neurogenic damage, possibly resulting from polymyositis or Guillain-Barré syndrome. The patient was previously treated with high-dose steroid,  $\gamma$ -globulin, cyclophosphamide (Cytoxan) (2 months before admission to our hospital), as well as other supportive therapy. Her symptoms did not improve. She was slightly underweight, without coughing.

Physical examination revealed a heart rate of 125 beats/min, non-pitting edema of the lower limbs, slight edema of both hands, grade-4 strength in the upper limb muscles and grade 3 in the lower limb muscles. Lab tests showed lactic acid levels >12.0 mmol/L (normal, 0.7–2.1 mmol/L), pH 7.235–7.405, HCO<sub>3</sub> 8.2–14.7 mmol/L, CK 734 U/L (normal, 10–190 U/L), and lactate dehydrogenase 1274 U/L (normal, 109–255 U/L). The chest X-ray was normal. The electrocardiogram showed sinus tachycardia and T wave changes. The ultrasonic cardiogram and cardiac function test revealed backflow through the tricuspid valve (median), pulmonary arterial hypertension (48 mmHg), slight pericardial effusion, ejection fraction 60%, and normal contraction. The myogram indicated neurogenic muscle damage. A diagnosis of polymyositis and bronchitis was made.

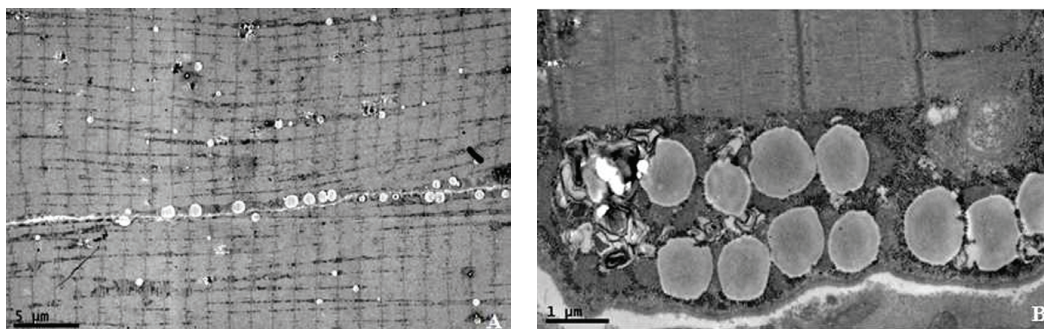
The patient experienced dyspnea five days after admission. Lab tests showed a NT-proBNP of 3294 pg/mL (normal, <155 pg/mL) and refractory hyperlactatemia. Arterial blood gas analysis indicated metabolic acidosis and respiratory alkalosis with pH 7.32, PaCO<sub>2</sub> 18.9 mmHg, PaO<sub>2</sub> 121 mmHg, and HCO<sub>3</sub> 9.4 mmol/L. Chest X-ray showed heart enlargement, pneumonia in double lower lobes of lung, pulmonary edema, and pericardial effusion. The patient was then transferred to the intensive care unit. Her muscle weakness, limb edema, and shortness of breath were aggravated. On admission to the ICU, physical examination revealed respiratory rate 30/min, heart rate 120–138 beats/min, SpO<sub>2</sub> 100% (mask oxygenation <4 L/min), moist rales in double lower lungs, and negative pathological signs. Neurological exam-



**Figure 1.** Quadriceps biopsy. **A)** The muscle fibers were smaller than normal fibers. Arrows show atrophied muscle. Hematoxylin and eosin, 200×. **B)** Arrows indicate sieve-like empty bubbles within the muscle fibers. Hematoxylin and eosin, 400×.



**Figure 2.** Quadriceps biopsy. **A)** Modified Gomori trichrome staining shows white lipid-like empty bubbles; arrows show the empty bubbles; 400×. **B)** Oil red O staining reveals accumulated lipid droplets, empty bubbles are stained orange within the muscle fibers; arrows show orange-colored empty bubbles; 400×.



**Figure 3.** Electron microscopic examination of the biopsied quadriceps specimen shows increased numbers of lipid droplets within muscle fibers; mitochondria and glycogen are normal (**A**) 2000× ; **B**) 10 000×).

ination revealed muscular atrophy of the limbs. The strength of the limb muscles declined to grade 2. The white blood cell count increased to  $20 \times 10^9/L$ . The patient was treated with antibiotics and non-invasive ventilation. The symptoms of muscle weakness continued to deteriorate and the patient had difficulty chewing, swallowing, and lifting her head.

The patient underwent endotracheal intubation and assisted mechanical ventilation after 14 days in the hospital and 9 days in the ICU. Her blood pressure slightly decreased during intubation, concomitant with oliguria. Because septic shock could not be ruled out, continuous veno-venous hemofiltration was performed at bedside for three days, even with partial high-volume hemofiltration. However, hyperlactatemia persisted and the sputum smear confirmed bacterial and fungal infection. One week after the start of endotracheal intubation, the patient's lung infection was shortly under control. Blood

oxygen exchange improved after mechanical ventilation but muscle weakness persisted. Tracheotomy was performed because of the difficulty in withdrawing the endotracheal tube.

Considering the patient's progressive muscle weakness, myogram was performed and muscle biopsy was taken from the quadriceps. Histology of the biopsied muscle sections showed muscle atrophy and few inflammatory cells. No vasculitis was found, as well as any evidence of the connective tissue disease due to negative immunological results. Metabolic myopathy and LSM were suggested. The patient was then treated with L-carnitine (2 g, intravenous, daily),  $\gamma$ -globulin (0.4 g/kg, intravenous drip, daily, for 5 consecutive days), a small amount of steroid (10mg/d of prednisone), and a carnitine-rich diet of meat.

Four weeks after admission to the ICU, the strength of the limb muscles improved to grade 4. The patient was able to lift her

hands over her head and was released from the ventilator. Lab tests showed a blood lactic acid level of 7–8 mmol/L (normal, 0.7–2.1 mmol/L), CK level of 277 U/L, and lactate dehydrogenase level of 501 U/L.

The quadriceps biopsy indicated muscular atrophy (Figure 1A) and empty bubbles within the muscle fibers (Figure 1B). Modified Gomori trichrome staining showed white lipid-like empty bubbles (Figure 2A). Oil red O staining revealed increased lipid droplets within the muscle fibers (Figure 2B); mitochondria and glycogen were normal (Figures 3A and 3B). Thus, LSM was confirmed. Analysis of the *ETFDH* gene (electron-transferring-dehydrogenase) found no mutation.

The strength of the limb muscles improved to grade 5. The patient was able to move her limbs freely. The blood lactic acid level was maintained at 2–3 mmol/L and the patient was discharged after seven weeks of hospitalization.

## Discussion

LSM is a metabolic disease characterized by abnormal lipid accumulation in muscle fibers, and is caused by the deficiency of carnitine or related enzymes. Four types of LSM can be diagnosed genetically: primary carnitine deficiency, multiple acyl-coenzyme A dehydrogenase deficiency, neutral lipid storage disease with ichthyosis, and neutral lipid storage disease with myopathy.<sup>1–4</sup> The first, primary carnitine deficiency, is an autosomal-recessive disorder resulting from mutations of *SLC22A5* (solute carrier family 22 [organic cation/carnitine transporter], member 5). *SLC22A5* encodes the carnitine/organic cation transporter OCTN2.<sup>5–7</sup> Defective OCTN2 leads to accumulation of long-chain fatty acids in the cytoplasm of cells. Increased blood levels of hepatic enzymes and CK are very common. Muscle pathology reveals that both the number and size of lipid droplets are higher than normal in muscle fibers. Early carnitine therapy can effectively prevent cardiomyopathy and damage to other organs.<sup>8,9</sup>

Multiple acyl-coenzyme A dehydrogenase deficiency is also known as glutaric aciduria type II. It is caused by mutations in electron-transferring-flavoprotein (*ETF*) or *ETFDH*.<sup>10,11</sup> In this form of LSM, the characteristics of muscle pathology are similar to those of primary carnitine deficiency. Detection of plasma carnitine, acylcarnitines, and urinary organic acid is helpful for diagnosis. Riboflavin supplementation can significantly improve the clinical symptoms of patients.

Neutral lipid storage disease with ichthyosis and neutral lipid storage disease with myopathy<sup>12–16</sup> are very rare, and are caused by defects of an adipose triglyceride lipase (PNPLA2) or abhydrolase domain containing protein 5 (ABHD5). Systemic triglyceride deposition in multiple tissues is a characteristic of neutral lipid storage diseases with ichthyosis; tissues that include skin, muscle, liver, central nervous system, and blood leukocytes. Conversely, neutral lipid storage disease with myopathy is characterized by slowly progressive myopathy.<sup>16,17</sup> Cardiac involvement is very common.<sup>18</sup> Lipid accumulation in leukocytes occurs in both of these neutral lipid storage diseases. There is no effective treatment.

In most cases, the diagnostic criteria for LSM consists of weakness of the proximal muscles with lab tests confirming myopathy, increased lipid droplets in muscle fibers without other pathological changes, the elimination of the possibility of all other metabolic diseases, and no other organ damage.<sup>19</sup> Differential diagnosis may require a process of elimination, as muscle weakness and

elevated CK are also very common with other myopathies such as myasthenia gravis, progressive muscle atrophy, and polymyositis. A helpful notion is that these other disorders have specific characteristics. Myasthenia gravis requires a positive neostigmine test and normal blood CK levels. In progressive muscle atrophy, the muscle biopsy will reveal no lipid accumulation in muscle fibers. Ruling out polymyositis are signs of neurogenic muscular damage that often accompany LSM, but are rarely seen in polymyositis—because the myopathy of LSM involves both type I and II muscle fibers, malnutrition of peripheral nerves leads to such damages.

The prognosis of patients with LSM is usually good. Most patients recover and resume normal daily life after timely treatments. However, relapses can occur under circumstances such as fatigue or cold, and the patient's condition can deteriorate rapidly with infection or overwork, eventually leading to multiple organ failure. Mechanical ventilation is required when patients have difficulty swallowing or breathing.

In this report, we presented a typical case of LSM. The patient had progressive muscle weakness and refractory hyperlactatemia. Thy symptoms deteriorated accompanied by middle infection. The function of the immune system was compromised, possibly associated with the previous administration of steroid and CTX in another hospital. Her condition did not improve after fluid resuscitation or aggressive treatments for septic shock. The lactate clearance rate was zero. The patient suffered from shock accompanied by reduced urine output, continuous veno-venous hemofiltration for blood purification was applied and it did not work out. However, the concentration of arterial blood lactic acid in this patient remained high. Under these conditions, the possibility of hyperlactatemia should be considered.

As we know, lactic acid is an intermediate product of glycolysis. It is mainly produced in the skin, brain, skeletal muscle, red blood cells, and intestinal mucosa, and metabolized in the liver. There are many causes of hyperlactatemia, including global or local hypoperfusion, severe inflammation, severe metabolic disorder, and deficient mitochondrial respiration. These conditions lead to activation of anaerobic glycolysis and promote the production of lactate.<sup>20</sup> In the present case, because the patient had normal liver function and the infection was rapidly controlled, a metabolic disorder was considered. The patient's condition improved significantly after treatment with L-carnitine, low-dose steroid,  $\gamma$ -globulin, and a carnitine-rich diet. To investigate the possibility of genetic etiology, we examined the *ETFDH* gene and no mutation was found. For economic reasons, mutations in other genes were not studied.

The diagnosis of LSM depends on pathological examination of muscle obtained through biopsy, a process that is both long and complicated. Based on clinical experience, early empirical therapy with carnitine is important for this type of patients, before the pathological confirmation of LSM. Unlike most metabolic myopathies, LSM usually responds well to treatment, when the treatment is timely.

## Conflicts of interest statement

The authors declare that there are no conflicts of interest.

## Acknowledgment

We thank Medjaden Bioscience Limited for assisting in the preparation of this manuscript.

## References

- Liang WC, Nishino I. Lipid storage myopathy. *Curr Neurol Neurosci Rep.* 2011; 11(1): 97-103.
- Skuban T, Klopstock T, Schoser B. Lipid storage myopathies. A clinical and pathobiochemical challenge. *Nervenarzt.* 2010; 81(12): 1460-6.
- Ohkuma A, Noguchi S, Sugie H, Malicdan MC, Fukuda T, Shimazu K, et al. Clinical and genetic analysis of lipid storage myopathies. *Muscle Nerve.* 2009; 39(3): 333-42.
- Bruno C, Dimauro S. Lipid storage myopathies. *Curr Opin Neurol.* 2008; 21(5): 601-06.
- Nezu J, Noguchi S, Sugie H, Malicdan MC, Fukuda T, Shimazu K, et al. Primary systemic carnitine deficiency is caused by mutations in a gene encoding sodium ion-dependent carnitine transporter. *Nat Genet.* 1999; 21(1): 91-4.
- Shibbani K, Fahed A, Al-Shaar L, Arabi M, Nemer G, Bitar F, et al. Primary carnitine deficiency: novel mutations and insights into the cardiac phenotype. *Clin Genet.* 2014; 85(2): 127-37.
- Agnetti A, Bitton L, Tchana B, Raymond A, Carano N. Primary carnitine deficiency dilated cardiomyopathy: 28 years follow-up. *Int J Cardiol.* 2013; 162(2): e34-35.
- Lamhonwah AM, Olpin SE, Pollitt RJ, Vianey-Saban C, Divry P, Guffon N, et al. Novel OCTN2 mutations: no genotype-phenotype correlations: early carnitine therapy prevents cardiomyopathy. *Am J Med Genet.* 2002; 111(3): 271-84.
- Kato K, Mizota T, Hirota K, Fukuda K. Successful perioperative management of a patient with primary systemic carnitine deficiency: a case report. *J Anesth.* 2013; 27(1): 141-2.
- Wakitani S, Torisu S, Yoshino T, Hattanda K, Yamato O, Tasaki R, et al. Multiple Acyl-CoA dehydrogenation deficiency (Glutaric Aciduria Type II) with a novel mutation of electron transfer flavoprotein-dehydrogenase in a cat. 2014;13:43-51.
- Sugai F, Baba K, Toyooka K, Liang WC, Nishino I, Yamadera M, et al. Adult-onset multiple acyl CoA dehydrogenation deficiency associated with an abnormal isoenzyme pattern of serum lactate dehydrogenase. *Neuromuscul Disord.* 2012; 22(2): 159-61.
- Demerjian M, Crumrine DA, Milstone LM, Williams ML, Elias PM. Barrier dysfunction and pathogenesis of neutral lipid storage disease with ichthyosis (Chanarin-Dorfman syndrome). *J Invest Dermatol.* 2006; 126(9): 2032-8.
- Venencie PY, Armengaud D, Foldès C, Vieillefond A, Coulombel L, Hadchouel M. Ichthyosis and neutral lipid storage disease (Dorfman-Chanarin syndrome). *Pediatr Dermatol.* 1988; 5(3): 173-7.
- Musumeci S, D'Agata A, Romano C, Patané R, Cutrona D. Ichthyosis and neutral lipid storage disease. *Am J Med Genet.* 1988; 29(2): 377-82.
- Fischer J, Lefèvre C, Morava E, Mussini JM, Laforêt P, Negre-Salvayre A, et al. The gene encoding adipose triglyceride lipase (PNPLA2) is mutated in neutral lipid storage disease with myopathy. *Nat Genet.* 2007; 39(1): 28-30.
- Chen J, Hong D, Wang Z, Yuan Y. A novel PNPLA2 mutation causes neutral lipid storage disease with myopathy (NLSMD) presenting muscular dystrophic features with lipid storage and rimmed vacuoles. *Clin Neuropathol.* 2010; 29(6): 351-6.
- Lin P, Li W, Wen B, Zhao Y, Fenster DS, Wang Y, et al. Novel PNPLA2 gene mutations in Chinese Han patients causing neutral lipid storage disease with myopathy. *J Hum Genet.* 2012; 57(10): 679-81.
- Igal RA, Rhoads JM, Coleman RA. Neutral lipid storage disease with fatty liver and cholestasis. *J Pediatr Gastroenterol Nutr.* 1997; 25(5): 541-7.
- Tarnopolsky MA, Raha S. Mitochondrial myopathies: diagnosis, exercise intolerance, and treatment options. *Med Sci Sports Exerc.* 2005; 37(12): 2086-93.
- Mackenzie DD. Production and utilization of lactic acid by the ruminant. A review. *J Dairy Sci.* 1967; 50(11): 1772-86.