

Case Report

Disseminated Kaposi's Sarcoma

Khadijeh Makhdoomi MD¹, Azam Mivefroshan MD^{1*}, Mohammad Hossein Rahimirad MD², Masome Rabeipour MD², Fariba Abbasi MD³, Afshin Mohammadi MD⁴, Ali Eishei Oskuei MD⁵

Abstract

Kaposi's Sarcomas (KS) have been associated with many conditions and also known as a typical complication of immunosuppression. It should be considered as an important differential diagnosis in skin lesions of patients after solid organ transplantation. This is a report of a 61-year-old man, who presented with disseminated KS and a history of renal transplantation. We suggest systemic evaluation and visceral assessment in patients with Cutaneous KS.

Keywords: Immunosuppression, kaposi's sarcoma, kidney transplantation

Cite this article as: Makhdoomi K, Mivefroshan A, Rahimirad MH, Rabeipour M, Abbasi F, Mohammadi A, Eishei Oskuei A. Disseminated kaposi's sarcoma. *Arch Iran Med.* 2015; **18(11)**: 793 – 795.

Introduction

Kaposi's sarcoma (KS) is a low-grade vascular tumor that derived from lymphatic endothelial cells infected with type 8 of human herpes virus (HHV8) also known as KS-associated herpes virus (KSHV).¹ Iatrogenic form of KS is most often detected in patients after kidney transplantation which reflects the higher frequency in this population. KS is most notable for its cutaneous involvement, characterized by dermal purplish, reddish blue, or dark black macules, plaques, and nodules. Lymph node enlargement and visceral localization are other clinical manifestation of KS.² Visceral involvement occurs in 25 to 30 percent of patients with kidney transplants and in 50 percent of those with liver or heart transplants.³ We present a 61-year-old man with multiple cutaneous lesion and disseminated visceral involvement in the stomach, transverse colon, liver, mediastinal lymph nodes and lungs 10 months after renal transplantation.

Case Report

A 61-year-old man with end-stage renal disease due to hypertension, one year after hemodialysis received a renal transplant from a living unrelated donor. His initial induction of immunosuppressive therapy was cyclosporine (6 mg/kg), mycophenolate mofetil (2 g/day) and prednisolone 1 mg/kg after three pulses of 1000 mg methylprednisolone daily. He had no episode of acute rejection or medical problems after transplantation. At the time of discharge, the serum creatinine was 1.5 g/dL, laboratory test was within the normal limit and the qualitative CMV DNA PCR was negative.

Ten months later, he was admitted with skin lesion and exer-

tional dyspnea. He had coughed without sputum and hemoptysis. Upon physical examination, the patient was comforted, afebrile, with room-air oximetry of 95% but he had rale's over both lungs on auscultation. Skin exam revealed reddish blue plaques in different sizes from 1 cm in face, scalp and periauricular areas to 4 cm in RLQ just above the scar of transplant surgery. There was not any abnormal finding in other physical examination. Chest X-ray and chest CT scan showed multiple well-defined round nodules (1 – 4 mm in diameter) without calcification in both lungs field and right-sided pleural effusion (Figure 1), as well as several lymph nodes in anterior and middle mediastinal (Figure 2). Also, multiple hypodense round opacities in the right and left lobe of liver with sharp border and without calcification was reported in abdominal CT scan (Figure 3). For detection of endobronchial lesions, bronchoscopy was performed and revealed diffuse airway edema with multiple sub-mucosal hemorrhagic lesions in both lungs (Figure 4).

Microscopic evaluation of skin biopsies revealed an area of hemorrhage and vascular proliferation as well as a collection of spindle shaped cells with positive CD₃₁ and CD₃ in immunohistochemistry staining (Figure 5). Overall, these findings were diagnostic of Kaposi's sarcoma. Upper and lower gastrointestinal endoscopy was performed to diagnose the other sit of KS. The result showed blue plaques on esophagus and multiple ulcerative and hemorrhagic lesion on fundus and body of the stomach and also in the transverse colon. Unfortunately, we have not any possibility for detection of human herpes virus 8 (HHV8) in our center. Immunosuppressive therapy was changed from cyclosporine and mycophenolate mofetil to Sirolimus. Due to worsening dyspnea and disseminates involvement, chemotherapy with Beleomycin (15 mg Q 15d), Vinblastin (10 mg Q 15d), and Adriamycin (50 mg Q 28d) for six months was scheduled.

Discussion

KS is a rare cancer in the general population, whereas its prevalence is more common among immunocompromised patients including AIDS and solid organ recipients.⁴ Intensive Immunosuppressive therapy is significantly associated with higher risk of developing KS after transplantation.⁵ The rate of post-transplan-

Authors' affiliations: ¹Nephrology and Renal Transplant Research Center, Uromia University of Medical Sciences, Uromia, Iran, ²Pulmonology and Critical Care Medicine, Uromia University of Medical Sciences, Uromia, Iran, ³Solid Tumor Research Center, Uromia University of Medical Sciences, Uromia, Iran, ⁴Radiology Department, Uromia University of Medical Sciences, Uromia, Iran, ⁵Hematology and Oncology Department, Uromia University of Medical Sciences, Uromia, Iran.

Corresponding author and reprints: Azam Mivefroshan MD, Nephrology and Renal Transplant Research Center, Uromia University of Medical Sciences, Uromia, Iran. Postal Address: Emam Khomeini Hospital, Ershad Ave., Uromia, Iran. Cell Phone: +98-9143437809, Fax: +98-44-33469935, E-mail: dr.azam2011@gmail.com.

Accepted for publication: 24 July 2015

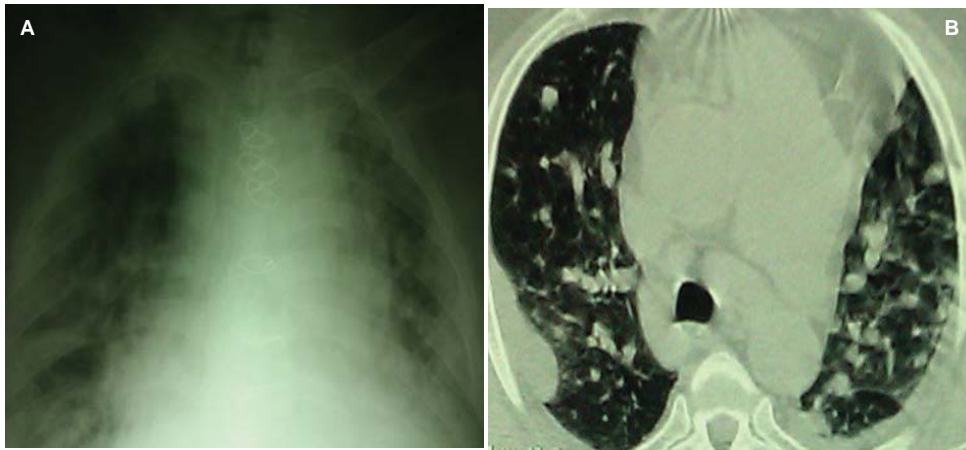


Figure 1. A) Chest X ray; B) Chest CT-scan

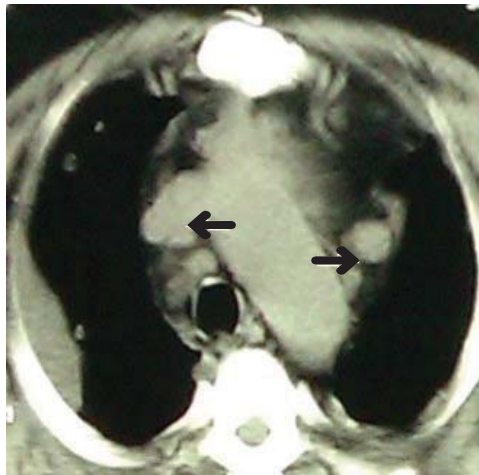


Figure 2. Lymph node in anterior and middle mediastin (arrows)

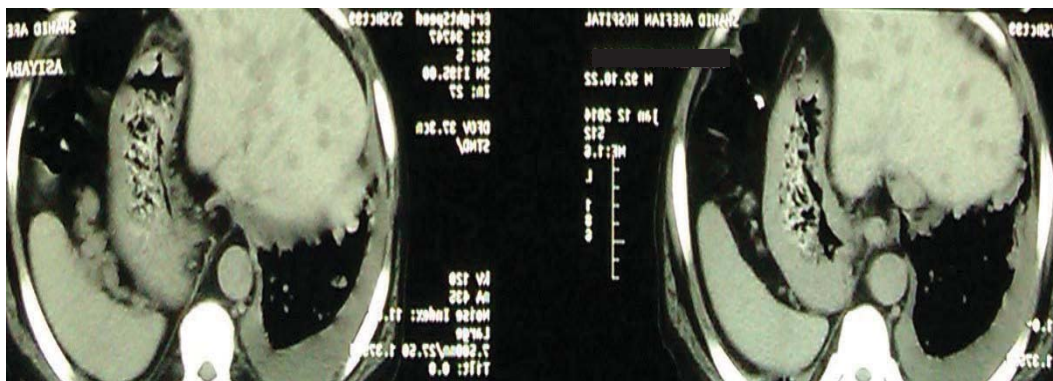


Figure 3. Abdominal CT scan: Multiple round, hypodense opacities in liver

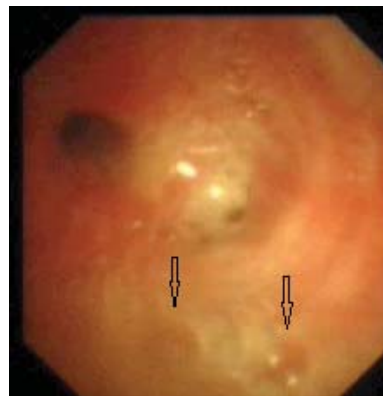


Figure 4. Endobronchial lesion (arrows)

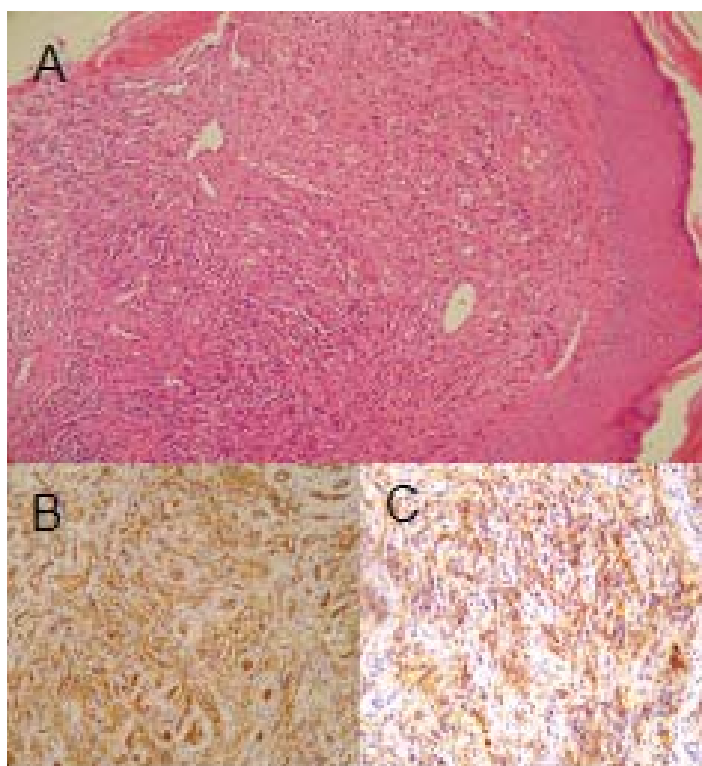


Figure 5. A) H&E staining of skin biopsy B) IHC for CD31 (×100); and C) IHC for CD30 (×100)

tation KS was estimated at about 0.5% (range 0.06% to 4.1%).⁶

Larger studies have described Kaposi's sarcomas following renal transplantation. Usually, Kaposi's sarcomas was localized in the skin, but visceral involvement such as lymph node, uterine cervix, gum, tonsils, lung and heart were also demonstrated.⁷ Because of the low immunosuppression in renal transplant, visceral involvement are expected in low frequent. In their case report, Ghorbani, et al. reported a 38-year-old man with isolated pulmonary Kaposi's sarcoma 6 months after renal transplant. He died due to intra-alveolar hemorrhage.⁸

It is important to note that 90% of kidney transplants with KS have skin and / or mucosal lesions. Primary visceral involvement and their clinical manifestations are unusual, extremely rare, and occur in 10% of recipients.⁸ Reduction or withdrawal of immunosuppressive therapy caused complete remission of KS in most patients.⁹ The conversion of calcineurin inhibitors such as Cyclosporine or Tacrolimus to Sirolimus (because of antiproliferative properties) is the most effective treatment.¹⁰⁻¹² For patients who do not respond, the choice of therapy with a second-line agent (vinblastin alone or in combination with bleomycin, paclitaxel, oral etoposide, and gemcitabine) must be individualized, and patients ages and co-morbidity must be taken into account.¹³ In this case we described an unusually aggressive and extensive KS with pulmonary, gastrointestinal and liver involvement. According to our knowledge, the report of disseminated KS is common in AIDS, but it is rare after solid organ transplant.

In conclusion, kaposi's sarcoma should be considered as an important differential diagnosis in skin lesion of patients after solid organ transplantation. Although skin lesions are the most common manifestation of KS but related to serious prognosis of visceral KS, we suggest systemic evaluation and visceral assessment in all patients with Cutaneous KS before any presentation.

Systemic chemotherapy after immunosuppressive reduction or its withdrawal may be necessary.

References

- Lebbé C, Legendre C, Francès C. Kaposi sarcoma in transplantation. *Transplantation Reviews*. 2008; 22: 252 – 261.
- Prokop AB, Ignacak E, Kuzniewski M, Kruszyna T, Okon K, Sulowicz W. Isolated intestinal Kaposi's sarcoma in a kidney transplant patient: Diagnostic difficulty. *Nephro-Urology Mon*.2011; 3(3): 204 – 206.
- Euvrard S, Kanitakis J, Claudy A. Skin cancers after organ transplantation. *N Engl J Med*. 2003; 348: 1681.
- Morris AK, Valley AW. Overview of the management of AIDS-related Kaposi's sarcoma. *Ann Pharmacother*. 1996; 30(10): 1150 – 1163.
- Penn I. The changing pattern of posttransplant malignancies. *Transplant Proc*. 1991; 23(1 Pt 2): 1101 – 1103.
- Euvrard S, Kanitakis J, Claudy A. Skin cancers after organ transplantation. *N Engl J Med*. 2003; 348(17): 1681 – 1691.
- Einollahi B. Unusual site of Kaposi sarcoma after kidney transplantation. *Iranian Journal of Kidney Diseases*. 2012; 6(3): 164 – 165.
- Ghorbani A, Mozafari A, Karimi S, Ehsanpour A, Aref A. Isolated primary pulmonary Kaposi's sarcoma in a renal transplant recipient: A case report. *Transplant Proc*. 2007; 39(10): 3471 – 3473.
- Costa Ferreira P, Miguel Pereira J, Oliveira I, Pinho C, Cardoso A, Reis J, et al. Unusual Kaposi's sarcoma in a renal transplant recipient. *Nephrol Dial Transplant*. 2005; 20(12): 2830 – 2831.
- Charfi S, Krichen-Makni S, Yaich S, Makni H, Khabir A, Amouri A, et al. Successful treatment of post-renal transplant gastric and pulmonary Kaposi's sarcoma with conversion to rapamycin treatment. *Saudi J Kidney Dis Transpl*. 2007; 18(4): 617 – 620.
- Campistol JM, Schena FP. Kaposi's sarcoma in renal transplant recipients--the impact of proliferation signal inhibitors. *Nephrol Dial Transplant*. 2007; 22(Suppl 1): i17 – i22.
- Stallone G, Schena A, Infante B, Sirolimus for Kaposi's sarcoma in renal-transplant recipients. *N Engl J Med*. 2005; 352: 1317 – 1323.
- Brambilla L, Miedico A, Ferrucci S. Combination of vinblastine and bleomycin as first line therapy in advanced classic Kaposi's sarcoma. *J Eur Acad Dermatol Venereol*. 2006; 20: 1090.