

# DatSCAN In Differential Diagnostics of Lewy Body Disease

Jan Luzny MD PhD<sup>1</sup>, Katerina Ivanova MD<sup>2</sup>

## Abstract

Differential diagnosis between Lewy body disease and Alzheimer's disease might be difficult because of similarities of clinical symptoms in both neurodegenerative diseases. DatSCAN is a modern functional neuroimaging method which differentiates between these similar diseases and helps in correct treatment strategy. We report our positive experience with DatSCAN in differentiating Lewy body disease from Alzheimer's disease. This is a case report of a woman with Lewy body disease, initially diagnosed as Alzheimer's disease. DatSCAN neuroimaging method was used in differential diagnosis of dementia. Memory impairment, impaired activities of daily living, sleep and behavioral disturbances were present in our case. Donepezil was well tolerated, but haloperidol administration was followed by development of severe dystonia. DatSCAN showed deficient dopaminergic presynaptic transport in substantia nigra and striatum. This finding is typical for Lewy body disease not for Alzheimer's disease. DatSCAN neuroimaging is a suitable method for differentiating Lewy body disease from Alzheimer's disease. Deficient dopaminergic presynaptic transport in substantia nigra and striatum is typical for Lewy body disease.

**Keywords:** Alzheimer's disease, DatSCAN, differential diagnosis, Lewy body disease, SPECT

Cite this article as: Luzny J, Ivanova K. DatSCAN In Differential Diagnostics of Lewy Body Disease. *Arch Iran Med.* 2016; **19**(6): 449 – 452.

## Introduction

Neurodegenerative dementias are pandemic noncommunicable diseases leading to memory impairment, behavioral changes and deterioration of functional status.<sup>1,2</sup> The prevalence of dementias increases as a result of demographic aging of populations in developed countries.<sup>3</sup> Differential diagnosis between Lewy body disease and Alzheimer's disease might be difficult in routine clinical practice.<sup>4</sup> Both neurodegenerative dementias are very frequent. Both Lewy body disease and Alzheimer's disease influence autonomy, functional status and life quality in affected individuals and their relatives.<sup>5,6</sup> Initially, both these neurodegenerative diseases have similar clinical symptoms (memory impairment, impaired activities of daily life, sleep and emotional disturbances); this makes concise diagnosis difficult.<sup>7,8</sup> However, treatment of these clinical categories needs different strategies. For instance, using antipsychotics is hazardous in Lewy body disease because of serious extrapyramidal side effects, whereas they might be helpful in treatment of behavioral disturbances in Alzheimer's disease.<sup>9</sup> On the contrary, using antidepressants might be helpful in Lewy body disease, whereas antidepressants show little or no clinical effect in Alzheimer's disease.<sup>10</sup> The obvious difference between Lewy body disease and Alzheimer's disease is in DatSCAN neuroimaging.<sup>11,12</sup> Presynaptic dopaminergic neurotransmission (dopamine transporter, DAT) in substantia nigra and striatum is typically deficient in Lewy body disease, whereas there is no deficit in dementia of Alzheimer's type.<sup>13,14</sup> Details are shown in Table 1 (Table 1; Figure 1).

DatSCAN is a modern functional neuroimaging method. In this procedure, radioactive iodine traced ligand (ioflupane) is used.

**Authors' affiliations:** <sup>1</sup> Mental Hospital in Kromeriz, Czech republic. <sup>2</sup> Department of Social Medicine and Public Health, Faculty of Medicine, Palacky University Olomouc, Czech Republic.

•**Corresponding author and reprints:** Jan Lužný MD PhD, Department of Psychogeriatrics, Mental hospital in Kromeriz, Havlickova 1265 Kromeriz 767 40, Czech Republic. Tel: +420 573 314 111, E-mail: honza.luzny@centrum.cz

Accepted for publication: 2 April 2016

Chemically, ioflupane is [N-<sup>125</sup>I-fluoropropyl-2a-carbomethoxy-3a-(4-iodophenyl)nortropane].<sup>15</sup> This ligand binds to presynaptic dopaminergic transporter (DAT), that is the reason why ioflupane is called presynaptic tracer binder.<sup>16</sup> As mentioned above, different DatSCAN findings in substantia nigra and striatum show the typical difference between Lewy body disease and Alzheimer's disease. For details, see below (Table 2, Figure 2 and Table 3, Figure 3).

DAT - presynaptic dopaminergic transporter, D1R, D2R - dopaminergic receptors.

DatSCAN in a healthy control – Figure A – symmetry in DAT-SPECT binding, DatSCAN in Parkinson disease – Figure B – symmetry in DAT-SPECT binding, DatSCAN in Alzheimer's disease – Figure C – symmetry in DAT-SPECT binding, and DatSCAN in Lewy body disease – Figure D – asymmetry and deficit in DAT-SPECT binding.

## Objective

We report our positive experience with DatSCAN in differentiating Lewy body disease from Alzheimer's disease.

## Case Report

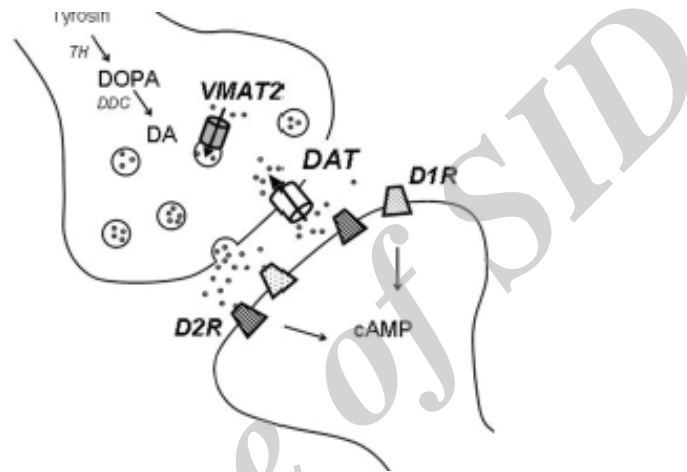
Case report of a woman with memory impairment, impaired activities of daily living, sleep and emotional disturbances

## Patient history

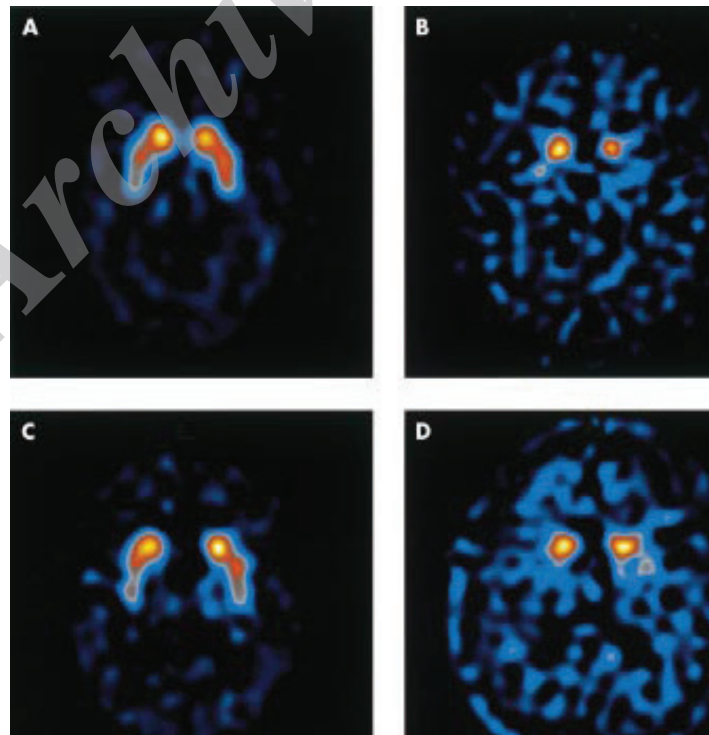
Our patient was a woman, 85 years old, teacher, widowed, with two adult children, and no former psychiatric history. She had a history of arterial hypertension since 1990 treated with ramipril (5 mg daily). She had no other diseases in her medical records. Since January 2012, she reported gradual memory impairment, sleep disturbances, anxiety and anhedonia. The patient complained of impaired instrumental activities of daily living (housework, shopping, using the credit card since March 2013). In November 2013, she was admitted to a mental hospital in Kromeriz, Czech Republic, for moderate dementia with anxiety, depression and sleep disturbances.

**Table 1.** Lewy Body Disease vs Alzheimer's disease (according to 3, 4).

Basic characteristics	Lewy Body Disease	Alzheimer's disease
Memory impairment	Gradual and pathognomonic	Gradual and pathognomonic
Activities of daily living	Impaired	Impaired
Sleep disturbances	Can be	Can be
Emotional disturbances	Can be	Can be
Behavioral symptoms	Can be	Can be in later stage
Psychotic symptoms	Can be	Not common
Risk of falls	Often	Can be
Use of antipsychotics	Hazardous (extrapyramidal adverse effects)	Can be helpful when dosing with care
Use of cholinesterase inhibitors	Not constant effect	Helpful
Use of serotonergic antidepressants	Helpful	Not constant effect
DatSCAN - DAT neurotransmission	Deficient	No deficit



**Figure 1.** Presynaptic dopaminergic transporter and dopaminergic receptors.



**Figure 2.** DatSCAN in a healthy control, Parkinson disease, Alzheimer's disease and Lewy body disease (D - asymmetry and deficit in DAT-SPECT binding).

### Diagnostic process and initial therapy

Personal data and patient history were taken. Routine laboratory checks showed no pathological values including thyroid parameters, which we take routinely for differential diagnostic reasons.<sup>17,18</sup> Initial MMSE score (Mini-Mental Examination score) for rough evaluation of cognitive status was 14, correlating with moderate dementia).

Computerized tomography of the brain (done 5.11.2013) showed global atrophy of the cerebral cortex. Taking into account the personal data, patient history (memory impairment, impaired activities of daily living, sleep and emotional disturbances) and clinical picture, we established a diagnosis of Alzheimer's disease according to ICD-10 (International classification of disease) diagnostic criteria, which are valid in the Czech Republic.

### Initial therapy

We initially administered 5 mg donepezil (cholinesterase inhibitor, used by the patient before for treating arterial hypertension) and her antihypertensive medication. Because of serious behavioral disturbances (night wandering in ward, disturbing other patients – lying down in beds of other patients). we had to use 2.5 mg haloperidol in intramuscular injection. On another day, the patient suffered from dystonia: she could not move and she had problems with swallowing the food. We had to make adjustments in therapy (we continued only donepezil) and we planned further examination (DatSCAN). Because of strong extrapyramidal reaction to antipsychotics, we considered Lewy body disease.

### DatSCAN findings

DatSCAN showed deficient dopaminergic presynaptic transport in substantia nigra and striatum. This finding is typical for Lewy body disease but not for Alzheimer's disease.

### Corrections in therapy and clinical progress

We continued with 5 mg daily donepezil (cholinesterase inhibitor) administration. Sleep disturbances were corrected with 75 mg daily trazodone (serotonergic antidepressant). No antipsychotics were used any more. Anxiety, anhedonia and sleep disturbances disappeared, no behavioral disturbances were detected since the beginning of December. Memory impairment improved (MMSE score 19) in the middle of December 2013. At the end of December, the patient felt well and was discharged.

## Discussion

A diagnosis of Alzheimer's disease was initially established because of fulfillment of ICD-10 diagnostic criteria for this diagnosis. According to literature<sup>1,3,4</sup> our diagnosis justified memory impairment, impaired activities of daily living, sleep and emotional disturbances, Computerized tomography of the brain showed global cerebral atrophy, Mini-Mental Examination score achieved by the patient was 14. Similar findings are routinely detected in many cases of Alzheimer's disease by different authors.<sup>19,20</sup> According our opinion, the use of cholinesterase inhibitors was correct as well as the use of haloperidol for behavioral disturbances correction. Similar management of therapy was described by many authors. Consequent adverse extrapyramidal effects of therapy (dystonia, disturbances with swallowing) led us to a diagnosis of Lewy body disease. Lennox *et al.* report the same experience of extrapyramidal hypersensitivity in Lewy body disease.<sup>21</sup>

Unfortunately, clinical symptomatology could not differentiate Alzheimer's disease from Lewy body disease in our case because of similarities of clinical symptoms in both diseases. Both Alzheimer's disease and Lewy body disease are common in the elderly. Lewy body disease is said to be the second most frequent type among neurodegenerative dementias.<sup>1,4</sup> DatSCAN showed us deficient dopaminergic presynaptic transport in substantia nigra and striatum in our case which supported the diagnosis of Lewy body disease. Together with extreme sensitivity to haloperidol, a correct diagnosis of Lewy body disease could be established.

In conclusion, differentiating between Lewy body disease and Alzheimer's disease might be difficult in routine clinical practice. All clinicians should be aware of this difficulty and consider Lewy body disease. DatSCAN neuroimaging is a suitable method for differentiating Lewy body disease from Alzheimer's disease. Deficient dopaminergic presynaptic transport in substantia nigra and striatum is typical for Lewy body disease.

**Financial or other competing interests:** None

## References

1. Gardner RC, Valcour V, Yaffe K. Dementia in the oldest old: a multifactorial and growing public health issue. *Alzheimers Res Ther.* 2013; 5(4): 27.
2. Lužný J, Bellová J, Doněk E. Does gerontopsychiatry belong to medicine? Cross sectional study monitoring polymorbidity in hospitalized gerontopsychiatric patients. *Biomed Pap Med Fac Univ Palacky Czech Repub.* 2010; 154(1): 89 – 92.
3. Lužný J. *Gerontopsychiatrie [Psychogeriatry]*. 1st ed. Praha: Triton; 2012: 159.
4. McKeith IG. Dementia with Lewy bodies. *Br J Psych.* 2002; 180: 144 – 147.
5. Lužný J, Ivanová K. Quality of life in hospitalized seniors with psychiatric disorders. *Biomed Pap Med Fac Univ Palacky Czech Repub.* 2009; 153(4): 1 – 4.
6. Lužný J. Kvalita života u pacientů s demencí. [Quality of Life in Patients With Dementia]. *Cesk Slov Neurol N.* 2013; 76(1): 90 – 95.
7. Ballard C, Aarsland D, Francis P, Corbett A. Neuropsychiatric symptoms in patients with dementias associated with cortical Lewy bodies: pathophysiology, clinical features, and pharmacological management. *Drugs Aging.* 2013; 30(8): 603 – 611.
8. Lužný J. Nefarmakologické ovlivnění kognitivních funkcí u klientů s demencí. [Nonpharmacological approaches in treatment of cognitive deficits in patients with dementia]. *Oš Por Asistence.* 2011; 2(4): 312 – 318.
9. Schwarz S, Froelich L, Burns A. Pharmacological treatment of dementia. *Curr Opin Psychiatry.* 2012; 25(6): 542 – 550.
10. Luzny J. Agomelatine in elderly – finally a patient friendly antidepressant in psychogeriatry. *Actas Esp Psiquiatr.* 2012; 40(6): 304 – 307.
11. Bertelson JA, Ajtai B. Neuroimaging of dementia. *Neurol Clin.* 2014; 32(1): 59 – 93.
12. Hanagasi HA, Bilgiç B, Emre M. Neuroimaging, biomarkers, and management of dementia with lewy bodies. *Front Neurol.* 2013; 4: 151.
13. Lavalaye J, Linszen DH, Booij J, Dingemans PM, Reneman L, Habraken JB, et al. Dopamine transporter density in young patients with schizophrenia assessed with [123I]FP-CIT SPECT. *Schizophr Res.* 2001; 47(2): 59 – 67.
14. Walker Z, Costa DC, Walker RW, Shaw K, Gacinovic S, Stevens T, et al. Differentiation of dementia with Lewy bodies from Alzheimer's disease using a dopaminergic presynaptic ligand. *J Neurol Neurosurg Psychiatry.* 2002; 73(2): 134 – 140.
15. O'Brien JT, Colloby S, Fenwick J, Williams ED, Firbank M, Burn D, et al. Dopamine transporter loss visualized with FP-CIT SPECT in the differential diagnosis of dementia with lewy bodies. *Arch Neurol.* 2004; 61(6): 919 – 925.
16. Plotkin M, Amthauer H, Klaffke S, Kühn A, Lüdemann L, Arnold G, et al. Combined 123I-FP-CIT and 123I-IBZM SPECT for the diagnosis of parkinsonian syndromes: study on 72 patients. *J Neural Transm.* 2005; 112(2): 677 – 692.

17. Lužný J, Ivanová K. Hypothyroidism in seniors hospitalized in inpatient psychogeriatric wards in mental hospital in Kroměříž. *Scripta Medica*. 2010; 1: 69 – 71.
18. Lužný J. Hodnocení bolesti u klientů se středně těžkou a těžkou demencí [Pain evaluation among clients with moderate and severe dementia]. *Oš Por Asistence*. 2013; 4(4): 678 – 683.
19. Lebouvier T, Delrieu J, Evain S, Pallardy A, Sauvaget A, Letournel F, et al. Dementia: Where are the lewy bodies? *Rev Neurol (Paris)*. 2013; 169(11): 844 – 857.
20. Ballard C, Kahn Z, Corbett A. Treatment of dementia with Lewy bodies and Parkinson's disease dementia. *Drugs Aging*. 2011; 28(10): 769 – 777.
21. Lennox G, Lowe JS, Godwin-Austen RB, Landon M, Mayer RJ. Diffuse Lewy body disease: an important differential diagnosis in dementia with extrapyramidal features. *Prog Clin Biol Res*. 1989; 317: 121 – 130.

Archive of SID