

Case Report

Pericardial Graft vs. Host Disease in a Patient with β -Thalassemia Major

Mehrdad Saravi MD¹, Mohsen Vakili Sadeghi MD², Hassan Mahmoodi Nesheli MD*³

Abstract

Bone marrow transplantation (BMT) in young children improves results in β -thalassemia major. Graft versus host disease (GVHD) is an important complication of peripheral blood stem cell transplantation. GVHD affects heart with a behavior resembling an autoimmune disease, including pericardial effusion.

We describe a 22-year-old β -thalassemia major patient who underwent bone marrow transplantation with an HLA-identical sibling donor. The patient didn't have any serious problem until 15 months after transplantation. He presented with chest discomfort and progressive dyspnea. Early echocardiogram showed mild pericardial effusion. Four days later, the effusion had increased, impeding to cardiac temponade requiring pericardectomy. Immunosuppressive drugs and pericardectomy resulted in significant improvement in ventricular filling.

Cardiac cGVHD, an un-common complication of HSCT may be presented as pericardial effusion. Although early initiation of steroids is very important, heart monitoring is necessary to diagnose cardiac temponade.

Keywords: BMT, β -thalassemia major, GVHD, HSCT, pericarditis

Cite this article as: Saravi M, Vakili Sadeghi M, Mahmoodi Nesheli H. Pericardial graft vs. host disease in a patient with β -thalassemia major. *Arch Iran Med.* 2016; **19(9)**: 674 – 676.

Introduction

Hematopoietic stem cell transplantation (HSCT) is a new window to therapy of many diseases. In Iran, HSCT has been successfully adapted in a routine clinical care.¹ HSCT in young children, before development of end-organ damage, improves results after transplantation for β -thalassemia major.² Many post-transplant complications including, acute graft versus host disease (GVHD), chronic GVHD (c GVHD), hemorrhagic cystitis, veno-occlusive disease (VOD) of liver, acute renal failure, and infections may occur.³ Many cardiac complications such as cardiomyopathies, pericarditis, heart failure, and arrhythmias may occur in HSCT. Drugs used in conditioning regimen in HSCT are responsible factors for the cardiac toxicity.^{4,5} GVHD may affect heart and many other organs in the body, with a behavior resembling an autoimmune disease, including serositis (pleural/pericardial effusion) and ascites.⁶ Also, cGVHD-associated serositis with or without pericarditis may occur mainly in the setting of treated as opposed to de novo chronic GVHD frequently in the setting of immunosuppression taper.⁷ GVHD is found as an important cause of death among other causes such as relapse, infections, and hemorrhagic cystitis, after bone marrow transplantation in many research centers.^{3,8} Several cardiac pathologic findings were seen in patients treated with bone marrow transplantation.⁵ Standard treatment of pericardial effusion (surgery and anti-inflammatory) offers poor results when recurrences occur.⁹

Authors' affiliations: ¹Department of Cardiology, Babol University of Medical Sciences, Babol, Iran, ²Department of Hematology, Babol University of Medical Sciences, Babol, Iran, ³Non-Communicable Pediatrics Diseases Research Center, Babol University of Medical Sciences, Babol, Iran.

Corresponding author and reprints: Hassan Mahmoodi Nesheli MD, Non-Communicable Pediatric Diseases Research Center, No 19, Amirkola Children's Hospital, Amirkola, Babol, Mazandaran Province, P. O. Box: 47317-41151, I. R. of Iran. Telefax: +98-11-32346963, E-mail: mahmoodi86@yahoo.com.

Accepted for publication: 2 March 2016

Case Report

BMT was performed for a 22-year-old patient with β -thalassemia major who had an HLA-identical sibling, in July 2011. Conditioning regimen was busulfan, fludarabine and antithymocyte globulin. The patient was discharged from hospital on day 25 post transplantation. There were no intestinal, liver or cutaneous acute GVHD (aGVHD) at that time. Cyclosporine (CYA) was administered as GVHD prophylaxis. Phlebotomy was done three times during the first 100 days of post transplantation, due to polycythemia. We decided to discontinue cyclosporine in the end of the first year of post transplantation. At that time oral cavity ulcer appeared. We considered this oral ulcer as a sign of graft vs. host disease. Gradually, sclerotic and erythematous skin lesions were progressed over the face and extremities. We treated these lesions as chronic GVHD with steroid and cyclosporine. He developed chest pain and progressive dyspnea 15 months after allogeneic peripheral blood stem cell transplantation. Vital signs revealed sinus tachycardia (110 beat per minute), and normal blood pressure (120/60 mmHg). Heart sounds were normal. Surface electrocardiogram showed ST elevation in all leads, except V1 and aVR (Figure 1). Chest X-ray showed right-sided pleural effusion with clear lung fields and mild cardiomegaly. Trans-thoracic echocardiography showed the left ventricular ejection fraction of 55%, a thickened pericardium with mild pericardial effusion posterior of the left ventricle and anterior of the right ventricle without chamber collapse. Patient treated with CYA, mycophenolate mofetil (MM), and high dose corticosteroid. Four days later, the effusion had increased significantly (Figure 2) accompanying with chamber collapse and hypotension. We concluded that pericardial effusion occurred due to pericarditis and was considered as a manifestation of chronic GVHD in this patient. The patient underwent a pericardiocentesis, evacuating approximately 250 mL of bloody pericardial fluid, which

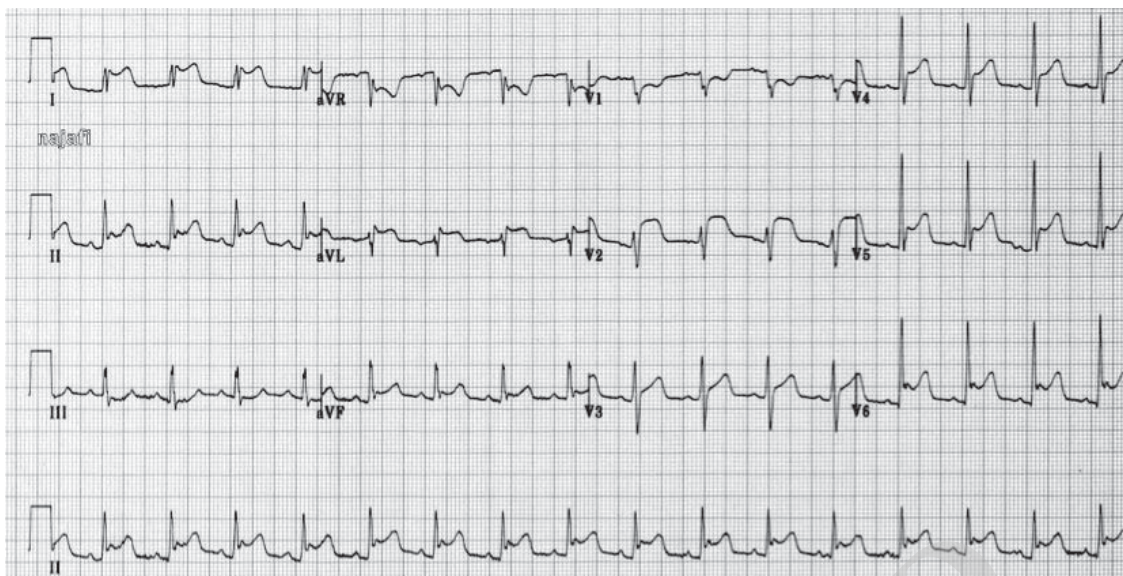


Figure 1. Electrocardiogram showed low voltage and ST elevation.

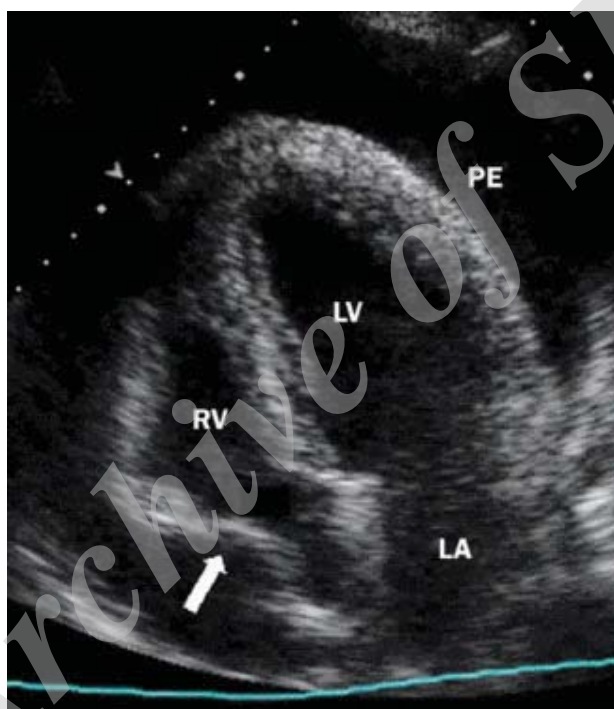

Figure 2. Trans-thoracic echocardiography showed significant pericardial effusion.

contained numerous lymphocytes, inflation, but no granulomatous cells. It was nonspecific suggesting of the inflammatory process and cGVHD. All microbiological studies (PCR for detection of CMV, herpes simplex I and II, human herpes 6, Epstein-Barr and varicella-zoster; bacterial, mycobacterial and fungal microscopy and culture) were negative. After two days, trans-thoracic echocardiography showed a significant increase of the pericardial effusion. The patient was impending to cardiac tamponade requiring pericardectomy. Pericardectomy resulted in significant improvement in ventricular filling. The pericardial drainage tube was withdrawn after 5 days, and the patient was discharged from hospital on day 15. Treatment with prednisolone, MM and CYA was continued. Skin GVHD didn't improve with resolution of pericardial effusion. The patient had no cardiac problems after that.

Discussion

cGVHD is a common complication of HSCT, but rarely affects the heart. Cardiac cGVHD was characterized by insidious onset and mimics other pathologic factors. Manifestations of cardiac GVHD include pericardial effusion, coronary artery disease, and conduction disturbances. Although early initiation of steroids is very important, heart monitoring is necessary to diagnose cardiac tamponade. If the patient is impending to cardiac tamponade, pericardectomy should be done immediately. Our patient complicated cardiac GVHD, 15 months after BMT. Some study showed cardiac GVHD may be happened more than 15 months after allogeneic peripheral blood stem cell transplantation.¹⁰ Angelucci reported a case of acute cardiac tamponade without concurrent myocardial disease that occurred early after bone

marrow transplantation in a thalassemia patient.¹¹ Sclerotic and erythematous skin lesions on the face and extremities can help the diagnosis of cardiac cGVHD. It is important to rule out infections as a cause of pericarditis as same as Aoyama's report. In their study, Aoyama, et al. reported pericarditis associated with EBV reactivation after allogeneic-stem cell transplantation.¹² Pericardial constriction and restrictive cardiomyopathy should be considered as causes of breathlessness and/or edema that occur late after BMT.¹³ Silberstein described a man with Hodgkin's disease who was transplanted from an HLA-identical brother, who developed cGVHD and constrictive pericarditis, 1 month after BMT.¹⁴ Jenner reported a successful response to infliximab of recurrent pericardial graft versus host disease, which we didn't use.⁹

In conclusions, cardiac cGVHD is an uncommon complication of HSCT. It may manifest as insidious onset and mimic other pathologic factors. Cardiac GVHD may present as pericardial effusion, coronary artery disease and conduction disturbances. Although early initiation of steroids is very important, heart monitoring is necessary to diagnose cardiac tamponade. If the patient is impending to cardiac tamponade, pericardectomy should be done immediately.

References

- Ghavamzadeh A, Alimoghaddam K, Ghaffari F, Derakhshandeh R, Jalali A, Jahani M. Twenty years of experience on stem cell transplantation in Iran. *Iran Red Crescent Med J.* 2013; 15(2): 93 – 100.
- Sabloff M, Chandy M, Wang Z, Logan BR, Ghavamzadeh A, Li CK, et al. HLA-matched sibling bone marrow transplantation for beta-thalassemia major. *Blood.* 2011; 117(5): 1745 – 1750.
- Ullah K, Ahmed P, Raza S, Satti T, Nisa Q, Mirza S, et al. Allogeneic stem cell transplantation in hematological disorders: single center experience from Pakistan. *Transplant Proc.* 2007; 39(10): 3347 – 3357.
- Cazin B, Gorin NC, Laporte JP, Gallet B, Douay L, Lopez M, et al. Cardiac complications after bone marrow transplantation. A report on a series of 63 consecutive transplantations. *Cancer.* 1986; 57(10): 2061 – 2069.
- Buja LM, Ferrans VJ, Graw RG. Cardiac pathologic findings in patients treated with bone marrow transplantation. *Hum Pathol.* 1976; 7(1): 17 – 45.
- Jenner MJ, Micallef IN, Rohatiner AZ, Kelsey SM, Newland AC, Cavenagh JD. Successful therapy of transplant-associated veno-occlusive disease with a combination of tissue plasminogen activator and defibrotide. *Med Oncol.* 2000; 17(4): 333 – 336.
- Jessica and Leonard, Chronic Gvhd-Associated Serositis and Pericarditis, Internal Medicine, Oregon Health & Science University.
- Ghavamzadeh A, Alimoghaddam K, Jahani M, Mousavi SA, Irvani M, Bahar B, et al. Stem cell transplantation; Iranian experience. *Arch Iran Med.* 2009; 12(1): 69 – 72.
- Rubio PM, Labrandero C, Riesco S, Plaza D, Gonzalez B, Munoz GM, et al. Successful response to infliximab of recurrent pericardial graft versus host disease in a pediatric patient. *Bone Marrow Transplant.* 2013; 48 (1): 144 – 145.
- Saito Y, Matsushima T, Doki N, Tsumita Y, Takizawa M, Yokohama A, et al. Pericardial graft versus host disease in patient with myelodysplastic syndrome following peripheral blood stemcell transplantation. *Eur J Haematol.* 2005; 75(1): 66 – 67.
- Angelucci E, Mariotti E, Lucarelli G, Baronciani D, Baldassarri M, Cesaroni P, et al. Cardiac tamponade in thalassemia. *Bone Marrow Transplant.* 1994; 13(6): 827 – 829.
- Aoyama Y, Nakao Y, Ohta K, Sakai T, Nakamae H, Yamamura R, et al. Pericarditis associated with Epstein-Barr virus reactivation in a patient following allogeneic peripheral blood stem cell transplantation from an HLA genotypic 1-locus mismatched sibling donor. *Leuk Lymphoma.* 2004; 45(2): 393 – 395.
- Cavet J, Lennard A, Gascoigne A, Finney RD, Lucraft HH, Richardson C, et al. Constrictive pericarditis post allogeneic Bone Marrow Transplantation for Philadelphia positive acute lymphoblastic leukemia. *Bone Marrow Transplant.* 2000; 25(5): 571 – 573.
- Silberstein L, Davies A, Kelsey S, Foran J, Murrell C, D'Cruz D, et al. Myositis, polyserositis with a large pericardial effusion and constrictive pericarditis as manifestations of chronic graft-versus-host disease after non-myeloablative peripheral stem cell transplantation and subsequent donor lymphocyte infusion. *Bone Marrow Transplant.* 2001; 27(2): 231 – 233.