

Original Article

***Enterobius vermicularis*: A Cause of Abdominal Pain Mimicking Acute Appendicitis in Children. A Retrospective Cohort Study**

Mohamed Zouari, MD¹; Hamid Louati, MD¹; Imen Abid, MD, FACS¹; Fatma Trabelsi, MD¹; Mahdi Ben Dhaou, MD¹; Mohamed Jallouli, MD, FACS¹; Riadh Mhiri, MD¹

¹Department of Pediatric Surgery, Hedi Chaker Hospital, 3029 Sfax, Tunisia

Abstract

Background: *Enterobius vermicularis* (EV) is the most common helminthic infection in the world. This small parasite is predominant in the pediatric population. The presence of EV in the appendix can cause or mimic appendicitis. The aim of our study was to compare patients with EV infection and those without EV infection, and to identify predictive factors that may help the diagnosis of EV infection in patients presenting with right iliac fossa pain and avoid negative appendectomy.

Methods: A retrospective analysis of all the appendices removed between January 2012 and December 2016 was conducted at the department of pediatric surgery, Hedi Chaker Hospital, Sfax, Tunisia. According to the final histopathological diagnosis, patients with EV infection were compared to those without EV infection. Data including age, sex, white blood cell (WBC) count, neutrophil count, eosinophil count, C-reactive protein, and ultrasound results for both groups were analyzed and compared. The study protocol was approved by the local hospital ethics committee. Statistical analysis was performed using IBM SPSS, version 20. Descriptive analysis in the form of mean and standard deviation was performed on demographic information. Differences between groups were assessed using the student t-test for continuous variables and the χ^2 test and Fisher exact test where appropriate for categorical variables.

Results: In total, 540 pediatric appendectomies were performed. Overall, 63.5% of patients were male and 36.5% were female. Mean age was 9.28 ± 2.77 years. 22.2% of procedures were completed laparoscopically, 76.5% were open and 1.3% were converted. The negative appendectomy rate was 11.1%. EV was present in 9.8% of cases. Comparison of clinical, biological, and ultrasound findings between two groups of patients with EV (EV+) and those without EV (EV-) shows a statistical significance for pruritus ani ($P < 0.001$), WBC count ($P < 0.001$), neutrophil count ($P < 0.001$), C-reactive protein (CRP) ($P = 0.001$), positive ultrasound ($P < 0.001$), perforation rate ($P = 0.009$), and negative appendectomy rate ($P < 0.001$). No significant difference between the two groups was seen when comparing gender ($P = 0.271$), vomiting ($P = 0.130$), eosinophil count ($P = 0.915$), and procedure ($P = 0.536$).

Conclusion: EV was seen in 9.8% of pediatric appendectomies in our study. Pruritus ani, normal WBC count, normal neutrophil count, and normal CRP level at presentation could predict EV infection in children who present with right iliac fossa pain.

Keywords: Abdominal pain, Acute appendicitis, Appendectomy, Children, *Enterobius vermicularis*

Cite this article as: Zouari M, Louati H, Abid I, Trabelsi F, Ben Dhaou M, Jallouli M, et al. *Enterobius vermicularis*: a cause of abdominal pain mimicking acute appendicitis in children. A retrospective cohort study. Arch Iran Med. 2018;21(2):67-72.

Received: August 2, 2016, Accepted: January 28, 2018, ePublished: February 1, 2018

Introduction

Enterobius vermicularis (EV), also known as *Oxyuris vermicularis* or pinworm, is the most common helminthic infection in the world.^{1,2} This small parasite is predominant in pediatric populations with around 4% to 28% of children infected. EV inhabits the cecum and has occasionally been reported in the appendix.³ The role of this parasite in pathogenesis of appendicitis still initiates controversy.⁴ The presence of EV in the appendix can cause or mimic appendicitis due to obstructive phenomena,⁵ but there is frequently no histological evidence of acute inflammation.⁶⁻⁹ The aim of our study was to compare patients with EV infection and those without EV infection and to identify predictive factors

that may help diagnosis of EV infection in patients presenting with right iliac fossa pain and avoid negative appendectomy.

Materials and Methods**Study Design**

In this retrospective study, the records of our department of pediatric Surgery were searched to identify all patients who underwent appendectomy to treat an initial diagnosis of acute appendicitis (AA) between January 2012 and December 2016 at the department of pediatric surgery, Hedi Chaker Hospital, Sfax, Tunisia. In our unit, the initial diagnosis of AA is obtained by clinical assessment and confirmed by laboratory blood tests and imaging

(ultrasound or computed tomography) when the surgeon deems it necessary. Patients older than 14 years, patients with previous history of open abdominal or pelvic operations, patients with preoperative clinical evidence of bowel perforation, and patients with appendices removed during the course of another intra-abdominal procedure were excluded from the study. In our hospital, appendectomy specimens are routinely sampled for microscopic examination, with representative sections including the tip and two cross sections from the base and body of the appendix. The recorded data extracted for each patient included age, sex, clinical presentation, white blood cell (WBC) count, neutrophil count, eosinophil count, C-reactive protein (CRP), ultrasound results, and macroscopic and microscopic properties of appendix vermicularis. The surgeon's diagnosis, clinical findings and pathology report were reviewed to ascertain whether the clinical diagnosis correlated with the histopathological diagnosis or whether the latter provided new information.

According to the final histopathological diagnosis, our patients were classified into four groups as illustrated in Figure 1. Normal ranges of WBC and eosinophil counts were considered between 4000 and 10000/ μ L for WBC count and between 0 and 700/ μ L for eosinophil count according to our laboratory normal ranges. CRP levels were measured by a highly sensitive immunonephelometric method; the upper reference limit for CRP was 6.0 mg/L. According to ultrasound results, patients were diagnosed "positive" for AA if the appendiceal diameter measured ≥ 6 mm and "negative" if measured < 6 mm or the appendix was not identified.

Follow-up of the Patients

On discharge, the patients were assessed in the outpatient surgical department on the 15th postoperative day. Subsequent follow-up visits were scheduled at 3 months and 9 months after surgery. Furthermore, the patients were advised to report immediately to the emergency department of the hospital in case of signs of

postoperative complications.

Data Analysis

Statistical analysis was performed using IBM SPSS, version 20. Descriptive analysis in the form of mean and standard deviation was performed on demographic information. Differences between groups were assessed using the student *t* test for continuous variables and the χ^2 test and Fisher's exact test where appropriate for categorical variables. Statistical significance was accepted as $P < 0.05$.

Results

Clinical, Biological, and Ultrasound Findings

A total of 540 pediatric appendectomies were performed over the four-year period of this study. Overall, 63.5% of patients were male ($n=343$) and 36.5% were female ($n=197$). Mean age at presentation was 9.28 years (range 3–14 years; $SD \pm 2.77$). All patients presented with right iliac fossa pain, 439 (81.3%) patients presented with vomiting, and 12 (2.2%) patients presented with pruritus ani. Leukocytosis was found in 418 patients (77.4%), neutrophilic leukocytosis was found in 386 patients (71.5%), and positive CRP was found in 317 patients (58.7%). Abdominal ultrasound scan was performed in 371 patients (68.7%). Ultrasound findings and performance were shown in Table 1 and Table 2, respectively.

Operative Procedures

Four hundred and thirteen appendectomies (76.5%) were performed open (mean age 9.4 years, range 3–14) and 22.2% ($n=120$) were completed laparoscopically (mean age 8.9 years, range 4–14). Seven appendectomies (1.3%) were converted from laparoscopic to open due to technical difficulty. The difference between perforation rates of open group patients and laparoscopic group patients was not statically significant (10.4% and 10.2% respectively, $P=0.955$).

Appendiceal Histopathology Results

On histopathological analysis 88.9% of specimen showed varying evidence of AA, giving an 11.1% negative appendectomy rate. Overall, suppurative appendicitis was evident in 54.4% and perforation in 10.4%. EV was present in 9.8% of cases. Faecoliths were found in 7.7% (37/480) of appendicitis specimens and 3.3% (2/60) of negative appendectomies ($P=0.217$).

Factors Predicting the Presence of EV

The comparison of clinical, biological, and ultrasound findings between two groups of patients with EV (EV+) and those without (EV-) shows a statistical significance

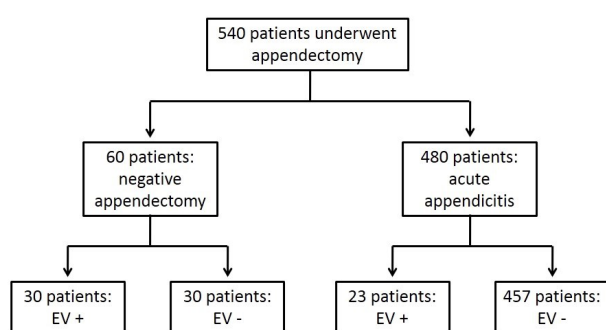


Figure 1. Classification of Patients According to the Final Histopathological Diagnosis.

Table 1. Table Demonstrating Relative Accuracy of Ultrasound for Detecting Acute Appendicitis in Patients With EV Infestation Versus Those Without

EV Present				EV Absent			
39				332			
Ultrasound Positive		Ultrasound Negative		Ultrasound Positive		Ultrasound Negative	
20		19		272		60	
True Positive	False Positive	True Negative	False Negative	True Positive	False Positive	True Negative	False Negative
14	6	14	5	262	10	11	49

Abbreviations: EV, *Enterobius vermicularis*.**Table 2.** Diagnostic Performance of Ultrasound for Appendicitis With Regard to Presence or Absence of EV Infection of the Appendix

Diagnostic Performance % (95% CI)		
Ultrasound	EV Present	EV Absent
Sensitivity	74 (49–91)	84 (80–88)
Specificity	70 (46–88)	52 (30–74)
PPV	70 (53–83)	96 (94–98)
NPV	74 (56–86)	18 (12–27)
Diagnostic accuracy	72 (55–85)	82 (78–86)

Abbreviations: EV, *Enterobius vermicularis*; PPV, positive predictive value; NPV, negative predictive value.

for pruritus ani ($P < 0.001$), WBC count ($P < 0.001$), neutrophil count ($P < 0.001$), CRP ($P = 0.001$), positive ultrasound ($P < 0.001$), perforation rate ($P = 0.009$), and negative appendectomy rate ($P < 0.001$). No significant

difference between the two groups was seen when comparing gender ($P = 0.271$), vomiting ($P = 0.130$), eosinophil count ($P = 0.915$), and procedure ($P = 0.536$) (Table 3).

Comparison Between 2 Subgroups of Patients With Negative Appendectomy

In the presence of EV, only 43.4% ($n = 23$) had evidence of AA. This resulted in a negative appendectomy rate of 56.6% in the presence of EV compared to a 11.1% overall ($P < 0.001$). The comparison between the EV group (negative appendectomy with EV+) and the control group (negative appendectomy with EV-) in terms of pruritus ani showed a significant difference ($P = 0.020$). There were no statistical differences in gender ($P = 0.602$), vomiting ($P = 0.390$), WBC counts

Table 3. Comparison of Clinical, Biological, and Ultrasound Characteristics of Patients With EV and Those Without

		EV+		EV-		P Value
		No.	%	No.	%	
Gender	Male	30	56.6	313	64.3	0.271
	Female	23	43.4	174	35.7	
Vomiting	Yes	39	73.6	400	82.1	0.13
	No	14	26.4	87	17.9	
Pruritus ani	Yes	7	13.2	5	1	<0.001
	No	46	86.8	482	99	
Leukocytosis	Yes	26	49	392	80.5	<0.001
	No	27	51	95	19.5	
Neutrophilic leukocytosis	Yes	21	39.6	365	74.9	<0.001
	No	32	60.4	122	25.1	
Eosinophilia	Yes	2	3.8	17	3.6	0.915
	No	51	96.2	470	96.4	
CRP	≥6 mg/L	20	37.7	297	61	0.001
	<6 mg/L	33	62.3	190	39	
Ultrasound	Positive	20	51.3	272	81.9	<0.001
	Negative	19	48.7	60	18.1	
Procedure	Open	43	81.1	377	77.4	0.536
	Laparo	10	18.9	110	22.6	
Perforation	Yes	0	0	56	11.5	0.009
	No	53	100	431	88.5	
Negative appendectomy	Yes	30	56.6	30	6.2	<0.001
	No	23	43.4	457	93.8	

Abbreviations: EV+, *Enterobius vermicularis* present; EV-, *Enterobius vermicularis* absent; CRP = C-reactive protein.

($P=0.605$), eosinophil counts ($P=0.694$), and CRP ($P=0.438$) between the 2 groups.

Treatment of Patients With EV Infestation of the Appendix

All patients with EV infestation of the appendix were treated with antihelminthic drugs (Albendazole 400 mg once and to repeat after 1 week). Close family contacts were advised to take prophylactic treatment. There was complete resolution of the symptoms post anti-helminth treatment and no complications were noted at 2 months follow-up.

Discussion

AA is the most common abdominal surgical emergency in children.¹⁰⁻¹⁴ In most cases, AA is associated with luminal obstruction resulting in progressive increase in intraluminal pressure. This obstruction can be caused by fecalith, gallstone, tumor, or parasites including EV (most commonly), *Ascaris*, *Giardia*, and *Entamoeba histolytica*.^{7,15} The histology of AA is variable. Phlegmonous appendicitis is defined as neutrophilic infiltration of the appendiceal wall, with associated inflamed and ulcerated mucosa and often crypt abscesses. Gangrenous appendicitis has necrosis of the wall of the appendix in a background of transmural inflammation, often with extension into the mesoappendix; perforation may result if untreated.¹⁶⁻¹⁸

Majority of patients infected with EV are asymptomatic.¹⁹ Reported symptoms include intense pruritus in the perianal area that can lead to insomnia, restlessness, and irritability.²⁰ EV infestation of the appendix can produce clinical features of AA or "appendiceal colic"²¹⁻²³ but frequently without any histological evidence of acute inflammation.^{6-8,24}

EV is an obligate parasite infecting approximately 1000 million humans worldwide.²⁵ Although it is commonly held that EV, in contrast to other intestinal helminth infections, is more prevalent in temperate than tropical climates, there is a paucity of contemporary data to support this view. Well-recognized cofactors for increased risk of *Enterobius* infection include overcrowding, poor sanitation, and lack of water for bathing and washing of hands and clothes.²⁶ The worms live and reproduce in the ileum, cecum, colon and appendix and the nematode female migrates to the anus to deposit its eggs and die, usually at nighttime. Autoinfection occurs by scratching the perianal area and transferring infective eggs to the mouth with contaminated hands. Following ingestion, eggs hatch and release larvae in the small intestine. The adult worms establish themselves in the gastrointestinal tract, mainly in the cecum and appendix.²⁷

The incidence of EV in specimens of patients who

underwent appendectomy due to AA was 9.8% in our study. In a recent study from Tunisia, pathological reports of 24697 appendectomy specimens were analyzed. In this study, 68% of patients were adults and 32% were children; the reported incidence of EV was 6.4%. Previous reports have shown that this incidence was between 0.15 and 12.5 % in different parts of the world.^{5,13,28-40}

Our study provides data that 50% of children with negative appendectomy are EV+. Negative appendectomy rate was significantly higher in the EV+ group compared to the EV- group. This finding supports the notion that presenting with right iliac fossa pain could be explained by EV infection. The results of our study made it possible to identify features that could clinically differentiate true appendicitis from appendiceal colic caused by EV. Pruritus ani, Normal WBC count, normal neutrophil count, and normal CRP level at presentation could predict EV infection in children who present with right iliac fossa pain. Sodergren et al³² and Akkapulu & Abdullazade¹⁵ compared the white cell counts with a control group and found that WBC count in the EV+ group was significantly lower than that of the EV- group. In accordance with other studies,^{15,41} our study showed no correlation between eosinophil counts in peripheral blood and EV infection. However, some studies suggest that eosinophilia may be helpful in predicting EV infection.⁴²⁻⁴⁴

In our study, ultrasonography showed an accuracy of 81.1% for the diagnosis of AA. Ultrasonography of the right iliac fossa is a useful imaging technique because of its safety and high diagnostic accuracy for evaluation of AA.^{45,46} Ultrasound is superior to laboratory tests for both affirming and excluding appendicitis.⁴⁵ However, ultrasound is not a reliable method to diagnose EV infestation of the appendix.

Our study was limited by its retrospective nature, the possibility of discharged patients presenting with appendicitis at other hospitals and the relatively small number of patients. In addition, we did not include clinical variables such as the Alvarado score, and specimens were only examined by a single pathologist.

In conclusion, EV was seen in 9.8% of pediatric appendectomies in our study. Pruritus ani, normal WBC count, normal Neutrophil count, and normal CRP level at presentation could predict EV infection in children who present with right iliac fossa pain. Careful examination, symptomatology awareness, and a high level of suspicion might prevent unnecessary appendectomies. Therefore, we strongly recommend that all appendectomy specimens be examined histopathologically regardless of whether the specimens are macroscopically normal.

Authors' Contribution

MZ: study design, data analysis, writing, final approval. HL: study design, data collections, writing, final approval. IA: data collections, writing, final approval. FT: data collections, writing, final approval. MBD: study design, revising, final approval. MJ: study design, revising, final approval. RM: study design, revising, final approval.

Conflict of Interest Disclosures

The authors have no conflicts of interest.

Ethical Statement

The study protocol was approved by the local hospital ethics committee. All patients were included in the study after informed consent procedures (Etical code: researchregistry 3185).

References

- Vleeschouwers W, Hofman P, Gillardin JP, Meert V, Van Slycke S. Appendicitis-like clinical image elicited by *Enterobius vermicularis*: case report and review of the literature. *Acta Chir Belg*. 2013;113(2):139-42.
- Kucik CJ, Martin GL, Sortor BV. Common intestinal parasites. *Am Fam Physician*. 2004;69(5):1161-8.
- Rohidas MA, Sampatraj JS, Ajit KA, Motilal RP. Massive infestation with pinworms causing chronic diarrhea. *J Formos Med Assoc*. 2015;114(10):1011-2. doi: 10.1016/j.jfma.2013.01.010.
- Wiebe BM. Appendicitis and *Enterobius vermicularis*. *Scand J Gastroenterol*. 1991;26(3):336-8.
- Gialamas E, Papavramidis T, Michalopoulos N, Karayannopoulou G, Cheva A, Vasilaki O, et al. *Enterobius vermicularis*: a rare cause of appendicitis. *Turkiye Parazit Derg*. 2012;36(1):37-40. doi: 10.5152/tpd.2012.09.
- Arca MJ, Gates RL, Groner JL, Hammond S, Caniano DA. Clinical manifestations of appendiceal pinworms in children: an institutional experience and a review of the literature. *Pediatr Surg Int*. 2004;20(5):372-5. doi: 10.1007/s00383-004-1151-5.
- Yildirim S, Nursal TZ, Tarim A, Kayaselcuk F, Noyan T. A rare cause of acute appendicitis: parasitic infection. *Scand J Infect Dis*. 2005;37(10):757-9. doi: 10.1080/00365540510012161.
- Nordstrand IA, Jayasekera LK. *Enterobius vermicularis* and clinical appendicitis: worms in the vermiform appendix. *ANZ J Surg*. 2004;74(11):1024-5. doi: 10.1111/j.1445-1433.2004.03230.x.
- Panidis S, Paramythiotis D, Panagiotou D, Batsis G, Salonikidis S, Kaloutsis V, et al. Acute appendicitis secondary to *Enterobius vermicularis* infection in a middle-aged man: a case report. *J Med Case Rep*. 2011;5:559. doi: 10.1186/1752-1947-5-559.
- Henneman PL, Marcus CS, Inkelis SH, Butler JA, Baumgartner FJ. Evaluation of children with possible appendicitis using technetium 99m leukocyte scan. *Pediatrics*. 1990;85(5):838-43.
- Escriba A, Gamell AM, Fernandez Y, Quintilla JM, Cubells CL. Prospective validation of two systems of classification for the diagnosis of acute appendicitis. *Pediatr Emerg Care*. 2011;27(3):165-9. doi: 10.1097/PEC.0b013e31820d6460.
- Acheson J, Banerjee J. Management of suspected appendicitis in children. *Arch Dis Child Educ Pract Ed*. 2010;95(1):9-13. doi: 10.1136/adc.2009.168468.
- Jones AE, Phillips AW, Jarvis JR, Sargen K. The value of routine histopathological examination of appendectomy specimens. *BMC Surg*. 2007;7:17. doi: 10.1186/1471-2482-7-17.
- Primates P, Goldacre MJ. Appendectomy for acute appendicitis and for other conditions: an epidemiological study. *Int J Epidemiol*. 1994;23(1):155-60.
- Akkapulu N, Abdullazade S. Is *Enterobius vermicularis* infestation associated with acute appendicitis? *Eur J Trauma Emerg Surg*. 2016;42(4):465-70. doi: 10.1007/s00068-015-0555-3.
- Carr NJ. The pathology of acute appendicitis. *Ann Diagn Pathol*. 2000;4(1):46-58. doi: 10.1053/adpa.2000.0046.
- Williams RA. Inflammatory disorders of the appendix. In: Williams RA, Myers P. Pathology of the Appendix and its Surgical Treatment. London: Chapman and Hall Medical Press; 1994. p. 53-89.
- Gray GF J, Wackym PA. Surgical pathology of the vermiform appendix. *Pathol Annu*. 1986;21 Pt 2:111-44.
- Alemayehu H, Snyder CL, St Peter SD, Ostlie DJ. Incidence and outcomes of unexpected pathology findings after appendectomy. *J Pediatr Surg*. 2014;49(9):1390-3. doi: 10.1016/j.jpedsurg.2014.01.005.
- Bundy DA, Cooper ES, Brooker S. Nematodes Limited to the Intestinal Tract (*Enterobius vermicularis*, *Trichuris trichiura*, *Capillaria philippinensis* and *Trichostrongylus* spp.). In: Magill AJ, Ryan ET, Solomon T, Hill DR. Hunter's Tropical Medicine and Emerging Infectious Disease. 9th ed. Saunders/Elsevier; 2013:797-803. doi: 10.1016/B978-1-4160-4390-4.00107-7.
- Zoorob RJ. Appendiceal colic caused by *Enterobius vermicularis*. *J Am Board Fam Pract*. 1996;9(1):57-9.
- Ajao OG, Jastaniah S, Malatani TS, Morad N, el Tayeb EN, Saif SA, et al. *Enterobius vermicularis* (pin worm) causing symptoms of appendicitis. *Trop Doct*. 1997;27(3):182-3. doi: 10.1177/004947559702700327.
- Saxena AK, Springer A, Tsokas J, Willital GH. Laparoscopic appendectomy in children with *Enterobius vermicularis*. *Surg Laparosc Endosc Percutan Tech*. 2001;11(4):284-6.
- Dahlstrom JE, Macarthur EB. *Enterobius vermicularis*: a possible cause of symptoms resembling appendicitis. *Aust N Z J Surg*. 1994;64(10):692-4.
- Cook GC. *Enterobius vermicularis* infection. *Gut*. 1994;35(9):1159-62.
- Moore TA, McCarthy JS. Enterobiasis. In: Guerrant RL, Walker DH, Weller PF. Tropical Infectious Diseases: Principles, Pathogens and Practice. 3rd ed. Philadelphia: Churchill Livingstone; 2011. p. 788-90.
- Lamps LW. *Enterobius Vermicularis* (Pinworms). In: Lamps LW, ed. Surgical Pathology of the Gastrointestinal System: Bacterial, Fungal, Viral, and Parasitic Infections. 1st ed. New York: Springer Publishing; 2010. p. 201-3.
- Engin O, Calik S, Calik B, Yildirim M, Coskun G. Parasitic appendicitis from past to present in Turkey. *Iran J Parasitol*. 2010;5(3):57-63.
- Yabanoglu H, Caliskan K, Ozgur Aytac H, Turk E, Karagulle E, Kayaselcuk F, et al. Unusual findings in appendectomy specimens of adults: retrospective analyses of 1466 patients and a review of literature. *Iran Red Crescent Med J*. 2014;16(2):e12931. doi: 10.5812/ircmj.12931.
- da Silva DF, da Silva RJ, da Silva MG, Sartorelli AC, Rodrigues MA. Parasitic infection of the appendix as a cause of acute appendicitis. *Parasitol Res*. 2007;102(1):99-102. doi: 10.1007/s00436-007-0735-0.
- Bredesen J, Falenstein Lauritzen A, Kristiansen VB, Sorensen C, Kjersgaard P. Appendicitis and enterobiasis in children. *Acta Chir Scand*. 1988;154(10):585-7.
- Sodergren MH, Jethwa P, Wilkinson S, Kerwat R. Presenting features of *Enterobius vermicularis* in the vermiform appendix. *Scand J Gastroenterol*. 2009;44(4):457-61. doi: 10.1080/00365520802624227.
- Isik B, Yilmaz M, Karadag N, Kahraman L, Sogutlu G, Yilmaz S, et al. Appendiceal *Enterobius vermicularis* infestation in adults. *Int Surg*. 2007;92(4):221-5.
- Lohsiriwat V, Vongjirad A, Lohsiriwat D. Value of routine histopathologic examination of three common surgical specimens: appendix, gallbladder, and hemorrhoid. *World J Surg*. 2009;33(10):2189-93. doi: 10.1007/s00268-009-0164-6.
- Matthysens LE, Ziolk M, Barrat C, Champault GG. Routine surgical pathology in general surgery. *Br J Surg*. 2006;93(3):362-8. doi: 10.1002/bjs.5268.
- Swank HA, Eshuis EJ, Ubbink DT, Bemelman WA. Is routine histopathological examination of appendectomy specimens useful? A systematic review of the literature. *Colorectal Dis*. 2011;13(11):1214-21. doi: 10.1111/j.1463-1318.2010.02457.x.

37. Akbulut S, Tas M, Sogutcu N, Arikanoğlu Z, Basbug M, Ulku A, et al. Unusual histopathological findings in appendectomy specimens: a retrospective analysis and literature review. *World J Gastroenterol*. 2011;17(15):1961-70. doi: 10.3748/wjg.v17.i15.1961.
38. Yilmaz M, Akbulut S, Kutluturk K, Sahin N, Arabaci E, Ara C, et al. Unusual histopathological findings in appendectomy specimens from patients with suspected acute appendicitis. *World J Gastroenterol*. 2013;19(25):4015-22. doi: 10.3748/wjg.v19.i25.4015.
39. Ariyathenam AV, Nachimuthu S, Tang TY, Courtney ED, Harris SA, Harris AM. *Enterobius vermicularis* infestation of the appendix and management at the time of laparoscopic appendectomy: case series and literature review. *Int J Surg*. 2010;8(6):466-9. doi: 10.1016/j.ijsu.2010.06.007.
40. Chandrasegaram MD, Rothwell LA, An EI, Miller RJ. Pathologies of the appendix: a 10-year review of 4670 appendectomy specimens. *ANZ J Surg*. 2012;82(11):844-7. doi: 10.1111/j.1445-2197.2012.06185.x.
41. Salim N, Schindler T, Abdul U, Rothen J, Genton B, Lweno O, et al. Enterobiasis and strongyloidiasis and associated co-infections and morbidity markers in infants, preschool- and school-aged children from rural coastal Tanzania: a cross-sectional study. *BMC Infect Dis*. 2014;14:644. doi: 10.1186/s12879-014-0644-7.
42. Aydin O. Incidental parasitic infestations in surgically removed appendices: a retrospective analysis. *Diagn Pathol*. 2007;2:16. doi: 10.1186/1746-1596-2-16.
43. Clark PJ. Utility of eosinophilia as a diagnostic clue in lower abdominal pain in northern Australia: a retrospective case-control study. *Intern Med J*. 2008;38(4):278-80. doi: 10.1111/j.1445-5994.2008.01644.x.
44. Fleming CA, Kearney DE, Moriarty P, Redmond HP, Andrews EJ. An evaluation of the relationship between *Enterobius vermicularis* infestation and acute appendicitis in a paediatric population--A retrospective cohort study. *Int J Surg*. 2015;18:154-8. doi: 10.1016/j.ijsu.2015.02.012.
45. Zouari M, Jallouli M, Louati H, Kchaou R, Chtourou R, Kotti A, et al. Predictive value of C-reactive protein, ultrasound and Alvarado score in acute appendicitis: a prospective pediatric cohort. *Am J Emerg Med*. 2016;34(2):189-92. doi: 10.1016/j.ajem.2015.10.004.
46. Yu SH, Kim CB, Park JW, Kim MS, Radosevich DM. Ultrasonography in the diagnosis of appendicitis: evaluation by meta-analysis. *Korean J Radiol*. 2005;6(4):267-77. doi: 10.3348/kjr.2005.6.4.267.



© 2018 The Author(s). This is an open-access article distributed under the terms of the Creative Commons Attribution License (<http://creativecommons.org/licenses/by/4.0>), which permits unrestricted use, distribution, and reproduction in any medium, provided the original work is properly cited.

Archive of SID