

Original Article

The Significance of the Stromal Response in Breast Cancer: An Immunohistochemical Study of Myofibroblasts in Primary and Metastatic Breast Cancer

Alale Roozdar, MD¹; Malcolm M. Hayes, M.Med.Path²; Bahram Pourseyedei, MD³; Hamid Zeinalinejad, MD³; Manzumeh Shamsi Meymandi, PhD¹; Bahram Dabiri, MD¹; Shahriar Dabiri, MD^{1*}

¹Pathology and Stem Cells Research Center, Pathology Department, Afzalipour Kerman Medical Sciences University, Kerman, Iran

²Pathology Department, B.C. Cancer Agency, University of British Columbia, Vancouver, Canada

³Surgery Department, Afzalipour Kerman Medical Sciences University, Kerman, Iran

Abstract

Background: Gene expression profiling of breast cancer has demonstrated the importance of stromal response in determining the prognosis of invasive breast cancer. The host response to breast cancer is of increasing interest to pathologists and may be a future focus for novel pharmacological treatments.

Methods: This study describes the pattern of distribution of stromal myofibroblasts using immunostains for CD10 and smooth muscle actin (SMA) in 50 primary breast cancers and their matched nodal metastases (68.6% nodes positive and 31.4% nodes negative). The stroma within the tumor (intratumoral) and at the advancing tumor edge (peri-tumoral) was studied in both primary and nodal sites. A simple quantitative scoring system was employed for both immunostains. The correlation between expression of these markers by stromal cells and standard pathological prognostic factors of stage, grade, hormone receptor and Her-2 status was analysed.

Results: SMA-positive stromal cells were more abundant in peri-tumoral stroma compared with intratumoral stroma in both primary and metastatic lesions. SMA expression in the lymph node metastases showed a significant correlation with tumor stage. SMA expression in peri-tumoral stroma correlated with Her-2 status.

Conclusion: The results of this study suggest that myofibroblasts, particularly those expressing SMA, might potentiate the progression of the carcinomatous process especially in nodal metastases. Thus these cells may be a potential therapeutic target.

Keywords: Breast cancer, Metastatic breast cancer, Myofibroblast

Cite this article as: Roozdar A, Hayes MM, Pourseyedei B, Zeinalinejad H, Meymandi MS, Dabiri B,. The significance of the stromal response in breast cancer: an immunohistochemical study of myofibroblasts in primary and metastatic breast cancer. Arch Iran Med. 2018;21(5):185–190.

Received: April 18, 2016, Accepted: April 8, 2018, ePublished: May 1, 2018

Introduction

Breast cancer is the most commonly diagnosed cancer in women worldwide. In Iran, it is the fifth-leading cause of cancer-related death among women, and also is the main cause of death in women aged 49 to 79 years.^{1,2} Unfortunately, age of breast cancer onset is earlier in Iranian women compared with other countries. About half of the breast cancer patients are referred too late to specialists for treatment, and consequently their disease is diagnosed in advanced stages.^{3,4}

Carcinomatous breast tissues are composed of neoplastic epithelial cells and their surrounding stroma. The interaction between these 2 major components determines tumoral cells growth and spread. Recently, several molecular and gene expression studies have demonstrated that interaction between the cells of carcinoma and the host microenvironment has prognostic significance.^{5–7} The inflammatory immune

reaction to the tumor has become the focus of new therapies using PD-1 antagonists. The stromal cells offer another potential target for novel therapies.⁸ Therefore, we studied the relationship between the expression of smooth muscle actin (SMA) and CD10 in stromal cells of 50 matched primary and/or metastatic breast carcinomas, and its correlation with established prognostic factors. We studied both intratumoral stroma and peri-tumoral stroma in both primary tumors and their matched axillary lymph nodes.

Materials and Methods

The tissue samples of 50 female patients with pathology proven invasive ductal breast carcinoma (treated by mastectomy and axillary lymph node dissection) were entered in the present study. The paraffin blocks were retrieved from the pathology archives of Afzalipour Kerman University. For each case, 2 blocks containing

*Corresponding Author: Shahriar Dabiri, MD, FIAC; Pathology and Stem Cells Research Center, Pathology Department, Afzalipour Kerman Medical Sciences University, Kerman, Iran. Address: 22th Bahman Blvd; P. O. Box 444, Tehran, Iran. Tel: +98-3433257112, Email:dabiri12@yahoo.com

lymph node tissue and primary breast tumor tissue were selected. These blocks were estimated to contain similar quantities of carcinoma and stromal tissues. Sections were cut from the blocks using standard histopathology methods, and were examined after hematoxylin and eosin (H&E) and immunohistochemical (IHC) staining for SMA, CD10 and Ki-67 markers. The expression of CD10 and SMA was quantified by counting the positive stained cells and considering the mean in 10 high-power fields (400X), in the stroma of inside (intratumoral) and outside (extra-tumoral) the tumor. Ki-67 index was evaluated by counting the percentage of nuclei stained positive in the primary breast tumor.

The patients' demographic features including tumor size, stage of the disease, number of involved lymph nodes, ER, PR and Her2Neu status were also retrieved from the patients' charts (Table 1). These standard prognostic parameters correlated with the results of immunostains for SMA, CD10 and Ki-67. Because of the unavailability of molecular techniques, clinical staging was determined according to the recent 2017 American Joint Committee on Cancer.⁹

Data were analyzed by using SPSS software version 22 by *t* test, analysis of variance (ANOVA) and Tukey test. A *P* value of < 0.05 was statistically significant.

Results

Fifty-five percent of patients were aged less than 50 years. Lymph nodes were involved in 68.6% of patients. 31.4% of patients were node negative. Mean tumor size was 4.2 cm. 58.8% of patients were clinical stage II and 41.2% were at stage III. 42.9% of patients at stage III were in age range of 41-50 years, while in the stage II group 33.3% were aged 31-40 years. There was a significant correlation between age and tumor stage (*P* = 0.028). 68.6% of tumors were ER positive, 51% were PR positive and 19.6% were Her2 positive (3+ IHC) (Table 1).

In primary breast tumors, the mean percent of SMA expression in stromal cells showed a significant difference between intratumoral stroma (mean = 29.5%) and peri-tumoral stroma (mean = 82.8%). Mean SMA stromal expression in lymph nodes was 50% in intratumoral stroma and 78% in extra-tumoral stroma tissues. SMA-positive myfibroblasts in peri-tumoral stroma showed a significant correlation with positive Her2 expression (*P*<0.015) and disease stage (*P*<0.045). This relationship was not evident for SMA-positive myfibroblasts in intratumoral stroma. SMA expression in intraand peri-tumoral stroma of the primary breast tumors showed no significant correlation with ER, PR status, and Ki-67 index.

Furthermore, the number of SMA-positive stromal

Table 1. The Frequency of Demographic and Immunohistochemical Variables According to the Disease Stage

	Stage II	Stage III
Age range (y)		
20-30	6.1%	-
30-40	33.3%	4.8%
40-50	20.0%	42.9%
50-60	26.7%	28.6%
60-70	13.3%	14.3%
70-80	-	9.5%
ER +	70%	66.7%
PR +	50%	52%
Her2Neu 3+	13%	15%
Axillary lymph nodes	50%	100%

cells in the primary tumor did not correlate with age of patient, tumor size, tumor grade, presence or absence of lymph nodes involvement or the number of involved lymph nodes. SMA expression in the lymph node metastases significantly increased with the clinical stage of the disease (*P*<0.01) (Figures 1, 2 and 3).

In primary breast tumors, the mean percent of CD10 expression showed a significant difference between intratumoral stroma (mean = 6.1%) and peri-tumoral stroma (mean = 37.2%). Mean CD10 stromal expression in lymph nodes was 10.4% in intratumoral stroma and 36% in peri-tumoral tissues. CD10-positive stromal cells were most frequent in the nodal metastases of stage III tumors. The CD10-positive cells were more numerous in primary tumor than in the matched nodal metastases (*P*<0.01). Stromal expression of CD10 was significantly less in intratumoral stroma compared with peri-tumoral stroma of both primary breast tumors and their nodal metastases (Figures 4, 5 and 6). Intratumoral stromal CD10 cells in the lymph node metastases showed significant inverse correlation with ER status. Stromal CD10 cells showed no significant correlation with PR, Her2Neu, Ki-67 levels, patients' age, tumor size, presence or absence of lymph nodes involvement or the number of involved lymph nodes. There was a positive

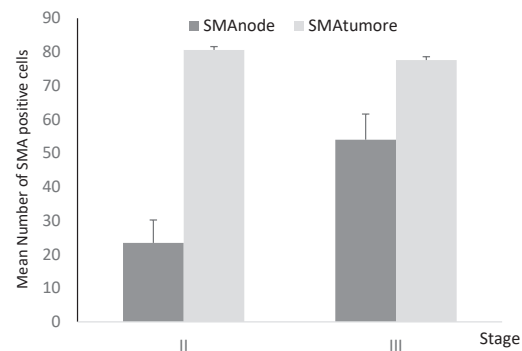


Figure 1. Comparison Between Numbers of SMA-Positive Stromal Cells in Primary Breast Tumor and Matched Lymph Node Metastases According to Different Tumor Stages. SMA expression in the nodal metastases in stage II is less than stage III.

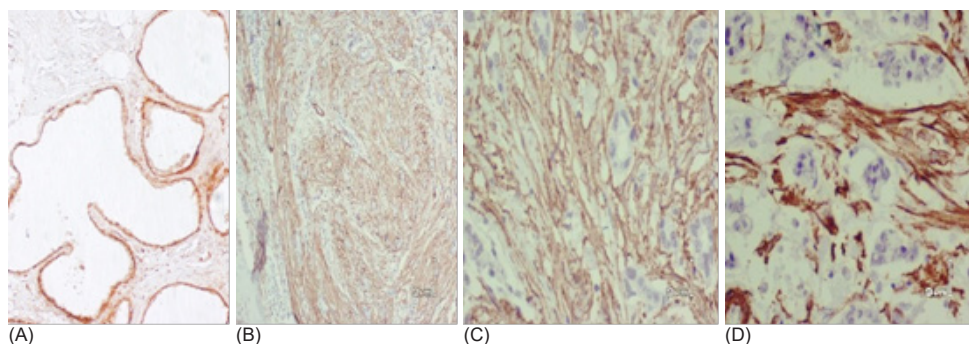


Figure 2. SMA IHC Staining in Primary Breast Cancer. A) SMA expression in fibrocystic change (normal control, $\times 40$); B, C) SMA stained stromal cells in intratumoral stroma ($\times 40$, $\times 100$); D) SMA expression in myofibroblasts of extra-tumoral and intratumoral stroma ($\times 400$).

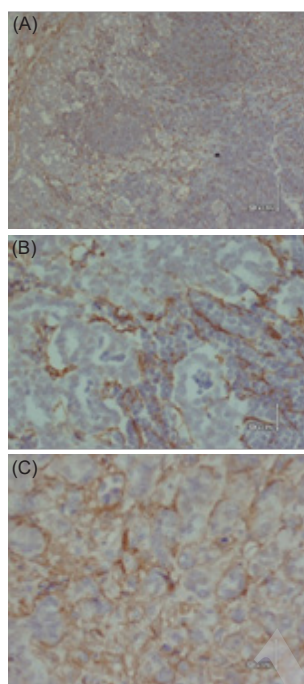


Figure 3. SMA IHC Staining in Metastatic Lymph Node. A) SMA expression of myofibroblasts between metastatic tumoral nests ($\times 40$); B) SMA stained stromal cells of extra tumoral nests ($\times 40$); C) Myofibroblastic SMA stained cells of intra tumoral nests ($\times 400$).

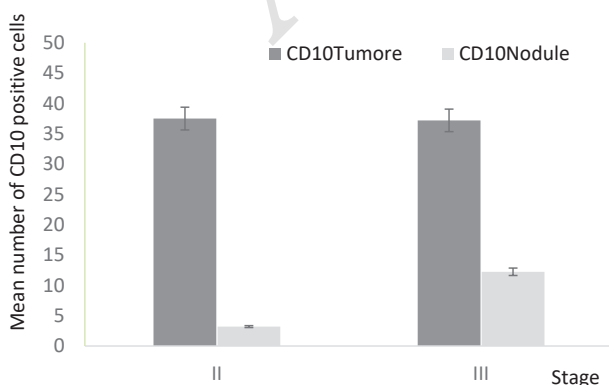


Figure 4. CD10 Positive Stromal Cells (in Primary Breast Tumor and Lymph Node) According to Different Stages. CD10 is less expressed in nodal stage II metastases than stage III cancers..

correlation between the number of CD10-positive cells and the number of SMA-positive cells in intratumoral stroma.

Discussion

Gene expression studies have demonstrated that the host microenvironment has prognostic significance in predicting the outcome of breast cancer.^{5-7,10,11}

Azzopardi described that myofibroblasts show morphologic features of both fibroblasts and smooth muscle cells. He postulated that myofibroblasts are derived from modified reactive fibroblasts or myoepithelial cells.¹² Current opinion favors a fibroblastic or mesenchymal stem cell origin. Myofibroblasts express alpha-SMA in their cytoplasm and appear in invasive breast carcinomas.¹³

The inflammatory immune reaction to the tumor has become the focus of new therapies using PD-1 antagonists. The stromal fibroblasts and myofibroblasts which may act through STAT 3 signaling, offer another potential target for novel therapies.⁸

Myofibroblasts produce and secrete several growth factors which act as ligands for epidermal growth factor receptors (such as Her2Neu), and simultaneously stimulate the expression of Her2Neu in breast cancer tumoral cells.

Since higher tumoral grade, and increased expression of Ki-67 and Her2Neu are unfavorable prognostic factors, the number of stromal myofibroblasts is confirmed to be an indicator of worse prognosis.^{11,13} Furthermore, there is significant correlation between the content of stromal myofibroblasts and the number of lymph nodes involved in invasive breast carcinomas.¹³

Since overexpression of Her2Neu is a negative prognostic factor in breast carcinomas, this may explain why the presence of myofibroblasts in tumoral stroma is associated with a poor prognosis.¹⁴⁻¹⁷ Furthermore, basal-type breast cancers are known to activate the proliferation of myofibroblasts, and this subset of breast cancers has a poor prognosis.¹⁸ Previous studies have

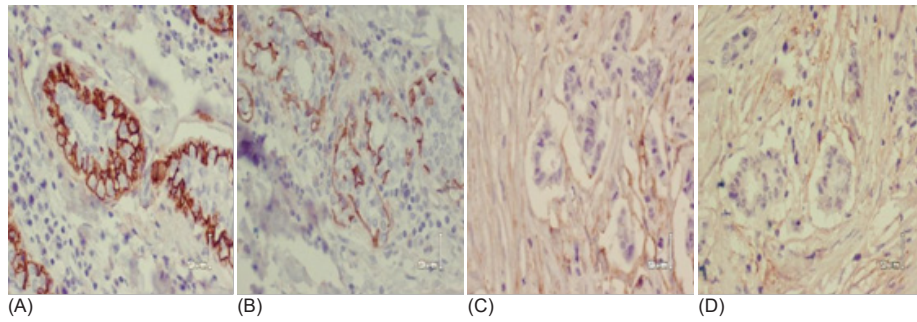


Figure 5. CD10 IHC Staining in Primary Breast Cancer. A) CD10 stained myoepithelial cells in normal duct (normal control, ×40); B, C, D) CD10 expression in extra-tumoral stroma with lower expression in intratumoral stromal cells (×400).




Figure 6. CD10 IHC Staining in Metastatic Lymph Node. A) Normal germinal center (×40); B) Scattered CD10 expression in intratumoral stroma (×100); C) Low expression of CD10 in extra tumoral nests and nearly no expression within the tumoral stroma (×400).

documented higher contents of myofibroblast cells in grade III invasive breast cancer compared to grade I.¹⁹

CD10 is a cytoplasmic marker which is expressed by myoepithelial cells and a subset of myofibroblasts present in specialized periductal and lobular stroma of both normal and malignant breast tissues.²⁰ Expression of the CD10 stromal marker correlates with invasiveness of epithelial malignancies and also worse prognosis.^{17,20} Stromal CD10 also positively correlates with the tumor grade and ER negative status. Since CD10 expression in invasive breast cancer is associated with negative ER, higher tumoral grade, and worse patients' survival, it is confirmed to be a prognostic marker and a potential target for new treatments.²⁰

SMA is a characteristic cytoplasmic marker of

myofibroblasts. A previous study showed that SMA expression occurs in 95.1% of metastatic lymph nodes and 97.2% of liver metastases of breast cancers, independent of tumor histologic features. This suggests that the stromal myofibroblasts have a major role in cell proliferation and spread of breast cancer.²¹ Previous studies have shown a positive correlation between myofibroblastic content of tumoral stroma and expression of Ki-67 and Her2Neu in different grades of breast cancer.²²

Several studies have shown that SMA expression and lymph nodes metastases are independent predictive factors for distant metastases. By promoting aggressive cancer growth, myofibroblasts may play an adverse role in patients with invasive breast cancer.²³

There was no significant correlation between SMA and CD10 expression and the age of the patient, confirming the findings of Surowiak et al.¹⁷

In our study, SMA expression in peri-tumoral stromal of the lymph nodes metastases was significantly lower in stage II than stage III. This finding suggests the role of stromal myofibroblasts in the metastatic process to lymph nodes. In primary tumors, there was no significant relationship between SMA and CD10 levels with tumor stage, confirming the results of Surowiak et al.¹⁵

In the present study, SMA levels in primary breast tumors and lymph nodes did not correlate with tumor grade, whereas in previous studies, higher stromal SMA expression has been reported in higher grade in situ lesions than medium and lower grade ones,²⁴ and also greater numbers of myofibroblasts have been correlated with high-grade tumors.^{15,17,21} In our study, there was no significant correlation between SMA expression and ER and PR status. A significant positive correlation was detected between SMA levels in peritumoral stroma and positive Her2Neu status, so that Her2Neu positive status could predict higher levels of SMA. This finding confirmed the results of the previous studies.¹⁷ It has been shown that in cancers with higher content of

myofibroblasts, higher levels of Her2Neu is expressed. Myofibroblasts secrete insulin like and hepatocyte growth factors. They present on their surface several ligands for epidermal growth factor receptors such as Her2Neu. Since Her2Neu receptor is a negative prognostic factor, this mechanism may explain why the number of myofibroblasts is a negative prognostic factor in breast cancer patients.¹⁷

An inverse correlation was evident between the amount of CD10 in intratumoral stroma and ER negative status. Thus, ER positive status was correlated with a lower level of stromal CD10 expression. The above mentioned result is quite consistent with the results of previous studies in which CD10 expression in invasive breast cancer was associated with negative ER status, higher tumoral grade, and reduction in patients' survival. Therefore, CD10 is a potential target for developing new treatments. CD10 is a zinc associated metalloproteinase that breaks down doxorubicin (a major chemotherapeutic drug used in breast cancer treatment). So CD10 expression may cause resistance to chemotherapy. Indeed, inhibition of the enzymatic effect of CD10 results in increased therapeutic effect of chemotherapy.²⁰

Previous studies have also proven that breast cancers that express higher levels of myofibroblasts in tumoral tissues, also express higher levels of Ki-67.^{15,17} In the present study, stromal myofibroblasts markers (CD10 and SMA) did not show any significant correlation with Ki-67 index.

In our study, none of stromal markers (SMA and CD10) showed significant correlation with presence or absence of lymph nodes involvement and also the number of affected lymph nodes, while in a previous study, a significant relationship was proved between amount of stromal myofibroblasts and the number of affected lymph nodes.²⁰ In another study, a significant correlation was observed between CD10 expression levels and absence of metastatic lymph nodes (lymph node negative status).¹⁹

The results of this study confirmed that positive Her2Neu status is associated with higher levels of SMA. Since Her2Neu is a negative prognostic factor in breast cancer patients, increase in stromal SMA expression could be another negative prognostic factor in this population.

In conclusion, in primary breast tumors, intratumoral stromal cells express markers different from those in peri-tumoral desmoplastic stroma. This finding supports the hypothesis that intratumoral stroma contains unique cells and behaves in a unique way different from extra-tumoral stroma.

On the other hand, in the lymph nodes metastases, stromal markers (CD10 and SMA) showed congruent expression in both intratumoral and peri-tumoral

desmoplastic stroma. This suggests that the metastatic carcinoma is influencing the cellular composition of both intratumoral and extra-tumoral.

The novel work of this paper is focusing on synergistic effects of neoplastic epithelial and its supporting stroma inside tumoral cells and outside them even at metastatic foci.

Importantly, given the differing results obtained from many studies, further study of the stromal microenvironment of both primary and metastatic breast carcinoma is essential as the stromal cells are potential targets for novel therapeutic agents.

Authors' Contribution

All authors contributed equally to this study.

Conflict of Interest Disclosures

The authors have no conflicts of interest.

Ethical Statement

The current study was approved by the Ethics Committee of Afzalipour Kerman University of Medical Sciences.

Acknowledgement

We express our appreciation to Mrs. Sheikhshoae for her excellent technical assistance.

References

1. Taghavi A, Fazeli Z, Vahedi M, Baghestani AR, Pourhoseingholi A, Barzegar F, et al. Increased trend of breast cancer mortality in Iran. *Asian Pac J Cancer Prev*. 2012;13(1):367-70.
2. Cooksley S, Hipkiss JB, Tickle SP, Holmes-levers E, Docherty AJ, Murphy G, et al. Immunoassays for the detection of human collagenase, stromelysin, tissue inhibitor of metalloproteinases (TIMP) and enzyme-inhibitor complexes. *Matrix*. 1990;10(5):285-91.
3. Newman PJ. The role of PECAM-1 in vascular cell biology. *Ann NY Acad Sci*. 1994;714:165-74.
4. Luukka M, Vihinen P, Kronqvist P, Vahlberg T, Pyrhonen S, Kahari VM, et al. Association between high collagenase-3 expression levels and poor prognosis in patients with head and neck cancer. *Head Neck*. 2006;28(3):225-34. doi: 10.1002/hed.20322.
5. Chang HY, Sneddon JB, Alizadeh AA, Sood R, West RB, Montgomery K, et al. Gene expression signature of fibroblast serum response predicts human cancer progression: similarities between tumors and wounds. *PLoS Biol*. 2004;2(2):E7. doi: 10.1371/journal.pbio.0020007.
6. Chang HY, Nuyten DS, Sneddon JB, Hastie T, Tibshirani R, Sorlie T, et al. Robustness, scalability, and integration of a wound-response gene expression signature in predicting breast cancer survival. *Proc Natl Acad Sci U S A*. 2005;102(10):3738-43. doi: 10.1073/pnas.0409462102.
7. Dunn L, Demichele A. Genomic predictors of outcome and treatment response in breast cancer. *Mol Diagn Ther*. 2009;13(2):73-90. doi: 10.2165/01250444-200913020-00002.
8. Segatto I, Berton S, Sonogo M, Massarut S, Perin T, Piccoli E, et al. Surgery-induced wound response promotes stem-like and tumor-initiating features of breast cancer cells, via STAT3 signaling. *Oncotarget*. 2014;5(15):6267-79. doi: 10.18632/oncotarget.2195.
9. Giuliano AE, Connolly JL, Edge SB, Mittendorf EA, Rugo HS, Solin LJ, et al. Breast Cancer-Major changes in the American Joint Committee on Cancer eighth edition cancer staging manual. *CA Cancer J Clin*. 2017;67(4):290-303. doi: 10.3322/

- caac.21393.
10. Azzopardi J. Problems in Breast Pathology (Major Problems in Pathology). 1st ed. Bailliere Tindall; 1979:395.
 11. Desmouliere A, Guyot C, Gabbiani G. The stroma reaction myofibroblast: a key player in the control of tumor cell behavior. *Int J Dev Biol.* 2004;48(5-6):509-17. doi: 10.1387/ijdb.041802ad.
 12. Novak K. Prognosis: A healing process. *Nat Rev Cancer.* 2005;5(4):244. doi: 10.1038/nrc1596.
 13. Troester MA, Lee MH, Carter M, Fan C, Cowan DW, Perez ER, et al. Activation of host wound responses in breast cancer microenvironment. *Clin Cancer Res.* 2009;15(22):7020-8. doi: 10.1158/1078-0432.ccr-09-1126.
 14. De Wever O, Mareel M. Role of tissue stroma in cancer cell invasion. *J Pathol.* 2003;200(4):429-47. doi: 10.1002/path.1398.
 15. Surowiak P, Murawa D, Materna V, Maciejczyk A, Pudelko M, Ciesla S, et al. Occurrence of stromal myofibroblasts in the invasive ductal breast cancer tissue is an unfavourable prognostic factor. *Anticancer Res.* 2007;27(4c):2917-24.
 16. Offersen BV, Nielsen BS, Hoyer-Hansen G, Rank F, Hamilton-Dutoit S, Overgaard J, et al. The myofibroblast is the predominant plasminogen activator inhibitor-1-expressing cell type in human breast carcinomas. *Am J Pathol.* 2003;163(5):1887-99. doi: 10.1016/s0002-9440(10)63547-x.
 17. Surowiak P, Suchocki S, Gyorffy B, Gansukh T, Wojnar A, Maciejczyk A, et al. Stromal myofibroblasts in breast cancer: relations between their occurrence, tumor grade and expression of some tumour markers. *Folia Histochem Cytobiol.* 2006;44(2):111-6.
 18. Kim RK, Suh Y, Yoo KC, Cui YH, Kim H, Kim MJ, et al. Activation of KRAS promotes the mesenchymal features of basal-type breast cancer. *Exp Mol Med.* 2015;47:e137. doi: 10.1038/emmm.2014.99.
 19. Dabiri S, Talebi A, Shahryari J, Meymandi MS, Safizadeh H. Distribution of myofibroblast cells and microvessels around invasive ductal carcinoma of the breast and comparing with the adjacent range of their normal-to-DCIS zones. *Arch Iran Med.* 2013;16(2):93-9. doi: 013162/aim.008.
 20. Makretsov NA, Hayes M, Carter BA, Dabiri S, Gilks CB, Huntsman DG. Stromal CD10 expression in invasive breast carcinoma correlates with poor prognosis, estrogen receptor negativity, and high grade. *Mod Pathol.* 2007;20(1):84-9. doi: 10.1038/modpathol.3800713.
 21. Martinez LM, Labovsky V, Calcagno ML, Davies KM, Garcia Rivello H, Bianchi MS, et al. CD105 expression on CD34-negative spindle-shaped stromal cells of primary tumor is an unfavorable prognostic marker in early breast cancer patients. *PLoS One.* 2015;10(3):e0121421. doi: 10.1371/journal.pone.0121421.
 22. Madani SH, Payandeh M, Sadeghi M, Motamed H, Sadeghi E. The correlation between Ki-67 with other prognostic factors in breast cancer: A study in Iranian patients. *Indian J Med Paediatr Oncol.* 2016;37(2):95-9. doi: 10.4103/0971-5851.180136.
 23. Yamashita M, Ogawa T, Zhang X, Hanamura N, Kashikura Y, Takamura M, et al. Role of stromal myofibroblasts in invasive breast cancer: stromal expression of alpha-smooth muscle actin correlates with worse clinical outcome. *Breast Cancer.* 2012;19(2):170-6. doi: 10.1007/s12282-010-0234-5.
 24. Thike AA, Iqbal J, Cheok PY, Tse GM, Tan PH. Ductal carcinoma in situ associated with triple negative invasive breast cancer: evidence for a precursor-product relationship. *J Clin Pathol.* 2013;66(8):665-70. doi: 10.1136/jclinpath-2012-201428.