

## Case Report

# Early Treatment Was Life Saving in Varicella Pneumonia of an Immunocompetent Adult

Neslihan Çelik, MD<sup>1</sup>; Onur Çelik, MD<sup>2</sup>; Onur Ünal, MD<sup>1</sup><sup>1</sup>Infectious Disease and Clinical Microbiology, Erzurum Region Training and Research Hospital, Erzurum, Turkey<sup>2</sup>Chest Disease, Erzurum Region Training and Research Hospital, Erzurum, Turkey**Abstract**

Chickenpox, an infection of childhood with vesicular skin rash, is caused by varicella-zoster virus (VZV). Although the infection is rare in adults, it can cause serious complications. Varicella pneumonia is the most encountered complication. In this report, a VZV pneumonia case in a previously healthy adult is presented. The patient was treated with early intravenous acyclovir and both clinical and radiographic recovery has been observed.

**Keywords:** Acyclovir, Early treatment, Immunocompetent adult, Varicella pneumonia

**Cite this article as:** Çelik N, Çelik O, Ünal O. Early treatment was life saving in varicella pneumonia of an immunocompetent adult. Arch Iran Med. 2018;21(5):223–225.

Received: April 19, 2017, Accepted: January 10, 2018, ePublished: May 1, 2018

**Introduction**

Varicella is presented by vesicular rashes and fever, and is usually a mild, self-limiting disease in pediatric group. But it may occur in infants, pregnant women and in immunocompromised individuals, including HIV patients. Globally, on average, 4.2 million cases of severe varicella result in hospitalisation or death each year. Prior to widespread usage of vaccines against varicella in temperate high-income countries, 13–16 cases of varicella per 1000 population occurred annually, mostly affecting children aged 1–9 years. In these settings, more than 90% of the population are infected with varicella-zoster virus (VZV) before adolescence.<sup>1</sup> Secondary bacterial infection of skin, encephalitis, hepatitis, and reye syndrome pneumonia are major complications of varicella infection.<sup>2</sup> Despite appropriate treatment, varicella pneumonia can cause 10%–30% mortality.<sup>3</sup> Varicella infection in an immunocompetent female patient is represented in this case report.

**Case Report**

A 27-year-old female presented with a 2-day history of dyspnea and pleuritic pain. She had exanthematous vesicular rashes and fever that had started 2 days prior to the respiratory symptoms. She was not a smoker and her 5 years old son had chickenpox a week ago.

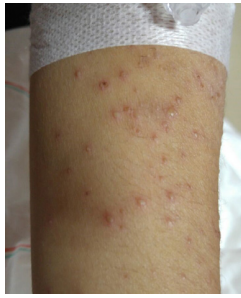Physical examination revealed subfebrile body temperature of 37.3°C, 120/80 mm Hg systolic/diastolic pressure, heart rate of 88/minute, widespread crepitations in the lower lung fields and rhonchi, and

multiple vesicles, pustules and crusty skin lesions including scalps (Figure 1). Other physical examination findings are normal. Laboratory studies showed WBC: 8200/mm<sup>3</sup> (neutrophil 58%, lymphocyte 22% and monocyte 15%), hemoglobine 12.8 g/dL, thrombocyte 220 000/mm<sup>3</sup>, CRP value of 5 mg/L and sedimentation of 35 mm/h. Chest X-ray revealed interstitial infiltrates in both lungs (Figure 2). Arterial blood gases were consistent with hypoxemic respiratory failure (pH of: 7.46, pCO<sub>2</sub>: 33.2 mm Hg, pO<sub>2</sub>: 65 mm Hg, SO<sub>2</sub>: 93%). HIV testing was negative. High-resolution computed tomography (CT) showed numerous ill-defined centrilobular nodules, randomly distributed in both lungs with surrounding ground-glass attenuation (Figure 3). The diagnosis of varicella pneumonia was made, and in addition to supportive treatment, intravenous acyclovir (10 mg/kg every 8 hours), ampicilline/sulbactam were promptly initiated before serological results of varicella were obtained. Serum varicella IgM and IgG were found positive in follow up period. Excellent clinical evolution was documented. After 2 weeks of therapy, the patient was discharged fully recovered. Disappearance of the nodules and interstitial infiltration was detected in high resolution-CT one month after the treatment (Figure 4).

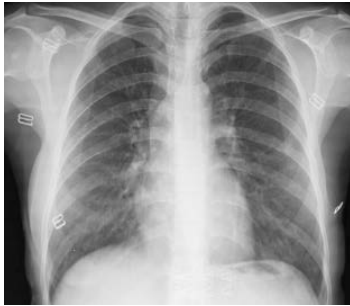**Discussion**

Although varicella infections mostly have good prognosis, varicella infections can cause complications in adults especially immunocompromised patients. Secondary bacterial infections of the skin (50%), pneumonia

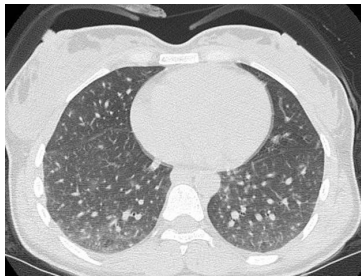
\*Corresponding Author: Neslihan Çelik, MD; Infectious Disease and Clinical Microbiology, Erzurum Region Training and Research Hospital, Turkey. 25240 Yakutiye/Erzurum. Tel: +904422325330, Email: dmeslihançelik@yahoo.com.tr



**Figure 1.** Multiple Vesicles, Pustules and Crusty Skin Lesion.



**Figure 2.** Interstitial Infiltrates in Both Lungs.

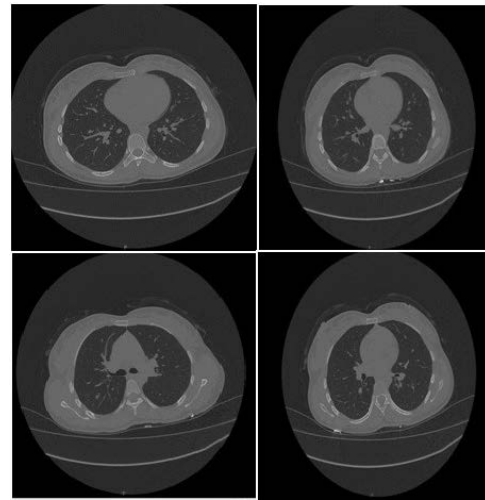


**Figure 3.** Numerous Ill-Defined Centrilobular Nodules, Randomly Distributed in Both Lungs With Surrounding Ground-Glass Attenuation.

(13.5%), and neurological complications (8.4%) are the most prevalent complications in children. While in adults, pneumonia (43.4%), thrombocytopenia (22.2%), and secondary bacterial infections of the skin (14.8%) are the most prevalent.<sup>4</sup> Pneumonia complications have high mortality rate. Incidence of pneumonia in adults (0.32-1.36 /100 000/year) is 25 times higher than in children.<sup>5</sup>

Varicella pneumonia usually presents 1–6 days after the onset of the rash and is associated with tachypnoea, chest tightness, cough, dyspnoea, fever and occasionally with pleuritic chest pain and haemoptysis. However, chest symptoms may appear before skin rash eruption.<sup>6</sup> In our case report, the patient had fever, sputum, cough, and shortness of breath 2 days after the onset of rash.

The risk factors for acute lung injury due to varicella infection are as the following: male sex, being an adult, smoking, greater than 100 skin lesions, pregnancy



**Figure 4.** Disappearance of the Nodules and Interstitial Infiltration in High Resolution-CT 1 Month After the Treatment.

and close contact with an infected person or any immunosuppression states.<sup>6</sup> In our case, there was history of contact with index case, but no history of immunocompromisation or pregnancy. She had severe rash and number of skin spots were greater than 100.

Varicella pneumonia is diagnosed on the basis of contact with index case, history, and radiological findings.<sup>7,8</sup> High-resolution CT showed numerous ill-defined centrilobular nodules 5–10 mm, randomly distributed in both lungs with surrounding ground-glass attenuation.<sup>9</sup> In our case, radiologic findings were consistent with previous reports. Kaaniche et al presented a varicella pneumonia patient with 5–10 mm diameter nodules. Most of them were round edged and surrounded by diffuse ground glass. They also reported 2 right pneumatoceles which were not previously reported in patients with varicella pneumonia. These features can be related to the varicella pneumonia itself, but may also be explained by consequences of mechanical ventilation.<sup>6</sup> Diagnosis was made by high resolution tomography and serological findings. It is accepted by most of physicians that treatment with high dose intravenous acyclovir in life threatening varicella pneumonia increases prognosis.<sup>10–12</sup> In our case, we started intravenous acyclovir immediately after radiological and clinical evaluations. Because of the risk of secondary bacterial infection, ampicilline/sulbactam treatment was added. In other case, early antiviral treatment of varicella pneumonia with acute respiratory failure leading to mechanical ventilation finally had good prognosis.<sup>6</sup>

As a result, varicella pneumonia must be considered in varicella patients with symptoms of cough, shortness of breath and sputum. Radiological and laboratory evaluations should be done immediately. As varicella pneumonia has high mortality in adults, acyclovir

treatment must be initiated as early as possible. In our case, early diagnosis and treatment gave us a satisfactory result.

It has been suggested that universal infant immunisation against varicella would not be possible in low or middle income countries, and high-risk groups such as immunocompromised individuals or healthcare workers should be targeted for vaccination instead. But here again, more epidemiological data would be needed to inform such decisions. Furthermore, if the rates of VZV complications and/or hospitalisation were found to be high, it would provide strong evidence for wider accessibility of drugs such as acyclovir.<sup>1</sup>

#### Authors' Contribution

NÇ and OÇ participated in conducting the practice and designing case report. NÇ wrote the draft of manuscript. All authors revised subsequent drafts of the paper. OÜ and OÇ prepared this manuscript for publication.

#### Conflict of Interest Disclosures

The authors have no conflicts of interest.

#### Ethical Statement

Written informed consent was obtained from the patient for publishing this case report.

#### References

- Hussey HS, Abdullahi LH, Collins JE, Muloiwa R, Hussey GD, Kagina BM. Varicella zoster virus-associated morbidity and mortality in Africa: a systematic review protocol. *BMJ Open*. 2016;6(4):e010213. doi: 10.1136/bmjopen-2015-010213.
- Choo PW, Donahue JG, Manson JE, Platt R. The epidemiology of varicella and its complications. *J Infect Dis*. 1995;172(3):706-12.
- Megged O, Schlesinger Y. Varicella zoster infection in adults: a preventable disease. *Isr Med Assoc J*. 2009;11(5):306-7.
- Rivest P, Bedard L, Valiquette L, Mills E, Lebel MH, Lavoie G, et al. Severe complications associated with varicella: Province of Quebec, April 1994 to March 1996. *Can J Infect Dis*. 2001;12(1):21-6.
- Gregorakos L, Myrianthefs P, Markou N, Chroni D, Sakagianni E. Severity of illness and outcome in adult patients with primary varicella pneumonia. *Respiration*. 2002;69(4):330-4. doi: 10.1159/000063274.
- Kaaniche FM, Chaari A, Ammar R, Bahloul M, Bouaziz M. Varicella Pneumonia in an Immunocompetent Adult: A Case Report. *J Clin Diagn Res*. 2015;3(1):116. doi: 10.4172/2376-0311.1000116.
- Shirai T, Sano K, Matsuyama S, Honjo Y, Takashima M, Sasada Y, et al. Varicella pneumonia in a healthy adult presenting with severe respiratory failure. *Intern Med*. 1996;35(4):315-8.
- Ogawa K, Sanno K, Tatsuta H, Ashitaka T, Mori K, Kinoshita M, et al. [Primary varicella pneumonia with respiratory failure]. *Nihon Kyobu Shikkan Gakkai Zasshi*. 1995;33(12):1436-40.
- Kim EA, Lee KS, Primack SL, Yoon HK, Byun HS, Kim TS, et al. Viral pneumonias in adults: radiologic and pathologic findings. *Radiographics*. 2002;22 Spec No:S137-49. doi: 10.1148/radiographics.22.suppl\_1.g02oc15s137.
- Mer M, Richards GA. Corticosteroids in life-threatening varicella pneumonia. *Chest*. 1998;114(2):426-31.
- Potgieter PD, Hammond JMJ. Intensive care management of varicella pneumonia. *Respir Med*. 1997;91(4):207-12. doi: 10.1016/S0954-6111(97)90040-8.
- Gogos CA, Bassaris HP, Vagenakis AG. Varicella pneumonia in adults. A review of pulmonary manifestations, risk factors and treatment. *Respiration*. 1992;59(6):339-43. doi: 10.1159/000196084.