

Original Article

Prevalence and Characteristics of Coronary Artery Anomalies Using Invasive Coronary Angiography in 6237 Consecutive Patients in a Single Center in Turkey

Kenan Erdem, MD^{1*}; Yilmaz Ozbay, PhD²¹Department of Cardiology, Medova Hospital, Konya, Turkey²Department of Cardiology, Medical Faculty of Amasya University, Amasya, Turkey**Abstract**

Background: Coronary artery anomalies (CAAs) include clinically and anatomically diverse types of congenital heart defects occurring in a complicated spectrum. The aim of the present study is to describe congenital anomalies of coronary arteries (CAs) and their variations, and also identify the prevalence of these anomalies in our center.

Methods: The study included a total of 6237 consecutive patients. Cine-angiographies and digital data of all patients undergoing coronary angiography (CAG) were reviewed by at least 2 independent and experienced observers. The Basic Anatomic Classification method was used to classify patients with CAAs.

Results: Of a total of 6237 patients, 2,313 were females (37.1%) and 3924 (62.9 %) were males. CAAs were detected in 247 out of 6237 patients (3.9%, 95% CI: 3.4–4.4). Of these patients, 48 (19.4%, 95% CI: 14.4–24.2) had absent left main coronary artery (LMCA), 21 (8.5%, 95% CI: 5–11.9) had anomalous origin from the appropriate sinus, 23 (9.3%, 95% CI: 5.7–12.9) had anomalous origin from structures other than appropriate sinus, 31 (12.6%, 95% CI: 8.5–16.6) had anomalous origin from the opposite sinus, 101 (40.9%, 95% CI: 34.8–46.9) had myocardial bridge, and 23 (9.3%, 95% CI: 5.7–12.9) had a coronary artery fistula.

Conclusions: Our study results suggested that the total rate of coronary anomaly was found much higher than those reported in various invasive angiographic studies.

Keywords: Coronary angiography, Coronary artery anomalies, Sudden death

Cite this article as: Erdem K, Ozbay Y. Prevalence and characteristics of coronary artery anomalies using invasive coronary angiography in 6237 consecutive patients in a single center in Turkey. Arch Iran Med. 2018;21(6):240–245.

Received: July 3, 2017, Accepted: April 25, 2018, ePublished: June 1, 2018

Introduction

Coronary artery anomalies (CAAs) include clinically and anatomically diverse types of congenital heart defects occurring in a complicated spectrum.¹ In the second half of the twentieth century, the focus of cardiologists has shifted to coronary artery anatomy with widespread use of coronary angiography (CAG). In 1965, Baroldi and Scomazonni published an excellent monograph summarizing what was known about normal anatomy of coronary arteries (CAs).² During this period, studies in the Armed Forces Institute of Pathology in Washington, United States, have attempted for the first time, to classify CAAs.³

The patients with CAAs are often asymptomatic and the anomalies are incidentally detected. However, some anomalies may result in angina pectoris, myocardial infarction, congestive heart failure or sudden death if they impair myocardial perfusion.³ CAAs are the cause of sudden deaths in athletes in 19 to 24% of the cases.⁴ Clinical consequences of CAAs must be therefore

well understood and “malignant” anomalies must be differentiated from “benign” anomalies. The reports of autopsy series indicate a rate of 1% for CAAs. The rate of CAAs ranges from 0.6% to 1.3% according to CAG results.^{5–8} Based on computed tomography angiography results, the incidence of CAAs ranges from 0.3% to 5.6% in general population.^{9,10}

Although CAAs have attracted the interest of clinicians and anatomists for years, they are regarded as rare anomalies of no clinical significance.⁸ With the widespread use of CAG, CAAs have been recognized more frequently, and clinicians have begun to gain better insight into their clinical significance.⁹ Although development of new diagnostic methods have contributed greatly to our understanding of CAAs, current data mostly rely on case reports and small case series. Considering the fact that epidemiological data are derived from the studies conducted in other countries, further studies are required to fill the knowledge gap on clinical consequences of CAAs and their prognosis. In the present study, we aimed

*Corresponding Author: Kenan Erdem, MD; Department of Cardiology, Medova Hospital, Konya, Turkey, 42075 Konya/Turkey. Tel: +90-50-65750266, Email: erdem.kenebr@yahoo.com.

to investigate prevalence and characteristics of CAAs using invasive CAG in Turkey.

Materials and Methods

Patients Group

In this study, we performed a retrospective examination of the medical records of all patients who underwent CAG in cardiac catheterization laboratory of Department of Cardiology at Firat University, Faculty of Medicine, between January 2005 and December 2007.

Coronary Angiography

After obtaining medical history and performing physical examination and laboratory tests, patients with an indication for CAG were informed of CAG procedure details. After obtaining informed consent, patients without contraindications for the procedure were transferred to the catheterization laboratory for diagnosis and treatment.

The imaging was performed using POLY C2 OM 2000 MRC DCI model (Philips, Eindhoven, Nederland) imaging device installed at our catheterization laboratory.

The Seldinger technique, also known as percutaneous needle-guidewire-dilator technique, was used in the procedure. Catheterization was most frequently performed through the right femoral artery, and less frequently through the left femoral artery and brachial artery.

Selective CAG was often performed using Left and Right Judkins catheters (JR 3.5, 4, 5, 6 and JL 3.5, 4, 4.5, 5 and 6) and less frequently using Amplatz (AR I, II, III and AL I, II, III) and Multipurpose (A, B, C) catheters, whereas left heart catheterization and aortography were performed using pigtail catheters.

Left coronary system was visualized using at least four projections and right coronary system was visualized using at least 2 projections, and the images were recorded on a digital memory. Left heart catheterization was performed in all patients with normal renal function who were suspected of having anomalous CAs. Some patients also underwent aortography in addition to these procedures. Patients with valvular heart diseases or congenital heart disease underwent selective CAG, left ventriculography, and aortography after obtaining hemodynamic parameters and measuring blood oxygen

saturation.

Assessment and Classification of Patients

Cine-angiographies and digital data of all patients undergoing CAG were reviewed by at least 2 independent and experienced observers. The Basic Anatomic Classification method was used to classify patients with CAAs and the patients were divided into four groups.¹¹

Statistical Analysis

Descriptive statistics were performed. Frequencies were calculated with %95 confidence interval. The Statistical Package for Social Sciences (SPSS) program version 16 was used to analyze data.

Results

The study included a total of 6237 cases. Of these cases, 2313 patients were females (37.1%) and 3924 patients were males (62.9%). Selective CAG was performed in 5926 patients with the preliminary diagnosis of atherosclerotic heart disease. 311 cases with valvular diseases and atherosclerotic heart disease underwent selective CAG and right heart catheterization.

Using basic anatomical classification, a total of 247 (3.9%) cases with anomalous CAs were detected among 637 patients undergoing CAG. The mean age of these cases was 52.4 ± 10.8 years. Of these patients, 36.4% ($n = 90$) were females and 63.6% ($n = 157$) were males. Considering all anomalies of CAs in general classification, 123 cases (49.8%, 95% CI: 46.5–53.0) had coronary anomalies of origin and course, 101 cases (40.9%, 95% CI: 34.8–46.9) had anomalies of intrinsic coronary arterial anatomy, 23 cases (9.3%, 95% CI: 5.7–12.9) had anomalies of coronary termination, whereas no patient (0%) had anomalous collateral vessels (Table 1).

As mentioned earlier, there were 123 cases with coronary anomalies of origin and course (the mean age was 54.6 ± 10.1 years; 44.7% [$n = 55$] were females and 55.3% [$n = 68$] were males). Subgroup analysis for these anomalies revealed that 48 cases (the mean age was 56.3 ± 10.8 years; 43.8% [$n = 21$] were females and 56.2% were males [$n = 27$]) had absent left main coronary artery (LMCA). Twenty one cases (the mean age was 50.7 ± 9.3 years; 47.6% [$n = 10$] were females and 52.4% [$n = 11$] were males) had anomalous origin from appropriate sinus (high take-off, low take-off, commissural origin).

Table 1. Anomalies of Coronary Arteries in General Classification

	Number of Patients (n)	n%, 95% CI
Coronary anomalies of origin and course	123	49.8, 46.5–53.0
Intrinsic coronary arterial anatomy	101	40.9, 34.8–46.9
Anomalies of coronary termination	23	9.3, 5.7–12.9
Anomalous collateral vessels	0	0
Total	247	100

Table 2. Subgroup Analysis for Coronary Anomalies of Origin and Course

	Number of Patients (n)	n%, 95% CI
Absent left main coronary artery	48	39.0, 30.4–47.5
Anomalous origin from appropriate sinus	21	17.1, 10.5–23.5
Anomalous origin outside normal coronary sinuses	23	18.7, 11.8–25.5
Anomalous origin from opposite coronary sinus	31	25.2, 17.5–32.8
Total	123	100

Twenty-three cases (the mean age was 53.4 ± 8.8 years; 34.8% [n = 8] were females and 65.2% [n = 15] were males) had anomalous origin outside normal coronary sinuses. All cases in this group had anomalous origin of CAs from noncoronary sinus. Thirty-one cases (the mean age was 56.8 ± 10.1 years; 45.2% [n = 14] were females and 54.8% [n = 17] were males) had anomalous origin from opposite coronary sinus. Two cases had anomalous origin of the left main stem (LM) from the right sinus of Valsalva, 2 cases had anomalous origin of the right coronary artery (RCA) from the left sinus of Valsalva, 27 cases had anomalous origin of Circumflex artery (Cx) from the right sinus of Valsalva or proximal to the RCA (Table 2, Figures 1, 2, 3).

There were 101 cases [the mean age was 49.3 ± 10.1 years; 17.8% (n = 18) were females and 82.2% (n = 83) were males] with anomalies of intrinsic coronary arterial anatomy. All cases in this group had myocardial bridging. Myocardial bridging was located in the left anterior descending coronary artery (LAD) in all, but 2 cases. In

these 2 cases, myocardial bridging involved RCA in one and internal mammary artery (rMA) in the other.

In terms of anomalies of coronary termination, 23 cases (the mean age was 60.1 ± 11.1 years; 52.2% [n=12] were females and 47.8% [n=11] were males) had coronary artery fistulas. Of 23 cases, 11 had fistulas to the right ventricle, 5 had fistulas to the right atrium, 4 had fistulas to the pulmonary artery, 2 had fistulas to the left atrium, and 1 had fistula to the left ventricle (Table 3, Figure 3A).

Discussion

The present study found CAAs in 247 patients out of 6237 cases undergoing CAG. The total rate of coronary anomaly was found to be 3.9%. This rate is much higher than those reported in various invasive angiographic studies. The use of diverse classification systems for evaluation of CAAs is one of the main reasons for this high rate reported in the present study. Many researchers do not recognize myocardial bridging as a coronary artery anomaly, and exclude this entity from the classification of anomalous CAs.^{12,13} If the present study had excluded cases with myocardial bridging (n = 101) leaving this entity out of classification, the total rate of anomalous CAs would be 2.3%. Even this rate still remains higher than those reported in other studies.

Technological innovations, advances in imaging systems, and increasing level of experience have led to better recognition and detection of these anomalies.¹¹ Even so, it is well known that there could be differences in the incidence of CAAs between various regions and populations.¹⁴ Although there is a lack of knowledge regarding the inheritance pattern of CAAs, high rates of consanguineous marriage in the study site of Upper

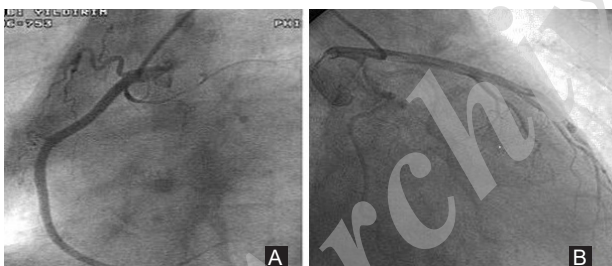


Figure 1. (A) Angiographic View of High Taking-Off Coronary Artery in 45 Degrees Left Oblique Projection; (B) Angiographic View of Left Coronary Artery With Posterior Origin in 45 Degrees Right and 30 Degrees Caudal Projections.

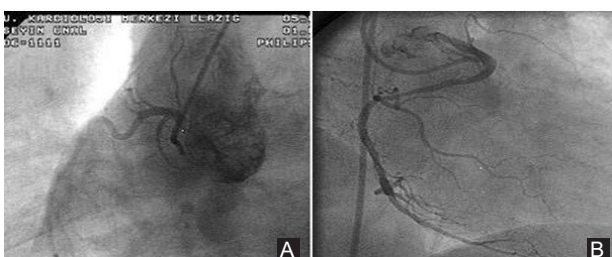


Figure 2. (A) Angiographic View of Right Coronary Artery (RCA) With Posterior Origin in 45 Degrees Left Oblique Projection; (B) Angiographic View of The RCA Originating From the Left Sinus of Valsalva in 45 Degrees Left Oblique Projection.

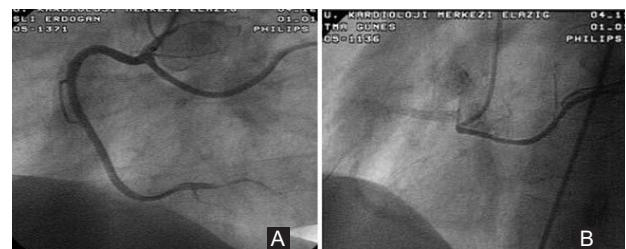


Figure 3. (A) Angiographic View of the Circumflex Artery Originating Proximal to the Right Coronary Artery (RCA) in 45 Degrees Left Oblique Projection; (B) Angiographic View of the Circumflex Artery Originating From the Right Sinus of Valsalva in 45 Degrees Left Oblique Projection

Table 3. Characteristics of Coronary Artery Anomalies

	Number of Patients (n)	n%, 95% CI
Absent left main coronary artery	48	19.4, 14.4–24.2
Anomalous origin from appropriate sinus	21	8.5, 5–11.9
Anomalous origin outside normal coronary sinuses	23	9.3, 5.–12.9
Anomalous origin from opposite coronary sinus	31	12.6, 8.5–16.6
Myocardial bridging	101	40.9, 34.8–46.9
Coronary fistula	23	9.3, 5.7–12.9
Coronary artery anomalies	247	100

Firat Basin might be the cause of high rates observed for CAAs.

There is no accurate data regarding the rate of coronary anomalies of origin and course in general population. Postmortem studies and studies evaluating individuals exhibiting the symptoms of coronary artery disease have reported a rate ranging from 0.2% to 1.2%.^{3,8} This rate was found to be 1.6% in the present study, which is higher than the literature data. The rate of these anomalies can be expected to be higher in adult populations due to limited number of studies on this subject and also inclusion of only those patients who exhibit the symptoms of coronary artery disease in available studies.⁷

Absent LMCA is the most common form of the anomalies of origin and course. In one of the most comprehensive studies on CAAs conducted by Yamanaka and Hobbs, absent LMCA was found to be the most common coronary artery anomaly accounting for 0.41% of the cases. Topaz et al¹⁵ also reported a rate of 0.4% for absent LMCA, whereas Angelini et al reported a rate of 0.55%.¹⁶ The present study reported a rate of 0.7% for absent LMCA. Considering high rate of coronary anomalies reported in the present study, the rate reported for absent LMCA is partially consistent with the literature. In angiographic views, it may be sometimes difficult to differentiate absent from very short LMCA. Catheter tip may be selectively introduced into LAD or Cx and this may give the impression of a separate opening. Furthermore, absence of LMCA is not associated with hemodynamic disturbance and it is regarded as a benign anomaly. Considering all these factors, some researchers did not diagnose absent LMCA as a coronary anomaly and did not pay attention as this entity deserves.^{8,9} It is important to diagnose this anomaly while performing CAG. If not diagnosed, this can be interpreted as complete occlusion or congenital absence of one coronary artery. This may cause planning unnecessary revascularization procedures.¹¹

Anomalous origin of CAs from appropriate sinuses and anomalous origin outside normal coronary sinuses are not associated with any symptoms and sign in general population. For this reason, some researchers have also excluded this group of patients from classification.¹⁷ The

rate of these anomalies has been reported to be 0.5%–0.9% in the literature. Consistent with other studies, the rate of these anomalies was found to be 0.7% in the present study.

Circumflex artery arising from the right sinus of Valsalva or proximal RCA is one of the most common anomalous origins from opposite coronary sinus. The incidence of this anomaly was reported to be 0.45% by Chaitman et al, 0.7% by Engel et al and 0.37% by Kimbiris et al.^{8,18,19} The incidence of this anomaly was 0.43% in the present study (n = 27). All authors working on CAAs have included these anomalies in the classification due to their remarkable anatomic diversity. The incidence of anomalies in the present study is consistent with those reported in the literature. In all cases with anomalous origin of Cx artery reported in the literature, the vessel shows a normal course by running posterior to the aorta as was the case in the present study.⁶

The incidence rates reported for anomalous origin of RCA from the left sinus of Valsalva in the literature range from 0.07% to 0.19%.^{8,18,19} The rate of this anomaly was 0.03% in the present study. It is unknown to what extent this anomaly contributes coronary circulation. After arising from the left sinus of Valsalva, RCA shows a normal course by running between aorta and pulmonary artery.

The incidence rate for LMCA arising from the right aortic sinus was reported to be 0.17% in a large scale study conducted by Yamanaka and Hobbs.⁶ Angelini reported an incidence rate of 0.15%.³ The incidence rate was found to be 0.03% in Turkish population.¹¹ Consistent with the data on Turkish population, the present study reported a rate of 0.03%. More studies have focused on this anomaly after the reports of sudden deaths in cases with anomalous origin of LMCA.¹⁹ Chaitlin et al reported sudden cardiac deaths in 9 out of 33 cases with LMCA detected on autopsy; they reported no pathology in these cases other than this anomaly.²⁰

Myocardial bridging is another subject on which there is an ongoing debate. The results are controversial when the subject is reviewed in light of the studies.¹¹ The incidence of myocardial bridging is considerably variable in pathologic and angiographic studies. The incidence

has been reported to be 58% in case series studied by histological methods, whereas the incidence ranges from 0.5% to 4.5% in case series studied by angiography. Consistent with angiographic studies, the rate of this anomaly was 1.6% in the present study. Besides, high incidence rates reported in pathologic studies and low rates reported in angiographic studies suggest that myocardial bridging is not associated with cardiac events in most cases.²¹

Coronary artery fistulas are the most common congenital CAAs that are of hemodynamic importance. Approximately half of coronary artery fistulas arise from RCA. In majority of the remaining cases fistulas arise from the left coronary artery. Fistulas arise from both RCA and left CAs in 5% of the cases.^{22,23} Of coronary artery fistulas, approximately 40% drain into the right ventricle, 25% drain into the right atrium, 15% drain into the pulmonary artery, 7% drain into the coronary sinuses, 5% drain into the left atrium, and 3% drain into the left ventricle. The incidence of coronary artery fistulas ranges from 0.1% to 0.26% in angiographic studies.²⁴ The incidence of coronary artery fistulas was 0.4% in the present study. This result is consistent with the literature. Consistent with the data in other studies, right heart chambers are the most common drainage sites for the fistulas.

In conclusion, anatomical and clinical characteristics of CAAs have not been well established due to their rare occurrence. Many cases with anomalous CAs that are regarded of no clinical significance may face the risk of myocardial ischemia, decreased life span and even sudden cardiac death. CAAs are still the third most common cause of death in young individuals. Increasing understanding of CAAs will clarify their clinical significance and consequences more.

Authors' Contribution

Both authors contributed equally to this study.

Conflict of Interest Disclosures

The authors have no conflicts of interest.

Acknowledgments

The authors would like to thank all cardiac catheterization laboratory staff of Department of Cardiology at Firat


Ethical Statement

The current study was approved by the Ethics Committee of Firat University of Medical Sciences.

References

- Shriki JE, Shinbane JS, Rashid MA, Hindoyan A, Withey JG, DeFrance A, et al. Identifying, characterizing, and classifying congenital anomalies of the coronary arteries. *Radiographics*. 2012;32(2):453-68. doi: 10.1148/rg.322115097.
- Baroldi G, Scomazzoni G. Coronary circulation in the normal and pathologic heart. Washington DC: Armed Forces Institute of Pathology; 1965:1-37.
- Angelini P. Normal and anomalous coronary arteries: definitions and classification. *Am Heart J*. 1989;117(2):418-34.
- Maron BJ, Thompson PD, Puffer JC, McGrew CA, Strong WB, Douglas PS, et al. Cardiovascular preparticipation screening of competitive athletes. A statement for health professionals from the Sudden Death Committee (clinical cardiology) and Congenital Cardiac Defects Committee (cardiovascular disease in the young), American Heart Association. *Circulation*. 1996;94(4):850-6.
- Krasuski RA, Magyar D, Hart S, Kalahasti V, Lorber R, Hobbs R, et al. Long-term outcome and impact of surgery on adults with coronary arteries originating from the opposite coronary cusp. *Circulation*. 2011;123(2):154-62. doi: 10.1161/circulationaha.109.921106.
- Yamanaka O, Hobbs RE. Coronary artery anomalies in 126,595 patients undergoing coronary arteriography. *Cathet Cardiovasc Diagn*. 1990;21(1):28-40.
- Topaz O, DeMarchena EJ, Perin E, Sommer LS, Mallon SM, Chahine RA. Anomalous coronary arteries: angiographic findings in 80 patients. *Int J Cardiol*. 1992;34(2):129-38.
- Kimbiris D, Iskandrian AS, Segal BL, Bemis CE. Anomalous aortic origin of coronary arteries. *Circulation*. 1978;58(4):606-15.
- Angelini P. Coronary artery anomalies: an entity in search of an identity. *Circulation*. 2007;115(10):1296-305. doi: 10.1161/circulationaha.106.618082.
- Kim SY, Seo JB, Do KH, Heo JN, Lee JS, Song JW, et al. Coronary artery anomalies: classification and ECG-gated multi-detector row CT findings with angiographic correlation. *Radiographics*. 2006;26(2):317-33; discussion 33-4. doi: 10.1148/rg.262055068.
- Kursaklioglu H, Iyisoy A, Celik T, Gunay C. Koroner arter anomalileri. In: Oto A, ed. Koroner arter anomalileri. Ankara: Ertem Tıbbi Yayıncılık; 2005:16-81.
- Topaz O, Edwards JE. Pathologic features of sudden death in children, adolescents, and young adults. *Chest*. 1985;87(4):476-82.
- Grani C, Benz DC, Schmied C, Vontobel J, Possner M, Clerc OF, et al. Prevalence and characteristics of coronary artery anomalies detected by coronary computed tomography angiography in 5 634 consecutive patients in a single centre in Switzerland. *Swiss Med Wkly*. 2016;146:w14294. doi: 10.4414/sm.w.2016.14294.
- Kursaklioglu H, Iyisoy A, Celik T, Isik E. Koroner Arter Anomalilerinin Klinik Yansımaları ve Koroner arter anomalilerinde Girişimsel Tedavi. *Koroner Arter Anomalileri*. Ankara: Ertem Tıbbi Yayıncılık; 2005:114-24.
- Topaz O, DiSciascio G, Cowley MJ, Soffer A, Lanter P, Goudreau E, et al. Absent left main coronary artery: angiographic findings in 83 patients with separate ostia of the left anterior descending and circumflex arteries at the left aortic sinus. *Am Heart J*. 1991;122(2):447-52.
- Angelini P, Villason S, Chan AV Jr, Diez JG. Normal and anomalous coronary arteries in humans. In: Angelini P, ed. *Coronary artery anomalies*. Philadelphia: Lippincott Williams & Wilkins; 1999:27-150.
- Fernandes ED, Kadivar H, Hallman GL, Reul GJ, Ott DA, Cooley DA. Congenital malformations of the coronary arteries: the Texas Heart Institute experience. *Ann Thorac Surg*. 1992;54(4):732-40.
- Engel HJ, Torres C, Page HL Jr. Major variations in anatomical origin of the coronary arteries: angiographic observations in 4,250 patients without associated congenital heart disease. *Cathet Cardiovasc Diagn*. 1975;1(2):157-69.
- Chaitman BR, Lesperance J, Saltiel J, Bourassa MG. Clinical, angiographic, and hemodynamic findings in patients with anomalous origin of the coronary arteries. *Circulation*.

- 1976;53(1):122-31.
20. Cheitlin MD, De Castro CM, McAllister HA. Sudden death as a complication of anomalous left coronary origin from the anterior sinus of Valsalva, A not-so-minor congenital anomaly. *Circulation*. 1974;50(4):780-7.
 21. Noble J, Bourassa MG, Petittlerc R, Dyrda I. Myocardial bridging and milking effect of the left anterior descending coronary artery: normal variant or obstruction? *Am J Cardiol*. 1976;37(7):993-9.
 22. Seon HJ, Kim YH, Choi S, Kim KH. Complex coronary artery fistulas in adults: evaluation with multidetector computed tomography. *Int J Cardiovasc Imaging*. 2010;26(Suppl 2):261-71. doi: 10.1007/s10554-010-9718-9.
 23. Gupta PD, Rahimtoola SH, Miller RA. Single coronary artery--right ventricle fistula. *Br Heart J*. 1972;34(7):755-7.
 24. de Nef JJ, Varghese PJ, Losekoot G. Congenital coronary artery fistula. Analysis of 17 cases. *Br Heart J*. 1971;33(6):857-62.

 © 2018 The Author(s). This is an open-access article distributed under the terms of the Creative Commons Attribution License (<http://creativecommons.org/licenses/by/4.0>), which permits unrestricted use, distribution, and reproduction in any medium, provided the original work is properly cited.

Archive of SID