

Original Article

Novel Mutations in the $\beta 2$ Integrin Gene (*ITGB2*) in a Moderate Leukocyte Adhesion Defect type 1 Patient

Jianxia Hu, MD^{1*}; Qiuye Zhang, MD^{2*}; Hongying Zheng, MD³; Hong Chang, MD²; Yuwei Xian, MD⁴; Nana Nie, MD²; Yi Lin, MD^{2*}¹Laboratory of thyroid disease, the Affiliated Hospital of Qingdao University, Qingdao, China²Pediatrics Department, the Affiliated Hospital of Qingdao University, Qingdao, China³Clinical Laboratory, the Affiliated Hospital of Qingdao University, Qingdao, China⁴Department of Ultrasound, Qingdao Municipal Hospital, Qingdao, China**Abstract****Background:** Leukocyte adhesion deficiency type 1 (LAD1) is an autosomal recessive disorder caused by reduced expression or function of CD18. It was well accepted that LAD1 resulted from mutations in the gene for the integrin $\beta 2$ subunit.**Methods:** We reported a moderate LAD1 patient with 2 novel *ITGB2* mutations, and further investigated the role of the 2 mutations on the expression and function of CD18 by gene transfection.**Results:** The 2 novel mutations included a frameshift deletion viz c.954G del, which was considered as a major pathogenic gene for the patient, and a missense mutation viz c.1802C>A (Cys601Phe), which caused a damaging effect on the *ITGB2* protein. There was no significant difference in protein expression between 293 T cells with mutant *ITGB2* p.601C>F and 293 T cells with wild type *ITGB2*. When investigating the cellular location of the mutant *ITGB2* in HeLa cells, we found that the mutant *ITGB2* (p.601C>F) protein could not locate to the cell membrane. This indicated that the mutant *ITGB2* protein could not perform its function at cell membrane level.**Conclusion:** The 2 novel *ITGB2* mutations affected the expression and function of CD18 and might be pathogenic genes for LAD1.**Keywords:** Gene mutations, *ITGB2*, Leukocyte adhesion deficiency type 1**Cite this article as:** Hu J, Zhang Q, Zheng H, Chang H, Xian Y, Nie N, Lin Y. Novel mutations in the $\beta 2$ integrin gene (*ITGB2*) in a moderate leukocyte adhesion defect type 1 patient. Arch Iran Med. 2018;21(7):296–301.

Received: December 29, 2017, Accepted: April 17, 2018, ePublished: June 1, 2018

Introduction

Leukocyte adhesion deficiency (LAD) is an autosomal recessive disorder caused by reduced expression/function of CD18. This deficiency leads to severe impairment of leukocyte adhesion to the vascular wall and leukocyte migration to sites of infection and inflammation. LAD includes three subtypes: LAD1, LAD2 and LAD3. Among them, LAD1 is the most common although the incidence of LAD1 in the population is extremely low, with an incidence of 1/10 million.¹

It was accepted that LAD1 (OMIM number 116920) resulted from mutations in the integrin $\beta 2$ subunit gene (Integrin $\beta 2$, *ITGB2*, OMIM number 600065), which is located on the long arm of chromosome 21q22.3 and also known as the CD18 subunit of the CD11/CD18 leukocyte antigens.² $\beta 2$ integrins exist as heterodimers composed of one α chain (CD11a, CD11b, CD11c or CD11d) non-covalently linked to the $\beta 2$ subunit (CD18).³ Combination of both CD11 and CD18 subunits was essential to maintain their normal surface-membrane expression and function.⁴ Failure to produce a functional $\beta 2$ subunit could result in defective membrane expression of all $\beta 2$ integrins, and thus generating abnormal adhesive

properties and the clinical features of LAD1.^{5,6}

Defects in the *ITGB2* gene affected leukocyte migration mediated by adhesive interactions between leukocytes and inflamed endothelial cells, which were critical for defense against bacteria and wound healing. Hence, LAD1 was characterized by leukocytosis, recurrent infections, impaired pus formation and slow wound healing.⁷ The severity of infections and complications was associated with severity of CD18 deficiency. Cases with <1% expression were clinically severe, while those with 2.5%–10% expression were moderate to mild. Many LAD patients died at young age despite intensive antibiotic therapy.^{8,9}

A range of mutations in the CD18 gene have been identified in patients with LAD1.^{3,10} Few mutations could cause a nonfunctional but normal expressed CD18 molecule. Most *ITGB2* mutations lead to reduced/null expression of $\beta 2$ -integrins on the leukocyte surface.^{3,5} In the present study, we reported a moderate LAD1 patient and characterized 2 novel *ITGB2* mutations in the patient; one was a frameshift mutation (c.954G del), and the other was a missense mutation (c.1802C>A), inducing cysteine replaced by proline (p.C601F). Also, we

*Corresponding Author: Yi Lin, MD; No.16, Jiangsu Road, Qingdao, Shandong Province, China. 266003. Email: qdyxlyx@163.com

† These authors contributed equally to this work.

further investigated the role of the 2 mutations on the expression and function of CD18.

Materials and Methods

Patient

The patient was a Chinese girl (Han nationality) born in 2006. Her parents were not known to be related. At initial diagnosis, detailed clinical history of the patient was recorded. After informed consent from the parents of the patient was obtained, 10 mL of blood was collected in EDTA vacutainer from the patient and her parents for hematological and molecular analysis on 18th of December, 2014.

Flow Cytometric Analysis of CD18 Expression

Expression of CD18 was examined on peripheral blood leukocytes by flow cytometry. Briefly, whole blood stain-lyse-wash protocol was used for sample processing and BD FACS lysing solution was used for erythrocyte lysis. Then, the cells were stained for surface antigens with a panel of monoclonal antibodies consisting of PE-labeled anti-CD18 and γ 1-FITC isotype control (BD Biosciences, Mountain View, CA, USA). Data were acquired by FACS Aria flow cytometer (Becton-Dickinson, San Jose, CA, USA) and analyzed using the FACSDiva and the FlowJo v7.6.5 version software. The percentage of positive fluorescent events and ratio of median fluorescence intensity (MFI) of stained to unstained were recorded for CD18 on monocytes, lymphocytes and neutrophils.

Mutation Detection in the *ITGB2* Gene

Extractions of genomic DNA from peripheral blood of the patient and her parents were done using QIAamp DNA mini kit (Qiagen Inc, Germantown, MD). PCR amplification of 16 exons in the *ITGB2* gene (NCBI Ref seq: NG_007270.2) was done using specific primers covering 16 coding regions and exon-intron boundaries of the *ITGB2* gene. Purification of PCR products were done using ExoSAP-IT (USB Inc, Staufen, Germany). Big Dye terminator v3.1 cycle sequencing kit (Applied Biosystems, Foster City, CA, USA) was used for DNA sequencing reaction on automated DNA sequencer from Applied Biosystems 3130XL Genetic Analyzer (Applied Biosystems, Foster City, CA, USA). Sequencher 5.0 software was used for the analysis of DNA sequenced data. DNASTAR software was used for gene sequence alignment. Effect of mutations detected was evaluated using online prediction tools including PolyPhen-2, 23 Uniprot and HOPE. Both parents were tested for the detection of carrier status for the mutation identified in the index case.

Construction of the *ITGB2* Expression Vector

ITGB2 cDNA vector obtained from Dharmacon (BC005861) was used as the template to amplify the *ITGB2* coding sequence. PCR primer sequences were: B2-CDS-F1/AsiI: 5'-gcgatcgc ATGCTG GGCCTGC-GCCCCCAC-3'; B2-CDS-B1/MluI: 5'-acggtACTCT-CAGCAAACCTGGGGTTC. PCR product was then ligated to pGEM-T vector (Promega). Four primers were used to verify the *ITGB2* coding sequence after TA cloning: T7, SP6, B2-SEQ-F1 (5'-AAGGAGAAAGA GTGCCAGCC-3'), and B2-SEQ-B1 (5'-GCCACGACCAC-TACTACTCAA-3'). *ITGB2* CDS fragment was isolated by MluI and AsiI digestion and then inserted into pCMV6-entry to generate the final *ITGB2* expression vector: pCMV6-entry-*ITGB2*. Missense mutation (*ITGB2* p. 601 C>F) was introduced into pCMV6-entry-*ITGB2* using QuikChange Lightning site-directed mutagenesis kit (Agilent). Mutagenesis primers were: MU-F (5'-ATG-GCACTCGAATACGTTGCAGCGGCA CCG-3') and MU -B (5'-CGGTGCCGCTGCAACGTATTCGAGT-GCCAT-3').

Protein Expression Assay

Lenti-x 293 T cells were cultured in RPMI-1640 with 10 % FBS for up to 60 % confluence in 10-cm plates and then transfected with 5 μ g wild type or mutant *ITGB2* expression vectors, individually. Twenty-four hours later, cells from each plate were passaged to 6-well plates. After 12 hours, cells of each well were treated with 100 μ g/mL cycloheximide for 0, 2, 4, 6, or 8 hours before protein collection. Western blotting was performed with anti-FLAG antibody (M2, Sigma).

Cellular Location of WT and Mutant *ITGB2* in HeLa Cells

HeLa cells were plated on 2 wells of 8-well chamber slides with a density of 10000 per well. On the next day, 500 ng of either wild type or mutant *ITGB2* expression vectors were transfected into HeLa cells. Immunofluorescence staining was performed 2 days after transfection. Briefly, cells were fixed by 4% paraformaldehyde for 5 min., permeated in TBS (0.2% Triton X-100 in PBS) for 20 min., blocked by 4% goat serum in TBS for 30 min., and then stained with anti-FLAG (M2, Sigma, 1:200) antibody overnight at four degrees. Finally, cells were stained by goat anti-mouse IgG secondary antibody conjugated with Alexa Fluor 488 (ThermoFisher, A-11001, 1:1000) and DAPI (1:1000) for 45 min. before observation with confocal microscopy. The preparations were mounted in Vectashield (Vector Laboratories) and analyzed with an Olympus microscope using 409 or 609 objectives and the Olympus FluoView software was used for processing images.

Results

Clinical and Laboratory Findings

The girl was 11 years old. She was born as a full-term fetus with birth weight of 3500 g and height of 50 cm. The childbirth process was smooth with Apgar score of 10 points. Diagnosis of LAD1 was confirmed based on clinical and laboratory findings consisting of recurrent severe infections (almost 1-2 times per month), impaired pus formation and wound healing. She was admitted to the hospital this time due to a fever lasting for 25 days. Physical examination showed bilateral submandibular lymphadenectasis, bilateral cheek swelling and swollen gums, alveolar ridge atrophy, severe tooth agenesis and loose teeth. When examined for hematological parameters, the patient exhibited an elevated white blood cell (WBC) count of 23.16×10^9 /L, neutrophils at 17.89×10^9 /L, lymphocytes at 4.45×10^9 /L, platelets at 338×10^9 /L, hemoglobin at 78.0 g/L, and CRP at 64.13 mg/L. Etiological detection was negative for the EB virus, HIV and Mycoplasma. The levels of immunoglobulins were; IgG at 810.90 mg, IgM at 281.70 mg, IgA at 450.40

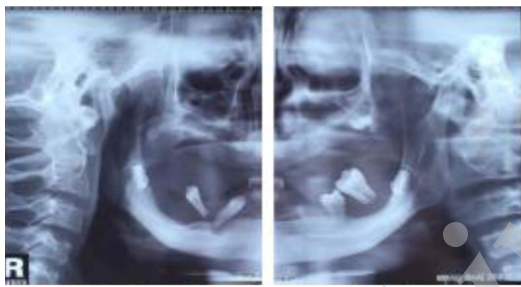


Figure 1. Teeth X-Ray Films of the Patient.

mg, and IgE at 67.48 mg. This patient did not accept any hematopoietic stem cell transplantation. Dental radiography showed multiple tooth agenesis (Figure 1).

Flow Cytometric Analysis of CD18 Expression

Flow cytometric analysis of expression levels of CD18 on patient monocytes, lymphocytes and granulocytes showed significantly lower values compared to normal controls (0.2% vs 99.0%, 0.6% vs 92.9%, 0.0% vs 99.9%, as shown in Figure 2).

Genomic DNA Sequencing of *ITGB2* Identified 2 Novel Mutations

The 16 exons and intron-exon boundaries of *ITGB2* from the patient and her parents were amplified using PCR. Direct sequencing of the PCR products revealed 2 novel mutations (different from the reference *ITGB2* genomic sequence): a frameshift deletion viz c.954G del (chr21, 46319021) and a missense mutation viz c.1802C>A (Cys601Phe, chr21, 46309266). A compound heterozygous mutation was observed in this patient (954G del & 1802C/A). The frameshift mutation was found in her father (954G del) but not in her mother. The missense mutation (1802C>A) was not found in her parents. It was accepted that frameshift mutations could cause a marked change in protein sequences. Moreover, we found a stop codon shortly after the mutation c.954G del resulting in the *ITGB2* protein synthesis to be terminated prematurely. Thus, the mutation c.954G del was considered as the major pathogenic mutation in this gene. As for mutation c.1802C>A, when compared with the NCBI database, we found that p.601C was highly conserved in different species, and PolyPhen-2 software

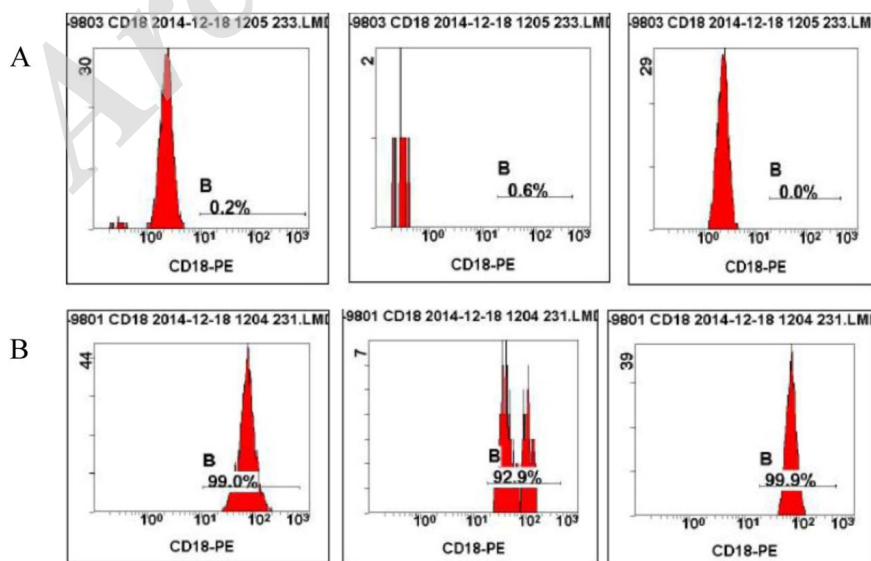


Figure 2. Expressions of CD18 on the Surface of Leukocytes. A) The expressions of CD18 on the surface of leukocytes, lymphocytes and neutrophils in the patient. B) The expressions of CD18 on the surface of leukocytes, lymphocytes and neutrophils in a healthy control.

predicted that the protein structure changes caused by this point mutation (c.1802C>A) were damaging (shown in Figure 3).

Expression Assay for the Mutant Protein

To further investigate the expression stability of the mutant protein, we generated a final *ITGB2* expression vector: pCMV6-entry-ITGB2. Missense mutation (*ITGB2* p.601C>F) was introduced into pCMV6-entry-ITGB2 and transfected into Lenti-x 293 T cells. With Western blotting analysis, there was no significant difference in the amount of protein expression between

293 T cells with mutant *ITGB2* p.601C>F and 293 T cells with wild type *ITGB2* (shown in Figure 4).

Cellular Localization of WT and Mutant ITGB2 in HeLa Cells

We further investigated the cellular location of WT and mutant *ITGB2* in HeLa cells. Compared with HeLa cells expressing wild type *ITGB2*, mutant *ITGB2* (p.601C>F) protein was only expressed in the cytoplasm and could not locate to the membrane of HeLa cell (Figure 5). This indicated that mutant *ITGB2* protein could not function at the cell membrane.

Discussion

LAD1 is the most common leukocyte adhesion deficiency and is caused by mutation in the $\beta 2$ integrin gene (*ITGB2*). Up to now, over 60 different mutations in the *ITGB2* gene have been identified.^{2,11,12} In the present study, we reported a female child with moderate LAD1 and 2 novel mutations in the *ITGB2* gene of this patient: a frameshift deletion viz c.954G del, which was considered as the major pathogenic gene for the patient, and a missense mutation viz c.1802C>A (Cys601Phe), which caused a damaging effect on *ITGB2* protein. Clinically, LAD-1 cases were subdivided into severe and moderate. In the severe form of the disease (less than 1% expression of CD18), the prognosis was very poor without hematopoietic stem cell transplantation. The clinical presentation of the patient in the present study could be categorized as a moderate form of LAD-1. It was found that the severity of the symptoms and survival directly associated with the amount of $\beta 2$ integrins expressed on the cell surface of leukocytes.^{13,14}

The integrins are a family of type I trans-membrane glycoproteins composed of α and β subunits which mediate cellular adhesive interactions throughout the body. The $\beta 2$ integrins are four heterodimeric proteins composed of one α subunit coupled to a common $\beta 2$ subunit.^{15,16} Decreased expression of the common $\beta 2$ subunit could lead to a decrease in expression of $\beta 2$ integrins on the leukocyte surface. The $\beta 2$ integrins could mediate adhesion of leukocytes to other cells and to extracellular matrix proteins and increase binding of intracellular target proteins and downstream signal transduction to cell proliferation and higher affinity for their ligands.^{17,18}

In clinical cases, the $\beta 2$ integrin gene (*ITGB2*) mutation was mainly in exons 5 to 9 which encoded the βA (I) domain. This domain was highly conserved in all β integrin subunits and contributed to the ligand binding pocket. Moreover, this domain was found to be involved in the biosynthesis of integrin precursors.¹⁹ Any significant alterations in the amino acid sequence in this

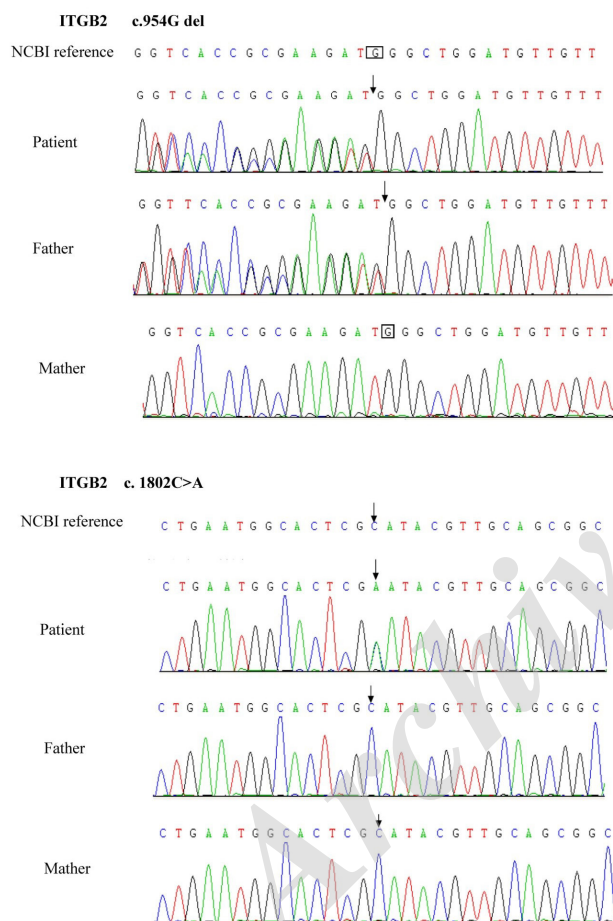


Figure 3. The Sequence of the 2 Novel Mutation in *ITGB2*.

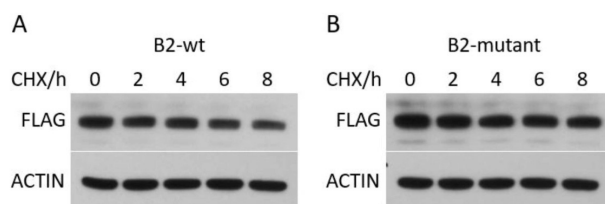


Figure 4. The Protein Expression of Mutant *ITGB2* p.601C>F. There was no significant difference in the amount of protein expression between 293 T cells with mutant *ITGB2* p.601C>F and 293 T cells with wild type *ITGB2* ($P > 0.05$).

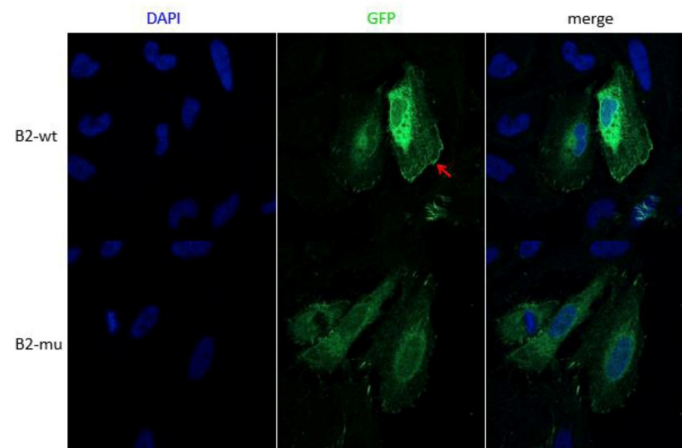


Figure 5. Cellular Location of WT and Mutant ITGB2 in HeLa Cells. Compared to HeLa cells with wild type ITGB2, mutant ITGB2 (p.601C>F) protein only expressed in cytoplasm and could not locate to HeLa cell membrane.

region might have a deleterious effect on the expression and functional activity of CD18 antigen.⁴

We considered that the first change, which led to a frameshift deletion viz c.954G del and a premature termination of the protein, could be responsible for the LAD phenotype in the patient. The functional analysis performed with blood cells of the patients supported the diagnosis of LAD-1. The effect of the missense mutation (Cys601Phe) on $\beta 2$ integrin function was evaluated using online prediction tools including PolyPhen-2. PolyPhen-2 predicted that this missense mutation affected $\beta 2$ integrin function. CD18 regions were found to have high degree of conservation and these regions were critical for heterodimer formation.²⁰ Mutations within the rigid cysteine-rich region might impair heterodimer formation.²¹ To demonstrate that the mutated *ITGB2* gene was the causative agent of LAD-1 in our patients, we cloned the coding sequence for expression in Lenti-x 293 cells and found that there was no significant difference in the amount of protein expression between 293 T cells with mutant *ITGB2* p.601C>F and 293 T cells with wild type *ITGB2*. However, when investigating the cellular location of the mutant ITGB2 in HeLa cells, we found mutant ITGB2 (p.601C>F) protein could not locate to the HeLa cell membrane. This indicated that the mutant ITGB2 protein could not play its function at the cell membrane.

Moreover, the patient had severe periodontitis with generalized gingival inflammation and severe periodontal bone loss on admission, which is one of the clinical characteristics of LAD1. A recent report showed that LAD1-associated oral disease was actually a microbe-induced hyperinflammatory response.²² In humans, LAD1 periodontitis was refractory to conventional therapy and could result in loss of teeth and surrounding alveolar bone. Moutsopoulos et al recently demonstrated that the interleukin-23 pathway was profoundly

dysregulated in the absence of tissue neutrophils.²³ Interleukin-23 response induced by the local bacteria at oral mucosa could be dysregulated and excessive in the absence of tissue neutrophils.^{22,24} They found that anti-interleukin-23 and anti-interleukin-17 could prevent periodontal inflammation and bone loss in lymphocyte function-associated antigen 1 (LFA1)-deficient mice.²⁵ The success of ustekinumab in the treatment of our patient's periodontitis and chronic sacral wound further supports this model.

In conclusion, we reported a moderate LAD1 patient and found 2 novel mutations in the *ITGB2* gene of this patient: a frameshift deletion viz c.954G del and a missense mutation viz c.1802C>A (Cys601Phe). The 2 mutations caused *ITGB2* protein changes and affected its function. Further investigations will focus on the specific mechanisms of the 2 mutations affecting the cellular location and function of the *ITGB2* protein.

Authors' Contribution

JH analyzed and interpreted the patient data and wrote the manuscript. QZ and HC diagnosed and treated the patient and recorded the medical history. YX and NN did and analyzed the ultrasound and laboratory examinations. YL was the corresponding author and participated in all the work. All authors read and approved the final manuscript.

Conflict of Interest Disclosures

The authors declare that they have no conflict of interest.

Ethical Statement

The experiments complied with the current laws of the country in which they were performed. This study was approved by the Institutional Animal Ethical Committee, Qingdao and Ethics Committee of the Affiliated Hospital of Qingdao University.

Acknowledgments

We appreciated Professor Herui Wang and all subjects in this study.

References

1. Picard C, Al-Herz W, Bousfiha A, Casanova JL, Chatila T, Conley ME, et al. Primary Immunodeficiency Diseases: an Update on the Classification from the International Union

- of Immunological Societies Expert Committee for Primary Immunodeficiency 2015. *J Clin Immunol.* 2015;35(8):696-726. doi: 10.1007/s10875-015-0201-1.
2. Teimourian S, De Boer M, Roos D, Isaian A, Moghanloo E, Lashkary S, et al. Mutation characterization and heterodimer analysis of patients with leukocyte adhesion deficiency: Including one novel mutation. *Immunol Lett.* 2017;187:7-13. doi: 10.1016/j.imlet.2017.04.012.
 3. Cabanillas D, Regairaz L, Deswarte C, Garcia M, Richard ME, Casanova JL, et al. Leukocyte adhesion deficiency type 1 (LAD1) with expressed but nonfunctional CD11/CD18. *J Clin Immunol.* 2016;36(7):627-30. doi: 10.1007/s10875-016-0322-1.
 4. Yassaee VR, Hashemi-Gorji F, Boosaliki S, Parvaneh N. Mutation spectra of the *ITGB2* gene in Iranian families with leukocyte adhesion deficiency type 1. *Hum Immunol.* 2016;77(2):191-5. doi: 10.1016/j.humimm.2015.11.019.
 5. Taghizade Mortezaee F, Esmaeli B, Badalzadeh M, Ghadami M, Fazlollahi MR, Alizade Z, et al. Investigation of *ITGB2* gene in 12 new cases of leukocyte adhesion deficiency-type I revealed four novel mutations from Iran. *Arch Iran Med.* 2015;18(11):760-4. doi: 0151811/aim.006.
 6. Levy-Mendelovich S, Rechavi E, Abuzaitoun O, Vernitsky H, Simon AJ, Lev A, et al. Highlighting the problematic reliance on CD18 for diagnosing leukocyte adhesion deficiency type 1. *Immunol Res.* 2016;64(2):476-82. doi: 10.1007/s12026-015-8706-5.
 7. Madkaikar M, Italia K, Gupta M, Desai M, Aggarwal A, Singh S, et al. Leukocyte adhesion deficiency-I with a novel intronic mutation presenting with pyoderma gangrenosum-like lesions. *J Clin Immunol.* 2015;35(4):431-4. doi: 10.1007/s10875-015-0155-3.
 8. Strickler A, Gallo S, King A, Rosenzweig SD. Leucocyte adhesion deficiency type 1 with developmental delay secondary to CMV infection and filiation questions. *BMJ Case Rep.* 2015;2015. doi: 10.1136/bcr-2014-208973.
 9. Yamazaki-Nakashimada M, Maravillas-Montero JL, Berron-Ruiz L, Lopez-Ortega O, Ramirez-Alejo N, Acevedo-Ochoa E, et al. Successful adjunctive immunoglobulin treatment in patients affected by leukocyte adhesion deficiency type 1 (LAD-1). *Immunol Res.* 2015;61(3):260-8. doi: 10.1007/s12026-014-8619-8.
 10. Madkaikar M, Italia K, Gupta M, Chavan S, Mishra A, Rao M, et al. Molecular characterization of leukocyte adhesion deficiency-I in Indian patients: identification of 9 novel mutations. *Blood Cells Mol Dis.* 2015;54(3):217-23. doi: 10.1016/j.bcmd.2015.01.012.
 11. Tipu HN. Leukocyte adhesion deficiency type I: A rare primary immunodeficiency disorder. *Pediatr Allergy Immunol.* 2017;28(3):303-5. doi: 10.1111/pai.12696.
 12. Herbin O, Regelmann AG, Ramkhelawon B, Weinstein EG, Moore KJ, Alexandropoulos K. Monocyte adhesion and plaque recruitment during atherosclerosis development is regulated by the adapter protein Chat-H/SHEP1. *Arterioscler Thromb Vasc Biol.* 2016;36(9):1791-801. doi: 10.1161/atvbaha.116.308014.
 13. Leon-Rico D, Aldea M, Sanchez-Baltasar R, Mesa-Nunez C, Record J, Burns SO, et al. Lentiviral vector-mediated correction of a mouse model of leukocyte adhesion deficiency type I. *Hum Gene Ther.* 2016;27(9):668-78. doi: 10.1089/hum.2016.016.
 14. Deshpande P, Kathirvel K, Alex AA, Korula A, George B, Shaji RV, et al. Leukocyte adhesion deficiency-i: clinical and molecular characterization in an indian population. *Indian J Pediatr.* 2016;83(8):799-804. doi: 10.1007/s12098-016-2051-0.
 15. Wolf D, Bukosza N, Engel D, Poggi M, Jehle F, Anto Michel N, et al. Inflammation, but not recruitment, of adipose tissue macrophages requires signalling through Mac-1 (CD11b/CD18) in diet-induced obesity (DIO). *Thromb Haemost.* 2017;117(2):325-38. doi: 10.1160/th16-07-0553.
 16. Dang TS, Willet JD, Griffin HR, Morgan NV, O'Boyle G, Arkwright PD, et al. Defective leukocyte adhesion and chemotaxis contributes to combined immunodeficiency in humans with autosomal recessive MST1 deficiency. *J Clin Immunol.* 2016;36(2):117-22. doi: 10.1007/s10875-016-0232-2.
 17. Levy-Mendelovich S, Rechavi E, Abuzaitoun O, Vernitsky H, Simon AJ, Lev A, et al. Highlighting the problematic reliance on CD18 for diagnosing leukocyte adhesion deficiency type 1. *Immunol Res.* 2016;64(2):476-82. doi: 10.1007/s12026-015-8706-5.
 18. Klapproth S, Sperandio M, Pinheiro EM, Prunster M, Soehnlein O, Gertler FB, et al. Loss of the Rap1 effector RIAM results in leukocyte adhesion deficiency due to impaired beta2 integrin function in mice. *Blood.* 2015;126(25):2704-12. doi: 10.1182/blood-2015-05-647453.
 19. Motomura Y, Kanno S, Asano K, Tanaka M, Hasegawa Y, Katagiri H, et al. Identification of Pathogenic Cardiac CD11c+ Macrophages in Nod1-Mediated Acute Coronary Arteritis. *Arterioscler Thromb Vasc Biol.* 2015;35(6):1423-33. doi: 10.1161/atvbaha.114.304846.
 20. Simon AJ, Lev A, Wolach B, Gavrieli R, Amariglio N, Rosenthal E, et al. The effect of gentamicin-induced readthrough on a novel premature termination codon of CD18 leukocyte adhesion deficiency patients. *PLoS One.* 2010;5(11):e13659. doi: 10.1371/journal.pone.0013659.
 21. Hixson P, Smith CW, Shurin SB, Tosi MF. Unique CD18 mutations involving a deletion in the extracellular stalk region and a major truncation of the cytoplasmic domain in a patient with leukocyte adhesion deficiency type 1. *Blood.* 2004;103(3):1105-13. doi: 10.1182/blood-2003-08-2780.
 22. Hajishengallis G, Moutsopoulos NM. Role of bacteria in leukocyte adhesion deficiency-associated periodontitis. *Microb Pathog.* 2016;94:21-6. doi: 10.1016/j.micpath.2015.09.003.
 23. Moutsopoulos NM, Zerbe CS, Wild T, Dutzan N, Brenchley L, DiPasquale G, et al. Interleukin-12 and interleukin-23 blockade in leukocyte adhesion deficiency type 1. *N Engl J Med.* 2017;376(12):1141-6. doi: 10.1056/NEJMoa1612197.
 24. Stark MA, Huo Y, Burcin TL, Morris MA, Olson TS, Ley K. Phagocytosis of apoptotic neutrophils regulates granulopoiesis via IL-23 and IL-17. *Immunity.* 2005;22(3):285-94. doi: 10.1016/j.immuni.2005.01.011.
 25. Moutsopoulos NM, Konkell J, Sarmadi M, Eskin MA, Wild T, Dutzan N, et al. Defective neutrophil recruitment in leukocyte adhesion deficiency type I disease causes local IL-17-driven inflammatory bone loss. *Sci Transl Med.* 2014;6(229):229ra40. doi: 10.1126/scitranslmed.300769