

Original Article

Complications of Fusionless Correction of Early Onset Scoliosis Using Dual Growing Rods

Farshad Nikouei, MD¹; Hasan Ghandhari, MD¹; Ebrahim Ameri, MD¹; Seyed Mani Mahdavi, MD²; Maryam Ameri, MD¹; Farshad Safdari, MSc³

¹Bone and Joint Reconstruction Research Center, Shafa Orthopedic Hospital, Iran University of Medical Sciences, Tehran, Iran

²Orthopedic Spine Surgery Department, Rasoul-e-Akram Hospital, Iran University of Medical Sciences, Tehran, Iran

³Bone Joint and Related Tissue Research Center, Shahid Beheshti University of Medical Sciences, Tehran, Iran

Abstract

Background: Growing rods are increasingly used for treatment of early onset scoliosis (EOS) worldwide. Beside promising outcomes, some authors are concerned about high rates of complications. In the current clinical trial, complications of EOS surgery using dual growing rods were investigated.

Methods: Between June 2006 and February 2017, twenty-two consecutive patients with a coronal curve >45 degrees underwent serial surgical correction using dual growing rods at Shafa Orthopedic hospital, Tehran, I.R. Iran. The rods were secured using hooks or screws or both. The patients were followed for 5.2 ± 1.7 years on average. Wilcoxon test was utilized to compare the pre- and post-operative values. $P < 0.05$ was considered significant.

Results: The scoliotic and kyphotic curves decreased significantly from $52 \pm 24^\circ$ to $38 \pm 19^\circ$ and from $78 \pm 22^\circ$ to $60 \pm 17^\circ$, respectively ($P < 0.001$). Total rate of implant-related complications (IRCs) and surgical site complications (SSCs) were 54.5% (12 patients) and 22.7% (5 patients), respectively. Malpositioned pedicular screw was found in 2 patients.

Conclusion: EOS can be effectively corrected using dual growing rods, however, considerable rates of IRC are of concern (54.5%). It seems necessary to compare the efficacy and complication rate of newer devices with those of growing rods in future studies.

Keywords: Complication, Early onset scoliosis, Fusionless surgery, Growing rod, Young children

Cite this article as: Nikouei F, Ghandhari H, Ameri E, Mahdavi SM, Ameri M, Safdari F. Complications of fusionless correction of early onset scoliosis using dual growing rods. Arch Iran Med. 2018;21(12):595-599.

Received: September 23, 2017, Accepted: October 3, 2018, ePublished: December 1, 2018

Introduction

Early onset scoliosis (EOS) involves the growing spine in children before complete lung development.¹ Treatment of growing children with EOS is challenging. When nonoperative treatment is insufficient, spinal fusion is used for deformity correction. However, spinal fusion at this age has been shown to be inappropriate and can result in pulmonary function disorders and other undesirable outcomes.²⁻⁵ Therefore, fusionless instrumentation has been introduced for treatment of EOS which is increasingly used all over the world to prevent deformity progression and delay the ultimate surgical fusion until complete spine and lung growth.⁶ There are several techniques proposed to apply fusionless instrumentation in this patient population including a single growing rod, dual growing rods, hybrid growing rod with proximal rib anchors and distal spinal anchors, vertical expandable prosthetic titanium rib (VEBTR) implant and H3S2 (3 hooks, 2 screws) construct; each with its own advantages and disadvantages.⁶⁻¹³

Within these techniques, correction of EOS using double growing rods is a prevalent technique with promising outcomes. However, like any other invasive management, this technique is also associated with some disadvantages. Some authors investigated the complications following surgical management of EOS with double growing rods with

promising outcomes.¹⁴⁻²² However, more prospective and long-term studies are required to increase our knowledge about the function and complications of this treatment method and confirm the results of previous studies. In the current study, we aimed to investigate clinical outcomes of treating EOS using double growing rods with concentration on rate and type of complications.

Materials and Methods

Between June 2006 and February 2017, 31 consecutive patients with progressive EOS were treated with fusionless fixation using double growing rods. In all of the patients, treatment for EOS with growing rods was started at 10 years of age or earlier. Indication for surgery included previous failed nonoperative management, curve progression and coronal curves >45 degrees. Patients with pulmonary disorders, insufficient soft tissue coverage, history of other additional procedures, severe proximal kyphosis and mental retardation were excluded.

Based on the inclusion criteria, nine patients were excluded and the study was completed with 22 patients. All of the parents signed the informed consent and agreed with publication of the data.

Preoperatively, clinical and radiologic evaluations were performed. In clinical examination, the muscular force,

*Corresponding Author: Seyed Mani Mahdavi, MD; Rasoul-e-Akram Hospital, Niayesh St, Sattar khan St, Tehran, IR Iran. Tel: +982188444408; Email: dr.mahdavi.spine@gmail.com

abdominal reflexes and the presence of pelvic obliquity, shoulder asymmetry and hump were evaluated. In addition, echocardiography and ultrasound assessment of kidneys were performed. Based on Cobb's method, the magnitude of the coronal curve and thoracic kyphosis were measured on the posteroanterior and lateral spinal X-rays. MR imaging showed tethered cord and diastematomyelia in 2 patients which were treated before treating EOS with dual rods.

All of the patients were operated on by a single surgeon. The surgical technique we used was based on the technique described by Akbarnia et al.¹² A midline incision was made to expose the vertebrae. Four submuscular rods were used for each patient (2 proximally and 2 distally) and contoured appropriately. The rods were secured to the spinal column using hooks and pedicular screws. The number and location of the anchors were determined based on the location and curve type. The diameter of rods, screws and hooks were 3.5 or 4 mm, 4.5 mm and 5 mm, respectively. All of the implants were made of titanium. After the operation, patients wore a rigid thoracolumbosacral orthosis for the first 6 months. Soon after the first procedure, the sagittal and coronal curves were measured. Construct lengthening usually was performed in 6-month intervals.

Patients were followed for 5.2 ± 1.7 years on average (range: 4 to 9 years). At the final visit, the coronal curve and thoracic kyphosis were measured (Figures 1 and 2). Also, the frequency of complications included implant-related complications (IRCs) and surgical site complications (SSCs) were recorded. IRC included screw pull-out (propulsion from pedicle), screw cut-off (creation of crack or fracture in any site of screw), and screw migration and rod cut-off (creation of crack or fracture in any site of rod). Screw migration was considered when the screw was placed correctly at time of operation but moved after surgery.

Statistical analysis was performed using the SPSS statistical software version 15.0. The magnitude of curves was reported as mean \pm standard deviation (SD). Based on the results of the Kolmogorov-Smirnov test, some of the measurements did not have a normal distribution. Then, the preoperative and early post-operative curves and, also, preoperative and final measurements were compared using the Wilcoxon test. $P < 0.05$ was considered significant.

Results

There were 9 males and 13 females aged 6.4 ± 2 years (range: 3–10 years) at time of first surgery. The characteristics of the patients are presented in Table 1. There were three patients with hook pull out. Rod cut-off occurred in 4 patients. Further, screw cut-off and screw migration occurred in three and 2 patients, respectively. IRCs were found in 12 patients (54.5%). Moreover, 5 patients developed surgical wound dehiscence (22.7%). Screw malpositioning occurred in 2 patients. In one of these patients, the screw entered the intervertebral disk. However, malpositioning of the screw was not accounted as IRC in the current study.

Both the coronal curve and thoracic kyphosis decreased significantly early after the first operation and at the last visit compared to the preoperative measurements

Table 1. Characteristics of EOS Treated Patients With Growing Rods

Patient number	22
Age at 1st surgery (y)	6.4 ± 2 (3–10)
Gender	
Male	9
Female	13
Patients with 2 scoliotic curves	2
Side of deformity	
Right	11
Left	13
Type of scoliosis	
Congenital	8
Infantile idiopathic scoliosis	6
Juvenile idiopathic scoliosis	5
Neuromuscular	3

($P < 0.001$) (Table 2).

Discussion

The most important finding of the current study was that treatment of EOS using dual growing rods is a useful method to prevent progression of deformity and to correct it until complete spinal growth. However, the technique is associated with high risk of complications especially IRC. When a patient with EOS is encountered, a spinal surgeon aims to prevent the progressive spinal and chest wall deformity while lung growth and function are preserved.¹⁰ Problems after fusion of EOS in the growing spine (disturbed pulmonary function and decreased quality of life) encouraged the authors to find and use alternative treatment methods. For example, in a retrospective cohort of patients with congenital scoliosis treated with early spinal fusion, Vitale et al found that after 6.9 years, these patients had

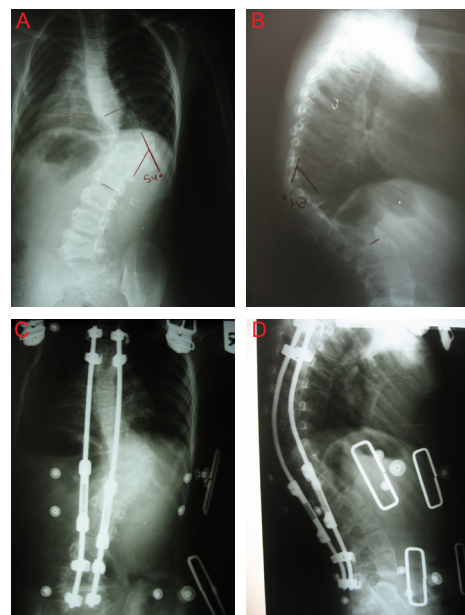


Figure 1. A 7-Year Old Patient With Early Onset Scoliosis Treated Using Dual Growing Rods. (A & B) Preoperative posteroanterior and lateral x-rays; (C & D) Posteroanterior and lateral x-rays taken 3 years after the first procedure with no complication.

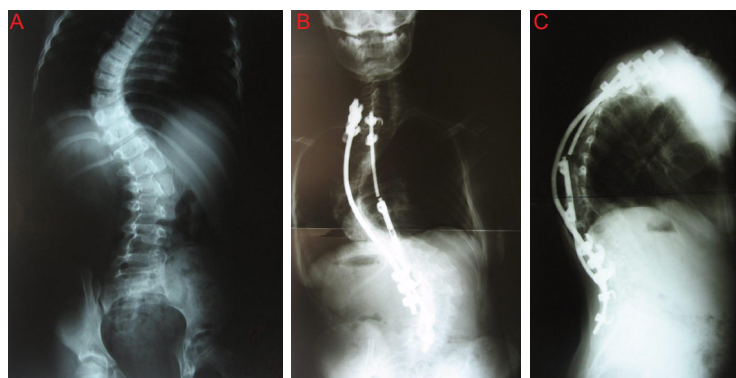


Figure 2. A 7-Year Old Patient With Early Onset Scoliosis Treated Using Dual Growing Rods. (A) Preoperative posteroanterior x-ray; (B & C) Posteroanterior and lateral x-rays taken 1.5 years after the first procedure showing a rod pulled out.

worse pulmonary function tests and quality of life compared to healthy peers. They suggested alternative methods such as growing rods.³ Also, Karol et al investigated pulmonary function in 28 patients who underwent early thoracic fusion for treatment of non-neuromuscular scoliosis. They demonstrated that these patients, especially those with more than 4 segment fusion, are at the highest risk for development of restrictive pulmonary disease.⁴ Goldberg et al found that in situ fusion for congenital scoliosis surgery effectively prevent progression of scoliosis in the fusion area but is not appropriate for correction of the overall deformity which is increased with spinal growth thus requiring a more biologic approach.⁵

Fusionless instrumentation is performed with several techniques and hardware but usually bears high risk of complications such as implant failure, infection and unintended autofusion.^{10,13,17,19,23, 24} Between these techniques and instruments, growing rods (single or dual) are commonly used worldwide with promising outcomes.^{7,25-27} Recently, it has been shown that treatment with a growing rod can stimulate the growth of individual vertebral bodies within the area of instrumentation.²⁸ Also, Shah et al found positive effect of growing rods on the sagittal vertical axis. They demonstrated that this treatment can return the patient to a more neutral alignment.²⁹

However, the mechanics of the fusionless growing rods and required serial surgeries can increase the risk of complications. It has been reported that treatment with single a growing rod is associated with rod breakage and infection in 42% and 9% of the cases, respectively.³⁰ With regard to the limitations and drawbacks of single growing rod, Akbarnia et al introduced the concept of correcting the deformity using dual growing rods in 2005. They treated 23 patients with EOS between 1993–2001 and found

that scoliosis deformity was corrected significantly after this treatment. Rate of complications was high (48%, 11 patients) consisting of implant failure in 22% and deep infection in 9%.¹²

After the innovation of the dual growing rod technique, several authors investigated the efficacy and complications of this technique and some compared it with the single rod technique. In a preliminary study, Thompson et al compared the results of a single submuscular rod and apical fusion, single growing rod and dual growing rods and found that dual growing rods provide greater initial correction and maintenance because they are stronger. However, the rate of complications was lower in the single growing rod technique.³¹ Zhao et al compared the results of the single growing rod and the dual growing rods and found no significant difference with regard to operating time, intraoperative bleeding and rate of complications. However, like the findings of Thompson et al., correction of the coronal curve was significantly greater in patients treated with dual growing rods.¹¹ In a study by Caniklioglu et al, IRCs occurred in 66% and 12.5% of patients treated with single and dual rods, respectively. Furthermore, medical complications were found in 22.2% and 12.5%, respectively.²⁷ Bess et al found a complication rate of 10% in the double rod technique compared with 27% in the single rod technique.¹⁵ Akgül et al. reported better deformity correction and stability with acceptable rate of complications.³² Finally, in a recent meta-analysis, Xu et al demonstrated that dual rods are associated with higher rate of coronal correction and lengthening, fewer rate of IRC and higher rate of SSC.³³ These findings strongly encourage using dual growing rods which can be associated with more correction and lower rate of complications compared to the single rod technique.

Table 2. Comparing the Preoperative, Early Postoperative and Postoperative Coronal Curves and Thoracic Kyphosis

	Preoperative	Early Postoperative	P Value ^a	Postoperative	P Value ^b
Coronal curve (degree)	78 ± 22	52 ± 16	< 0.001	60 ± 17	< 0.001
Thoracic kyphosis (degree)	52 ± 24	34 ± 18	< 0.001	38 ± 19	< 0.001

^a Comparison of preoperative and early postoperative measures.

^b Comparison of preoperative and postoperative measures.

Like previous studies, rate of IRC was high in our patients (54.5%). In addition, medical complications developed in 5 patients (22.7%). Although the rate of curve correction was acceptable according to the duration of the study, but the high rate of complications and number of unplanned surgeries are concerning. High rate of complications in treatment of EOS is a consequence of long-lasting treatment and the frequency of required surgical procedures.¹⁵

These results indicate the necessity of improving the mechanism or structure of the growing rods or emphasizes the necessity of finding more appropriate treatment techniques and strategies. In a review of complications due to growth-sparing surgery for treatment of EOS, Akbarnia and Evans demonstrated that none of the available techniques completely controls the deformity over the growth period.¹⁴ However, there are new devices introduced for fusionless correction of EOS which were associated with some promising outcomes. For example, Sankar et al showed that the rate of complications in treatment of EOS with hybrid growing rods is substantially less than dual growing rods (2.3 vs. 0.86 per patient).¹⁹ In another study, recently Choi et al used magnetically controlled growing rods and stated that the new device was efficient in reducing the rate of infection while there was no difference in term of hard-ware failure.³⁴ Like other studies, there were some limitations in the current study. The number of patients were small and there was no control group. Furthermore, long-term follow-up is required.

In conclusion, fusionless correction of EOS using dual growing rods results in satisfactory outcomes, however, the high rate of IRC was of concern (54.5%). It seems necessary to investigate the efficacy and complications of newer devices which may decrease the rate of complications in comparison to growing rods in future studies.

Authors' Contribution

Study conception and design: FN and HG. Acquisition of data: FN, HG, EA, SMM. Data analysis: MA and FS. Data interpretation: FN, HG, EA, SMM. Drafting the manuscript: MA and FS. Critical revision of the manuscript: FN, HG, EA, SMM. Final approval: MA and FS.

Conflict of Interest Disclosures

The authors have no conflicts of interest.

Ethical Statement

The Research Ethics Board (REB) of the Bone and Joint Reconstruction Research Center, Iran University of Medical Sciences approved the study.

References

1. Teli M, Grava G, Solomon V, Andreoletti G, Grismondi E, Meswania J. Measurement of forces generated during distraction of growing-rods in early onset scoliosis. *World J Orthop.* 2012;3(2):15-9. doi: 10.5312/wjo.v3.i2.15.
2. Campbell RM, Jr., Smith MD, Mayes TC, Mangos JA, Willey-Courand DB, Kose N, et al. The characteristics of thoracic insufficiency syndrome associated with fused ribs and congenital scoliosis. *J Bone Joint Surg Am.* 2003;85-a(3):399-408.
3. Vitale MG, Matsumoto H, Bye MR, Gomez JA, Booker WA, Hyman JE, et al. A retrospective cohort study of pulmonary function, radiographic measures, and quality of life in children with congenital scoliosis: an evaluation of patient outcomes after early spinal fusion. *Spine (Phila Pa 1976).* 2008;33(11):1242-9. doi: 10.1097/BRS.0b013e3181714536.
4. Karol LA, Johnston C, Mladenov K, Schochet P, Walters P, Browne RH. Pulmonary function following early thoracic fusion in non-neuromuscular scoliosis. *J Bone Joint Surg Am.* 2008;90(6):1272-81. doi: 10.2106/jbjs.g.00184.
5. Goldberg CJ, Moore DP, Fogarty EE, Dowling FE. Long-term results from in situ fusion for congenital vertebral deformity. *Spine (Phila Pa 1976).* 2002;27(6):619-28.
6. Thompson GH, Akbarnia BA, Campbell RM Jr. Growing rod techniques in early-onset scoliosis. *J Pediatr Orthop.* 2007;27(3):354-61. doi: 10.1097/BPO.0b013e3180333ee.
7. Sun ZJ, Qiu GX, Zhao Y, Guo SG, Zhang JG, Shen JX, et al. Dual growing rod treatment in early onset scoliosis: the effect of repeated lengthening surgeries on thoracic growth and dimensions. *Eur Spine J.* 2015;24(7):1434-40. doi: 10.1007/s00586-014-3668-1.
8. Campbell RM Jr, Smith MD, Mayes TC, Mangos JA, Willey-Courand DB, Kose N, et al. The effect of opening wedge thoracostomy on thoracic insufficiency syndrome associated with fused ribs and congenital scoliosis. *J Bone Joint Surg Am.* 2004;86-a(8):1659-74.
9. Yang JS, McElroy MJ, Akbarnia BA, Salari P, Oliveira D, Thompson GH, et al. Growing rods for spinal deformity: characterizing consensus and variation in current use. *J Pediatr Orthop.* 2010;30(3):264-70. doi: 10.1097/BPO.0b013e3181d40f94.
10. White KK, Song KM, Frost N, Daines BK. VEPTR growing rods for early-onset neuromuscular scoliosis: feasible and effective. *Clin Orthop Relat Res.* 2011;469(5):1335-41. doi: 10.1007/s11999-010-1749-y.
11. Zhao Y, Qiu GX, Wang YP, Zhang JG, Shen JX, Li SG, et al. Comparison of initial efficacy between single and dual growing rods in treatment of early onset scoliosis. *Chin Med J (Engl).* 2012;125(16):2862-6.
12. Akbarnia BA, Marks DS, Boachie-Adjei O, Thompson AG, Asher MA. Dual growing rod technique for the treatment of progressive early-onset scoliosis: a multicenter study. *Spine (Phila Pa 1976).* 2005;30(17 Suppl):S46-57.
13. Teli M, Lovi A, Brayda-Bruno M. Results of the spine-to-rib-cage distraction in the treatment of early onset scoliosis. *Indian J Orthop.* 2010;44(1):23-7. doi: 10.4103/0019-5413.58602.
14. Akbarnia BA, Emans JB. Complications of growth-sparing surgery in early onset scoliosis. *Spine (Phila Pa 1976).* 2010;35(25):2193-204. doi: 10.1097/BRS.0b013e3181f070b5.
15. Bess S, Akbarnia BA, Thompson GH, Sponseller PD, Shah SA, El Sebaie H, et al. Complications of growing-rod treatment for early-onset scoliosis: analysis of one hundred and forty patients. *J Bone Joint Surg Am.* 2010;92(15):2533-43. doi: 10.2106/jbjs.i.01471.
16. David M, Gardner A, Jennison T, Spilsbury J, Marks D. The impact of revision of one or more rods on refracture rate and implant survival following rod fracture in instrumentation without fusion constructs in the management of early-onset scoliosis. *J Pediatr Orthop B.* 2014;23(3):288-90. doi: 10.1097/bpb.0000000000000035.
17. Kabirian N, Akbarnia BA, Pawelek JB, Alam M, Mundis GM Jr, Acacio R, et al. Deep Surgical Site Infection Following 2344 Growing-Rod Procedures for Early-Onset Scoliosis: Risk Factors and Clinical Consequences. *J Bone Joint Surg Am.* 2014;96(15):e128. doi: 10.2106/jbjs.m.00618.
18. Gregg T, Lolli F, Di Silvestre M, Martikos K, Vommaro F, Maredi E, et al. Complications incidence in the treatment of early onset scoliosis with growing spinal implants. *Stud Health*

- Technol Inform. 2012;176:334-7.
19. Sankar WN, Acevedo DC, Skaggs DL. Comparison of complications among growing spinal implants. *Spine (Phila Pa 1976)*. 2010;35(23):2091-6. doi: 10.1097/BRS.0b013e3181c6edd7.
 20. Sankar WN, Skaggs DL, Emans JB, Marks DS, Dormans JP, Thompson GH, et al. Neurologic risk in growing rod spine surgery in early onset scoliosis: is neuromonitoring necessary for all cases? *Spine (Phila Pa 1976)*. 2009;34(18):1952-5. doi: 10.1097/BRS.0b013e3181afe869.
 21. Watanabe K, Uno K, Suzuki T, Kawakami N, Tsuji T, Yanagida H, et al. Risk Factors for Proximal Junctional Kyphosis Associated With Dual-rod Growing-rod Surgery for Early-onset Scoliosis. *Clin Spine Surg*. 2016;29(8):E428-33. doi: 10.1097/bsd.000000000000127.
 22. Watanabe K, Uno K, Suzuki T, Kawakami N, Tsuji T, Yanagida H, et al. Risk factors for complications associated with growing-rod surgery for early-onset scoliosis. *Spine (Phila Pa 1976)*. 2013;38(8):E464-8. doi: 10.1097/BRS.0b013e318288671a.
 23. Cahill PJ, Marvil S, Cuddihy L, Schutt C, Idema J, Clements DH, et al. Autofusion in the immature spine treated with growing rods. *Spine (Phila Pa 1976)*. 2010;35(22):E1199-203. doi: 10.1097/BRS.0b013e3181e21b50.
 24. Yang JS, Sponseller PD, Thompson GH, Akbarnia BA, Emans JB, Yazici M, et al. Growing rod fractures: risk factors and opportunities for prevention. *Spine (Phila Pa 1976)*. 2011;36(20):1639-44. doi: 10.1097/BRS.0b013e31822a982f.
 25. Wang S, Zhang J, Qiu G, Wang Y, Li S, Zhao Y, et al. Dual growing rods technique for congenital scoliosis: more than 2 years outcomes: preliminary results of a single center. *Spine (Phila Pa 1976)*. 2012;37(26):E1639-44. doi: 10.1097/BRS.0b013e318273d6bf.
 26. Kamaci S, Demirkiran G, Ismayilov V, Olgun ZD, Yazici M. The effect of dual growing rod instrumentation on the apical vertebral rotation in early-onset idiopathic scoliosis. *J Pediatr Orthop*. 2014;34(6):607-12. doi: 10.1097/bpo.000000000000169.
 27. Caniklioglu M, Gokce A, Ozturkmen Y, Gokay NS, Atici Y, Uzumcugil O. Clinical and radiological outcome of the growing rod technique in the management of scoliosis in young children. *Acta Orthop Traumatol Turc*. 2012;46(5):379-84.
 28. Olgun ZD, Ahmadiadli H, Alanay A, Yazici M. Vertebral body growth during growing rod instrumentation: growth preservation or stimulation? *J Pediatr Orthop*. 2012;32(2):184-9. doi: 10.1097/BPO.0b013e3182471915.
 29. Shah SA, Karatas AF, Dhawale AA, Dede O, Mundis GM, Jr., Holmes L Jr, et al. The effect of serial growing rod lengthening on the sagittal profile and pelvic parameters in early-onset scoliosis. *Spine (Phila Pa 1976)*. 2014;39(22):E1311-7. doi: 10.1097/brs.0000000000000565.
 30. Mineiro J, Weinstein SL. Subcutaneous rodding for progressive spinal curvatures: early results. *J Pediatr Orthop*. 2002;22(3):290-5.
 31. Thompson GH, Akbarnia BA, Kostial P, Poe-Kochert C, Armstrong DG, Roh J, et al. Comparison of single and dual growing rod techniques followed through definitive surgery: a preliminary study. *Spine (Phila Pa 1976)*. 2005;30(18):2039-44.
 32. Akgul T, Dikici F, Sar C, Talu U, Domanic U. Growing rod instrumentation in the treatment of early onset scoliosis. *Acta Orthop Belg*. 2014;80(4):457-63.
 33. Xu GJ, Fu X, Tian P, Ma JX, Ma XL. Comparison of single and dual growing rods in the treatment of early onset scoliosis: a meta-analysis. *J Orthop Surg Res*. 2016;11(1):80. doi: 10.1186/s13018-016-0413-y.
 34. Choi E, Yaszay B, Mundis G, Hosseini P, Pawelek J, Alanay A, et al. Implant Complications After Magnetically Controlled Growing Rods for Early Onset Scoliosis: A Multicenter Retrospective Review. *J Pediatr Orthop*. 2017;37(8):e588-e92. doi: 10.1097/bpo.0000000000000803.