

## Case Report

# Multiple Gastritis Cystica Profunda in a Patient without Gastric Surgery History

Enis Dikicier, MD<sup>1</sup>; Fatih Altintoprak, MD<sup>1</sup><sup>1</sup>Department of General Surgery, İstinye University Faculty of Medicine, Istanbul, Turkey**Abstract**

Gastritis cystica profunda (GCP) is a rare condition characterized by polypoid cystic ectasia of the submucosal layer with cystic dilatation of the glandular structures of the stomach. The probable pathogenesis refers to degradation of the integrity of the muscularis mucosa and migration of epithelial cells to the submucosal layer. The most common cause known in the literature for this occurrence is previous stomach surgery. A case presented with two GCP lesions in different locations in the stomach without any history of previous surgery.

**Keywords:** Gastritis cystica profunda, Robotic surgery

**Cite this article as:** Dikicier E, Altintoprak F. Multiple gastritis cystica profunda in a patient without gastric surgery history. Arch Iran Med. 2018;21(12):608–610.

Received: May 23, 2018, Accepted: October 20, 2018, ePublished: December 1, 2018

**Introduction**

Gastritis cystica profunda (GCP) is a rare condition characterized by polypoid cystic ectasia of the submucosal layer with cystic dilatation of the glandular structures of the stomach.<sup>1</sup> This condition is commonly asymptomatic but nonspecific symptoms like abdominal pain, nausea and vomiting may occasionally occur.<sup>2</sup> It may rarely present with gastrointestinal bleeding or obstruction in the gastric outlet.<sup>3</sup> It is assumed that GCP lesions occur after gastric surgery due to epithelial destruction and migration through the submucosal area, but cases without previous gastric surgery do exist in the literature.<sup>4</sup> We present a case with two GCP lesions in different locations of the stomach without any history of previous surgery. The treatment of choice for these lesions was robotic surgery in this patient.

**Case Report**

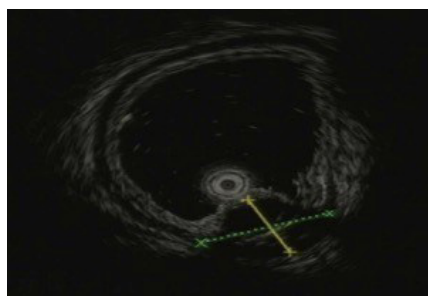
A 29 year-old male patient presented with nausea, vomiting and epigastric pain which gradually increased for 3 months. Physical examination was normal and the patient had no previous gastrointestinal surgery. The mucosal appearance of the whole stomach was regular and normal, but an outer mass effect of 4 × 5 cm in size at the gastric cardia and 2 × 2 cm lesions which were evaluated as submucosal masses at the gastric antrum were noted during an upper gastrointestinal endoscopic examination. Endoscopic ultrasound imaging revealed a 2 × 2 cm anechoic submucosal cystic lesion at the antrum and a 4 × 5 cm retrogastric cystic lesion with an irregular mural thickening which appeared associated with the gastric wall at the cardia (Figure 1). Abdominal computerized tomography imaging showed a 4 × 5 cm submucosal cystic lesion located on the larger curvature of the gastric cardia and a 2 × 2 cm similar lesion at the

posterior part of the stomach (Figure 2).

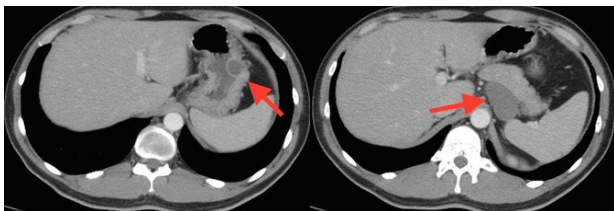
Robotic surgery was the procedure of choice for this patient. The 2 × 2 cm lesion located on the larger curvature, near the antrum at the anterior mural part of the stomach, was explored first (Figure 3A), and then the gastro-colic ligament was opened to explore the posterior part of the stomach. The lesion at the posterior part was explored as attached to the gastric wall at the esophago-gastric junction level. This lesion, located posterior to the stomach, was excised totally with the serosal part of the stomach (Figure 3B). The former lesion at the anterior part was excised by a wedge resection. No post-operative complications emerged and the patient was discharged on the fifth post-operative day with no additional problems. Histopathologic examination of the lesions revealed dilated cystic glands within mucosal and submucosal layers compatible with the diagnosis of benign GCP (Figures 4 and 5).

**Discussion**

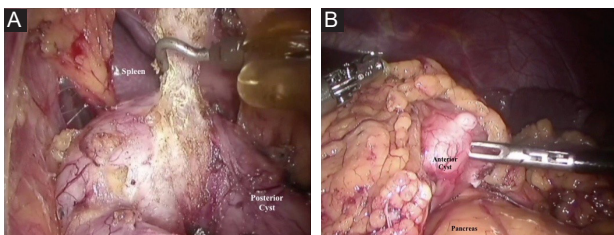
GCP is defined as multiple cystic gastric glands within the



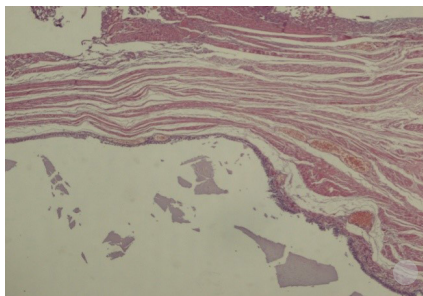
**Figure 1.** Endoscopic Ultrasound (EUS) Visualized 2 × 2 cm Anechoic Submucosal Cystic Lesion at the Antrum.



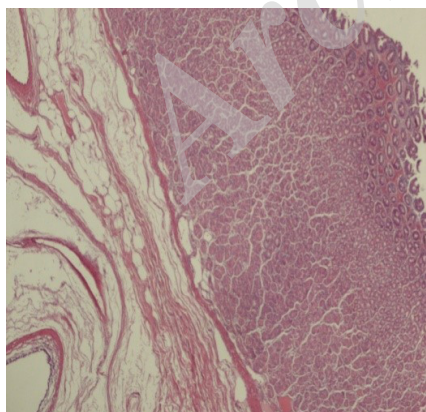
**Figure 2.** Abdominal Computerized Tomography Imaging; 4 x 5 cm submucosal cystic lesion located on the larger curvature at cardia and a 2 x 2 cm similar lesion at posterior part of the stomach (arrows).



**Figure 3.** Exploration of (A) Lesion in Front of the Stomach and (B) Retrogastric Lesion.



**Figure 4.** Hematoxylin and Eosin Staining of Lesion Specimens Showed Dilated Cystic Glands, H&E, 4x.



**Figure 5.** Histopathological Appearance of the Retrogastric Lesion, H&E, 4x.

submucosa of the stomach. The probable pathogenesis refers to degradation of the integrity of the muscularis mucosa and the emigration of epithelial cells to the submucosal layer. The theory explaining the pathogenesis is that previous

gastric surgery leads to mucosal defects or mucosal ischemia and inflammation which in turn causes mucosal prolapse and herniation of gastric gland cells to the submucosal layer forming cystic dilatation.<sup>5</sup> Also mucosal erosions due to diffuse chronic gastritis and *Helicobacter pylori* infection are suggested as important factors for GCP to occur, which may be an explanation for the cases without history of previous gastric surgery.<sup>6</sup> Our patient had no previous gastric surgery or specific etiological factors. To the best of our knowledge, there is no other case like this patient with two lesions which were confirmed as GCP histopathologically.

GCP is a benign disorder, but some cases associated with malignancy are also present in the literature.<sup>7,8</sup> Recurring mucosal erosions inducing regeneration and proliferation may lead to precancerous transformation.<sup>9</sup> Ki-67, p53 and p21 mutations have been detected in deep layer biopsy materials of some GCP lesions when compared with normal gastric mucosa.<sup>10</sup> No dysplasia was detected in both of the lesions from our case according to histopathologic evaluation.

Surgical resection and medical interventions to reduce bile reflux for treatment of GCP is recommended.<sup>11</sup> Surgical procedure varies between endoscopic resection or total gastrectomy depending on the lesion size and localization.<sup>12,13</sup> The proximal lesion was growing outwards so only the excision of the lesion was performed, and wedge resection was the procedure for the second and rather small lesion in our case. Recurrence after surgical excision has been identified in some patients, that's why a long follow-up period is recommended.<sup>11,13</sup> Since previous gastric surgery is an etiologic factor, the cases who had been treated with surgical excision must be put on long follow-up watch for risk of recurrence.

Finally, GCP is a rare cystic lesion of the stomach and surgical excision is recommended for treatment. Our case is a rare instance with 2 simultaneous lesions in different locations. This patient was treated by robotic surgery.

#### Authors' Contribution

Concept: ED. Design: FA. Supervision: FA. Materials: FA, ED. Data collection and/or processing: ED. Analysis and/or interpretation: FA, ED. Literature search: FA, ED. Writing: ED. Critical reviews: ED, FA.

#### Conflict of Interest Disclosures

The authors have no conflicts of interest.

#### Informed Consent

Informed consent was obtained from the patient who participated in this study.

#### Financial Disclosure

The authors declared that this study received no financial support.

#### Acknowledgments

We thank the patient for his cooperation.

#### References

1. Littler ER, Gleibermann E. Gastritis cystica polyposa. (Gastric mucosal prolapse at gastroenterostomy site, with cystic and infiltrative epithelial hyperplasia). *Cancer*. 1972;29(1):205-9.
2. Ozturk A, Kaya C, Tahaoglu C. A rare stomach lesion: Gastritis

- cystica profunda. *Int J Case Reports Med.* 2014;2014:249718. doi: 10.5171/2014.249718.
3. Butt MO, Luck NH, Hassan SM, Abbas Z, Mubarak M. Gastritis profunda cystica presenting as gastric outlet obstruction and mimicking cancer: A case report. *J Transl Int Med.* 2015;3(1):35-7. doi: 10.4103/2224-4018.154296.
  4. Yu XF, Guo LW, Chen ST, Teng LS. Gastritis cystica profunda in a previously unoperated stomach: a case report. *World J Gastroenterol.* 2015;21(12):3759-62. doi: 10.3748/wjg.v21.i12.3759.
  5. Park WY, Lee SJ, Kim YK, Kim A, Park DY, Lee BE, et al. Occurrence of metachronous or synchronous lesions after endoscopic treatment of gastric epithelia dysplasia- impact of histologic features of background mucosa. *Pathol Res Pract.* 2018;214(1):95-9. doi: 10.1016/j.prp.2017.10.022.
  6. Xu G, Peng C, Li X, Zhang W, Lv Y, Ling T, et al. Endoscopic resection of gastritis cystica profunda: preliminary experience with 34 patients from a single center in China. *Gastrointest Endosc.* 2015;81(6):1493-8. doi: 10.1016/j.gie.2014.11.017.
  7. Alkimawi KA, Shuja A. A rare precursor of gastric tumor. *Gastroenterol Rep (Oxf).* 2014;2(4):320-2. doi: 10.1093/gastro/gou029.
  8. Kim L, Kim JM, Hur YS, Shin YW, Park IS, Choi SJ, et al. Extended gastritis cystica profunda associated with Epstein-Barr virus-positive dysplasia and carcinoma with lymphoid stroma. *Pathol Int.* 2012;62(5):351-5. doi: 10.1111/j.1440-1827.2012.02806.x.
  9. Mukaisho K, Miwa K, Kumagai H, Bamba M, Sugihara H, Hattori T. Gastric carcinogenesis by duodenal reflux through gut regenerative cell lineage. *Dig Dis Sci.* 2003;48(11):2153-8.
  10. Iwanaga T, Koyama H, Takahashi Y, Taniguchi H, Wada A. Diffuse submucosal cysts and carcinoma of the stomach. *Cancer.* 1975;36(2):606-14.
  11. Kim JH, Jang SY, Hwang JA, Ha SH, Choi WG, Park JS, et al. [A ten-year follow-up of a case with gastric adenoma accompanied with gastritis cystica profunda treated by endoscopic submucosal dissection]. *Korean J Gastroenterol.* 2012;59(5):366-71.
  12. Laratta JL, Buhtoiarova TN, Sparber LS, Chamberlain RS. Gastritis cystica profunda: a rare gastric tumor masquerading as a malignancy. *Surg Sci.* 2012;3(3):158-64. doi: 10.4236/ss.2012.33031.
  13. Wang L, Yan H, Cao DC, Huo L, Huo HZ, Wang B, et al. Gastritis cystica profunda recurrence after surgical resection: 2-year follow-up. *World J Surg Oncol.* 2014;12:133. doi: 10.1186/1477-7819-12-133.

Archive of SID