

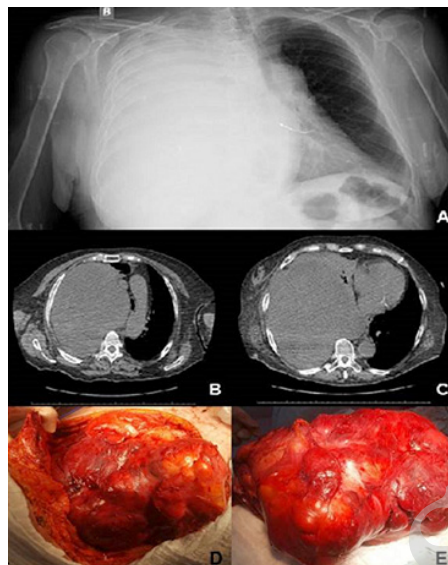
Photoclinic

Figure 1. (A) Plain Chest Radiography Showing Opaque Right Hemithorax and Mediastinal Deviation to the Left Side; (B and C) CT of Thorax Revealing a Huge Mass in the Right Hemithorax with Deviation of Mediastinal Structures; (D and E) Voluminous Lobulated Mass Excised From the Left Hemithorax.

A 75-year-old hypertensive woman using perindopril arginine (5 mg/d) came to the hospital with dyspnea on exertion, productive cough, and asthenia for 15 days. She denied alcoholism, smoking, illicit drug use or weight loss. On admission, there was pallor, tachypnea, dull note on percussion and absent breath sounds in the right hemithorax. The chest X-ray showed total opacity of the right hemithorax, as well as deviation of the mediastinum to the left side (Figure 1A). The computed tomography (CT) images revealed a voluminous homogeneous mass occupying the right hemithorax and causing contralateral deviation of mediastinum (Figure 1B-C). The patient was admitted to the intensive care due to marked respiratory discomfort, with

tachypnea (35 irpm), SpO₂ 99% with the Venturi mask (FiO₂ 50%) and underwent tracheostomy. Transthoracic biopsy of the mass was performed and the histopathological analysis showed irregularly arranged, fusiform cell bundles and focally sclerotic stroma; hyperchromasia and anisokaryosis; moderate atypia with up to 6 mitotic figures per 10 in high-power fields; and focal necrosis. The immunohistochemistry study showed AE1/AE3 negative; smooth muscle actin negative, CD31 negative; desmin negative; epithelial membrane antigen negative; ERG negative; S-100 protein negative; progesterone receptor negative; CD34 positive and nuclear pattern of STAT6 positive. An open surgical procedure was done unsuccessfully (Figure 1D-E).

**What is your diagnosis?
See the next page for your diagnosis.**

Received: April 7, 2018, Accepted: October, 27, 2018, ePublished: December 1, 2018

Vitorino Modesto dos Santos, MD, PhD¹; Evandro Luiz Brum, MD²; Layssa de Melo Feitosa, MD³; Kamila Fernandes Ferreira, MD³; Camila de Azevedo Silva, MD³

¹Internal Medicine Department, Armed Forces Hospital and Catholic University, Brasília-DF, Brazil. ²Thoracic Surgery Service, Armed Forces Hospital, Brasília-DF, Brazil. ³Internal Medicine Department, Armed Forces Hospital, Brasília-DF, Brazil.

***Corresponding Author:** Vitorino Modesto dos Santos, MD, PhD; Hospital das Forças Armadas. Estrada do Contorno do Bosque s/n, Cruzeiro Novo. CEP 70.658-900, Brasília-DF, Brasil. Phone: +55 61-39662103; Fax: +55 61-32331599. Email: vitorinomodesto@gmail.com

Cite this article as: Santos VM, Brum EL, Feitosa LM, Ferreira KF, Silva CA. Photoclinic. Arch Iran Med. 2018;21(12):613-615.

■ Photoclinic Diagnosis

Opaque hemithorax due to malignant fibrous tumor of thorax

Opaque hemithorax (OH) can be associated with shift of mediastinal structures either to affected or to the contralateral side in some cases evolving with compensatory hyperinflation of the normal lung and variable herniation across the midline.¹⁻⁸ This condition is not rare and may be due to voluminous pleural effusion, lung consolidation or collapse, massive tumor, fibrothorax, pneumectomy, or agenesis, aplasia, and hypoplasia of the lung.¹⁻⁸ Anamnesis, chest physical examination, bronchoscopy, ultrasound, X-ray and CT, are useful in differential diagnosis.¹⁻⁸ The OH may be evaluated by the volume of the affected hemithorax and mediastinal positions: (1) increased volume and mediastinal shift to the unaffected side; (2) reduced volume and mediastinal shift to the affected side; and (3) normal volume and absence of mediastinal shift.⁷ The most common causes of OH with increased volume are large pleural effusions or masses.⁷

This patient had opacification of the right hemithorax by a voluminous mass with progressive mediastinal shift to the left. Immunohistochemistry of biopsy samples revealed CD34 and STAT6 positivity, and the data set was consistent with malignant solitary fibrous tumor (SFT).⁹⁻¹⁵ Without improvement, she was treated by docetaxel (75 mg/m²) and radiotherapy. After the first cycle of chemotherapy, CT images showed further increase of the tumor (Figure 1C). Open surgery was done to reduce the compression,⁹ but in the postoperative period, she had hypotension and irreversible asystole despite resuscitation maneuvers.

The histologic pattern of pleural SFTs was first described in 1931, whereas the sub mesothelial mesenchymal origin was established by immunohistochemical methods in 1980s.¹¹ They are rare neoplasms of giant size at diagnosis, more often pleural (up to 80% visceral and 80% benign) and of soft tissues⁹: Immunohistochemistry is mandatory for diagnosis; CD34, CD99, Vimentin, and BCL-2 may be positive, but nuclear STAT6 is a specific marker of SFT.^{13,15} Gupta et al reviewed 28 cases of pleural SFTs (53.57% women and 64.28% benign); the mean age of patients was 58.1 ± 15.9 years for benign and 66.5 ± 11.8 years for malignant tumors and the diameter was 6.05 (3.2–10.9) cm for benign and 15.7 (7.1–17.5) cm for malignant ones.¹⁰ CT predictive data of malignancy are large in size, lobulated, with calcification, and pleural effusion.¹⁰⁻¹⁴ Hélage et al also found large tumor size as the most significant predictor of SFT malignancy in 56 patients,⁷ and this macroscopic feature is in accordance with findings of the present report. Worthy of note, approximately half of pleural SFTs evolve asymptotically; however, cough, chest pain, and dyspnea may be presented, especially in patients with voluminous masses.¹⁴ About 10% of pleural SFTs may be related to paraneoplastic syndromes, including hypertrophic

osteoarthritis, hypoglycemia, clubbed nail-beds, as well as gynecomastia or galactorrhea.^{14,15} Lee et al described a pleural SFT with recurrent episodes of hypoglycemia; and, as the present case, the tumor did not respond to non-surgical control, but the mass volume remained stable.¹² Clinical behavior of this rare malignancy and best control for large SFTs are not clear yet.

Authors' Contribution

All three authors participated in the conception and design, collection and interpretation of data, literature search, and writing and review of the manuscript.

Conflict of Interest Disclosures

The authors have no conflicts of interest.

Ethical Statement

In writing the manuscript, the authors followed the policy of the Committee on Publication Ethics (COPE).


Funding

There was no grant support for this study.

References

- Chawla RK, Madan A, Das K, Chawla A. Completely opaque hemithorax. *Lung India*. 2014;31(4):416-8. doi: 10.4103/0970-2113.142095.
- dos Santos VM, Pinto VL Jr, Paixao GT, de Faria KD. Photoclinic. Hypoplasia of the left lung and bronchial asthma. *Arch Iran Med*. 2011;14(6):423-4. doi: 011146/aim.0013.
- Girdhar A, Zaiden R. A 54-year-old man with right opaque hemithorax and worsening shortness of breath. *Respiration*. 2010;79(2):157-9. doi: 10.1159/000235973.
- Guleria R, Mohan A, Mukhopadhyay S. Opaque hemithorax in a young adult. *Postgrad Med J*. 1997;73(864):681-3.
- Kumar R, Poongadan MN, Singh M. Allergic bronchopulmonary aspergillosis presenting as lobar or total lung collapse. *Pneumonol Alergol Pol*. 2015;83(2):144-50. doi: 10.5603/PiAP.2015.0023.
- Kumar P, Tansir G, Sasmal G, Dixit J, Sahoo R. Left pulmonary agenesis with right lung bronchiectasis in an adult. *J Clin Diagn Res*. 2016;10(9):Od15-od7. doi: 10.7860/jcdr/2016/21623.8547.
- Marchiori E, Hochegger B, Zanetti G. Opaque hemithorax. *J Bras Pneumol*. 2017;43(3):161. doi: 10.1590/s1806-37562017000000024.
- Singh U, Jhim D, Kumar S, Mittal V, Singh N, Gour H, et al. Unilateral agenesis of the lung: a rare entity. *Am J Case Rep*. 2015;16:69-72. doi: 10.12659/ajcr.892385.
- Aydemir B, Celik S, Okay T, Dogusoy I. Intrathoracic giant solitary fibrous tumor. *Am J Case Rep*. 2013;14:91-3. doi: 10.12659/ajcr.883867.
- Gupta A, Souza CA, Sekhon HS, Gomes MM, Hare SS, Agarwal PP, et al. Solitary fibrous tumour of pleura: CT differentiation of benign and malignant types. *Clin Radiol*. 2017;72(9):796.e9-.e17. doi: 10.1016/j.crad.2017.03.028.
- Hélage S, Revel MP, Chabi ML, Audureau E, Ferretti G, Laurent F, et al. Solitary fibrous tumor of the pleura: Can computed tomography features help predict malignancy? A series of

- 56 patients with histopathological correlates. *Diagn Interv Imaging*. 2016;97(3):347-53. doi: 10.1016/j.diii.2015.04.013.
12. Lee CE, Zanariah H, Masni M, Pau KK. Solitary fibrous tumour of the pleura presenting with refractory non-insulin mediated hypoglycaemia (the Doege-Potter syndrome). *Med J Malaysia*. 2010;65(1):72-4.
 13. Tani E, Wejde J, Astrom K, Wingmo IL, Larsson O, Haglund F. FNA cytology of solitary fibrous tumors and the diagnostic value of STAT6 immunocytochemistry. *Cancer Cytopathol*. 2018;126(1):36-43. doi: 10.1002/cncy.21923.
 14. Yeom YK, Kim MY, Lee HJ, Kim SS. Solitary Fibrous Tumors of the Pleura of the Thorax: CT and FDG PET Characteristics in a Tertiary Referral Center. *Medicine (Baltimore)*. 2015;94(38):e1548. doi: 10.1097/md.0000000000001548.
 15. You X, Sun X, Yang C, Fang Y. CT diagnosis and differentiation of benign and malignant varieties of solitary fibrous tumor of the pleura. *Medicine (Baltimore)*. 2017;96(49):e9058. doi: 10.1097/md.0000000000009058.

 © 2018 The Author(s). This is an open-access article distributed under the terms of the Creative Commons Attribution License (<http://creativecommons.org/licenses/by/4.0>), which permits unrestricted use, distribution, and reproduction in any medium, provided the original work is properly cited.

Archive of SID