

Case Report

Electrocardiographic Changes Following Acute Hydralazine Overdose

Maryam Vahabzadeh, MD, PhD¹; Ali Eshraghi, MD²; Mina Akbari-Rad, MD³; Abdollah Firoozi, PharmD⁴; Alireza Esmaeili, MD⁵; Yaghoob Ahrari, MD⁶

¹Medical Toxicology Research Center, Faculty of Medicine, Mashhad University of Medical Sciences, Mashhad, Iran

²Cardiology Department of Imam Reza Hospital, Mashhad University of Medical Sciences, Mashhad, Iran

³Department of Internal Medicine, Ghaem Hospital, Mashhad University of Medical Sciences, Mashhad, Iran

⁴Mashhad University of Medical Sciences, Mashhad, Iran

⁵Department of Emergency Medicine, Shahid Sadoughi University of Medical Sciences, Yazd, Iran

⁶Faculty of Medicine, Mashhad University of Medical Sciences, Mashhad, Iran

Abstract

Hydralazine is an FDA-approved antihypertensive agent which has been utilized for years either alone or in combination with other medications especially the beta-blockers. Hydralazine works as a direct-acting vasodilator, thereby exerting a decrease in vascular resistance and increase in intravascular volume. When overdosed, hydralazine applies its toxic effects by extending its pharmacological action, which produces hypotension, syncope, tachycardia, and nausea. However, studies and case reports of acute hydralazine toxicity and its effects on electrocardiographic changes are rare, and most of the medical literature have only highlighted its immunological side effects. In this report, we are presenting a case of acute hydralazine overdose in a young woman who ended up in CCU due to remarkably abnormal electrocardiogram and unstable hemodynamics followed by myocardial infarction.

Keywords: Cardiotoxicity, Electrocardiogram, Hydralazine, Myocarditis, Myocardial Infarction

Cite this article as: Vahabzadeh M, Eshraghi A, Akbari-Rad M, Firoozi A, Esmaeili A, Ahrari Y. Electrocardiographic changes following acute hydralazine overdose. Arch Iran Med. 2019;22(1):53-56.

Received: May 25, 2018, Accepted: October 13, 2018, ePublished: January 1, 2019

Introduction

Hydralazine, an FDA-approved antihypertensive agent, has been utilized for years either alone or in combination with other medications especially beta-blockers. Hydralazine works as a direct-acting vasodilator thereby exerting a decrease in vascular resistance and an increase in intravascular volume.¹ In patients with severe congestive heart failure in whom the primary problem is low cardiac output, hydralazine can be prescribed to benefit from its noticeable effects on hemodynamics. Significant tachycardia and hypotension could be the side effects in occasional patients and those with congestive heart failure, respectively.²

Following oral use, hydralazine reaches its peak plasma level within 1-2 hours and has a half-life of 3-7 hours.³⁻⁵ Therapeutic doses are based on the disorder for which the medicine is prescribed. However, the maximum daily dose should not exceed 300 mg. In therapeutic doses, possible adverse immunologic reactions may occur ranging from vasculitis and hemolytic anemia to lupus-like syndrome. While overdosed, hydralazine applies its toxic effects as an extension of its pharmacological actions, producing hypotension, syncope, tachycardia, and nausea.⁵ However, reports pointing to acute toxicity of hydralazine and electrocardiographic changes are very rare, and most of the

medical literature has highlighted its immunological side effects. There were only two reports found of abnormal ECG due to hydralazine overdose in the literature which we could find. One of these reports had ethanol as the concomitant sedative agent⁶ and the other occurred due to hydralazine alone.⁷ Toxic doses between 750 and 2000 mg have been described in these case reports. In this report, we are representing a case of acute hydralazine overdose in a young woman who ended up in CCU due to remarkably abnormal electrocardiogram and unstable hemodynamics followed by myocardial infarction.

Case Report

A 38-year-old married woman who had history of hypertension and unknown heart disease was referred to Imam Reza educational hospital of Mashhad, Iran via Emergency Medical Services (EMS) approximately 2 hours after a suicide attempt with a combination of 10 mg clonazepam (10×1 mg tablets) and 750 mg of hydralazine (30 × 25 mg tablets). On arrival, the patient's vital signs were as follows: Blood Pressure: 70/55 mm Hg, pulse rate: 90/min, respiratory rate: 16/min, O₂Sat: 98%, axillary body temperature: 36.9 degrees centigrade. On physical examination, the patient was lethargic, the pupils were mid-

size and reactive to light, and mucosal membranes were normal. Other aspects of physical exam were unremarkable. Due to low blood pressure, 1000 mL of 0.9% sodium chloride (30 mL/min infusion rate) was intravenously infused under close monitoring followed by 50 mg of ranitidine, and 10 mg metoclopramide- both administered through the I.V. route. Gastric lavage was also performed to remove any possible residue of medication from the digestive system.

A set of laboratory tests (Table 1) and ECG (Figure 1) were performed for the patient, respectively. One hour after admission, the patient reported chest pain, therefore, the second and third ECG (Figures 2 and 3) and quantitative troponin I cardiac enzyme test was performed for her.

Due to the patient's chest pain, dynamic changes in the second and third ECG (Figures 2 and 3) and high serum levels of troponin, anti-ischemic regimen including oral ASA (300 mg), oral Clopidogrel (300 mg), heparin infusion (1000 U/h), TNG infusion (5–10 µg/min) and oral atorvastatin (40 mg) was started for her. The patient was then transferred to CCU with the diagnosis of non-ST elevation MI. Her echocardiography revealed an ejection fraction (EF): 50%–55%, mild mitral regurgitation (MR), with other abnormalities. Considering the above results, the patient

underwent coronary angiography via the radial artery that showed normal coronary arteries. After 36 hours, symptoms gradually improved and the patient was transferred to the cardiology ward. Two days later, the patient was discharged from the hospital with a favorable general condition without any cardiac symptoms and advised to follow her outpatient therapy with a medical toxicologist and a psychiatrist.

Discussion

Hydralazine is a direct peripheral vasodilating agent, which affects the cardiovascular system by an unknown mechanism of action. The peripheral vasodilating effect of hydralazine results in decreased arterial blood pressure (more potent on diastolic than systolic); decreased peripheral vascular resistance, and an increased heart rate and cardiac output. hydralazine increases renin activity, which leads to the production of angiotensin II and stimulation of aldosterone and consequent sodium reabsorption. Hydralazine also maintains or increases renal and cerebral blood flow. Common side effects include headache, anorexia, nausea, vomiting, diarrhea, palpitations, tachycardia and angina pectoris. There are also some less frequent side effects such as constipation, paralytic ileus, hypotension, paradoxical pressor response, edema, dyspnea, peripheral neuritis

Table 1. Laboratory Results at time of referral

CBC	VBG	Biochemistry	LFT	Coagulation tests	Misc.
WBC: $17.6 \times 10^9/L$	pH: 7.38	Urea: 28 mg/dL	AST: 23 U/L	PT: 12 sec	CPK: 326 U/L
RBC: $4.75 \times 10^{12}/L$	pCO ₂ : 29.1 torr	Cr: 1.4 mg/dL	ALT: 12 U/L	PTT: 24.6 sec	TPI: 10283
HB: 11.1 g/dL	pO ₂ : 29.9 torr	Na: 140 mEq/L	ALP: 121 U/L	INR: 1.85	
HCT: 36.7%	HCO ₃ : 16.9 mEq/L	K: 3.1 mEq/L			
MCH: 23.4 pg		Ca: 8.9 mg/dL			
MCV: 77.3 fL		Mg: 2.27 mg/dL			
PLT: $372 \times 10^9/L$		BS: 150 mg/dL			

CBC, Complete Blood Test; WBC, White Blood Cell; RBC Red Blood Cell; HB, Hemoglobin; HCT, Hematocrit; MCH, Mean Corpuscular Hemoglobin; MCV, Mean Corpuscular Volume; PLT, Platelet; VBG, Venus Blood Gas; Cr, Creatinine; Na, Sodium; K, Potassium; Ca, Calcium; Mg, Magnesium; BS, Blood Sugar; LFT, Liver Function Test; AST, Aspartate Aminotransferase; ALT, Alanine Aminotransferase; ALP, Alkaline Phosphatase; CPK, Creatine Phosphokinase; TPI, Troponine; PT, Prothrombin Time; PTT, Partial Thromboplastin Time; INR, International Normalized Ratio.

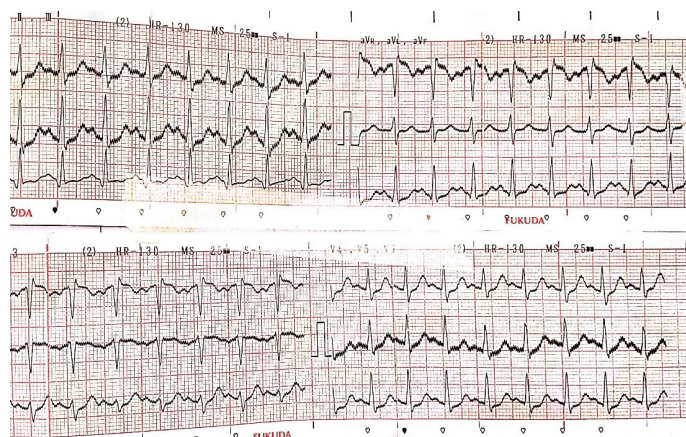


Figure 1. ECG on Admission: Sinus Tachycardia, Normal Axis, Poor R Progression in Precordial Leads, ST Depression in I-2 & V4-V6 & AVF, Normal QT Interval, Normal PR Interval.

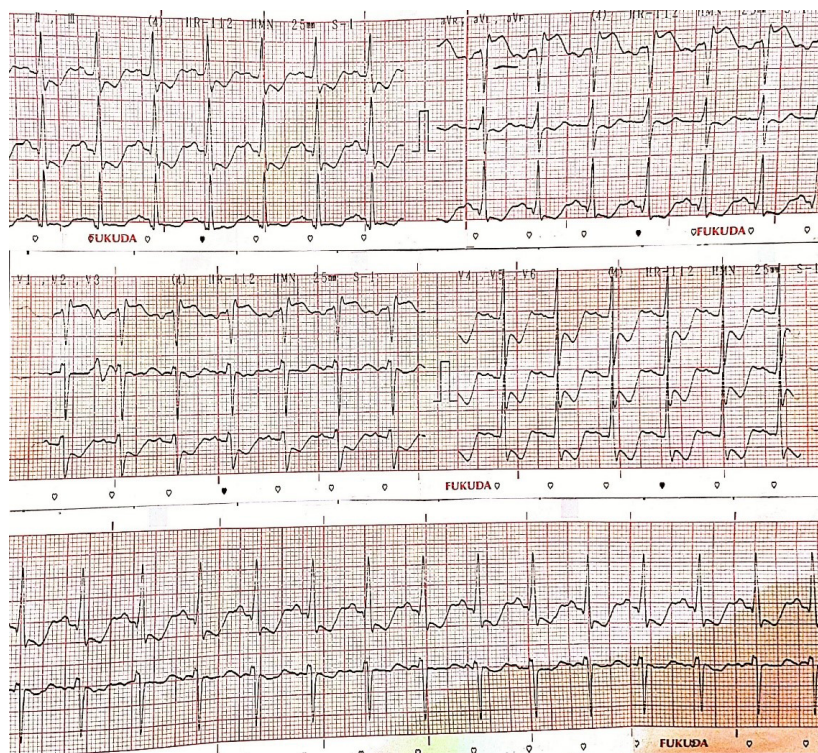


Figure 2. ECG 1 h After Admission at the Onset of Chest Pain: Sinus Tachycardia, Normal Axis, ST Depression in 1-2 & V3-V6 & AVF, Inverted T in 1-3 & AVL & AVF & V3-V6, ST Elevation in AVR (2 mm) & V1 (the de winter ECG pattern in V1-V3), Normal QT Interval, Normal PR Interval.

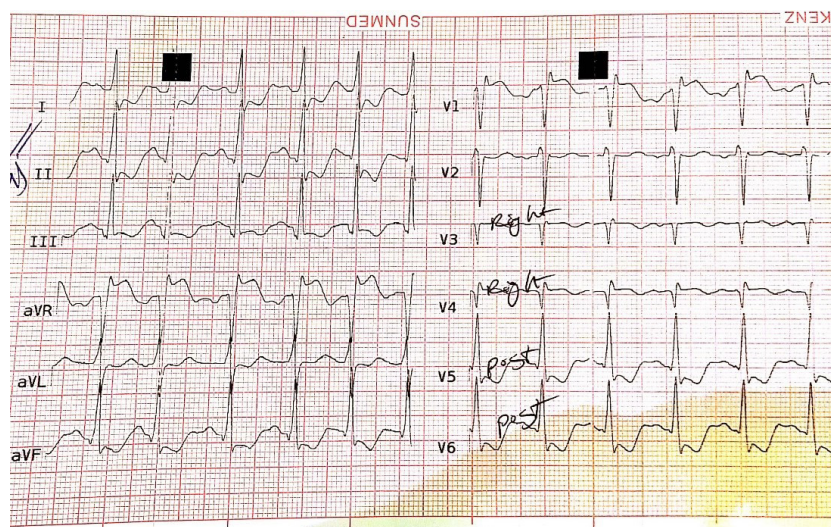


Figure 3. ECG 1 h after referral that was taken after chest pain, focused on Right and Posterior sides, showing ST depression in V7-V8 (posterior leads), ST-elevation up to 1 mm in v4.

evidenced by paresthesia, numbness, tingling, dizziness, tremors, and muscle cramps. Moreover, psychotic reactions characterized by depression, disorientation, anxiety, blood dyscrasias such as reduction in hemoglobin and red cell count have been reported. Hydralazine leads to myocardial stimulation, which can cause angina attacks and ECG changes representing myocardial ischemia.^{4,8}

In cases of overdose, no deaths related to acute hydralazine poisoning have been reported as its highest known dose survived in adults is reported as 10 g hydralazine orally.

The oral LD50 reported in rats is 173–187 mg/kg.^{4,5} The typical signs of overdose include hypotension, tachycardia, headache, and generalized skin flushing as well as myocardial ischemia and subsequent myocardial infarction, cardiac arrhythmia, and profound shock.

While hypokalemia is one of the main reasons for ECG changes, it occurs when potassium levels go below 3.0 mmol/L and mainly cause flattening and inversion of T waves.⁹ Although our patient had a notable inverted T, her potassium level was above 3.0 mmol/L, which rules out the

role of potassium as the primary cause of arrhythmias.

Temporary reduction of coronary artery perfusion pressure has been reported in patients with ischemic cardiomyopathy after taking oral doses of hydralazine. That can lead to myocardial ischemic episodes. Hydralazine toxicity can cause lactic acidosis due to hypotension and hypoperfusion. Following tissue hypoperfusion, there is an increase in NADH levels which favors lactate formation.¹⁰ This, along with toxicity related shock may account for ST depression, which was observed in both ECGs of our patient.¹¹ Moreover, since our patient had no coronary stenosis or abnormality in coronary angiography, we attributed these ECG changes to hydralazine effect itself.

While there is no specific antidote known for hydralazine, the first step to manage its overdoses is gastric lavage and activated charcoal slurry if patient's condition permits. These manipulations have to be carried out only after cardiovascular status has been stabilized since they might precipitate cardiac arrhythmias or increase the depth of shock. Support of the cardiovascular system is of primary importance. The shock should be treated with plasma expanders. If possible, vasopressors should not be given; but if a vasopressor is required, care should be taken not to precipitate or aggravate cardiac arrhythmia. Tachycardia responds to beta-blockers. Digitalization may be necessary, and renal function should be monitored and supported as required.^{4,5}

In conclusion, Intentional overdose with hydralazine should be dealt with seriously, particularly among those with underlying cardiac diseases.

Authors' Contribution

Nothing specific to mention, just follow the order of authors. Mina Akbari-Rad, MD is the corresponding author.

Conflict of Interest Disclosures

The authors have no conflicts of interest.

Ethical Statement

As this manuscript is a case report, and did not done anything against ethics, there was no need to ask for any ethical certification in this manner. We have just taken a written consent from the patient in order to publish the results regarded to her conditions..

References

1. Koch-Weser J. Medical intelligence drug therapy. *N Engl J Med*. 1976;295(6):320-3. doi:10.1056/nejm197608052950606.
2. Chatterjee K, Parmley WW, Massie B, Greenberg B, Werner J, Klausner S, et al. Oral hydralazine therapy for chronic refractory heart failure. *Circulation*. 1976;54(6):879-83.
3. Caswell A, Reckmann M, Bellantonio J. MIMS annual. St Leonards, NSW, Australia: MediMedia Australia; 2002
4. Brunton LL, Knollmann BC, Hilal-Dandan R. Goodman & Gilman's the pharmacological basis of therapeutics. 13th ed. New York: McGraw Hill Medical; 2018.
5. Hoffman RS, Howland MA, Lewin NA, Nelson LS, Goldfrank LR. Goldfrank's Toxicologic Emergencies. New York: McGraw Hill Medical; 2015.
6. Smith BA, Ferguson DB. Acute hydralazine overdose: marked ECG abnormalities in a young adult. *Ann Emerg Med*. 1992;21(3):326-30.
7. Woolmer P. Global electrocardiograph changes and acute pulmonary oedema in an acute hydralazine overdose of a young male: A case study. *Australas Emerg Nurs J*. 2004;6(2):14-20. doi: 10.1016/S1328-2743(04)80110-X.
8. Trevor AJ, Katzung BG, Masters SB. Katzung & Trevor's Pharmacology: Examination & Board Review. 8th ed. New York: McGraw Hill Medical; 2008.
9. Rosen P. Emergency Medicine: Concepts and Clinical Practice. 2nd ed. St. Louis: Mosby; 1988.
10. Laski ME, Kurtzman NA. Acid-base disorders in medicine. *Dis Mon*. 1996;42(2):51-125.
11. Smith BA, Ferguson DB. Acute hydralazine overdose: marked ECG abnormalities in a young adult. *Ann Emerg Med*. 1992;21(3):326-30.