

Traumatic Hip Dislocation in an Infant

MT Peivandi^{1*}, AR Kachooei², S Amel-Farzad³

^{1,2}Department of Orthopedics, ³Boo-Ali Center of Research, Mashhad University of Medical Sciences, Mashhad, Iran

Abstract

A 19 month-old child with pain and deformity in hip following a downfall was admitted to the Emergency Department of Emdadi Hospital. After clinical examination and plain X-ray, hip dislocation was diagnosed and the patient was transferred to the emergency operation theater. Under general anesthesia, the hip was simply reduced using closed method. In the following day, a hip spica-cast was applied for three weeks. Regarding the low-energy trauma required in this kind of dislocation and long-term and hazardous complications due to the delayed diagnosis, it is important to consider the probability of hip dislocation in children.

Keywords: Dislocation, Hip, Close Reduction

Introduction

Hip dislocation is a rare case in children with trivial trauma in children below 5 years of age due to ligament laxity.¹ The aim of this study is to report the case of a posterior hip dislocation in a 19 month-old child due to falling off two steps. The diagnosis of dislocation in children is hard and such trauma can lead to serious complications and even open reduction.

Case Report

A 19 month-old child with pain and deformity in hip following a downfall from stairs was admitted to the Emergency Department of Emdadi Hospital. In clinical examination, there was a shortening of the right lower limb with pain and restricted motion of the hip; however, the neurovascular examination was normal. She was the first child of the family and there was no disease in the past medical history of her immediate family.

The examinations done on the other joints did not reveal any abnormality regarding the range of motion or ligament laxity. The right hip was in slight flexion, adduction and internal rotation. A plain x-ray was

done revealing posterior and superior displacement of the head of the femur out of the acetabulum without any accompanied fracture (Figure 1). Therefore, the patient was transferred to the emergency operation theater. Under general anesthesia, the hip was simply reduced, using closed method. The hip joint was stable in 90 degree of flexion and neutral rotation. On the following day, a hip spica-cast was applied. The position of the hip in the cast was in a neutral extension and a slight abduction. The casting lasted for three weeks. After the removal of the cast, the hip was stable and painless. Gradually, the child was permitted to walk. At the end of a 12-month follow-up, the plain x-ray and clinical examination revealed no problem in the hip. Meanwhile, there was no recurrence of hip dislocation.

Neurological examination and the hip range of motion were normal and there was no evidence of AVN. During the follow up period, the child was visited and examined every two weeks for two months and then once in a month for 10 months.

The parents were informed of the probable complications such as limping and recurrence of dislocation in the long term follow up.

Discussion

In recent studies, the youngest child diagnosed with traumatic hip dislocation has been 21 months old.²

*Correspondence: Mohammad Taghi Peivandi, MD, Department of Orthopedics, Mashhad University of Medical Sciences, Mashhad, Iran.
Tel: +98-511-8520028, Fax: +98-511-8596606, e-mail: Dpeivandi@yahoo.com
Received: February 12, 2008 Accepted: June 23, 2008

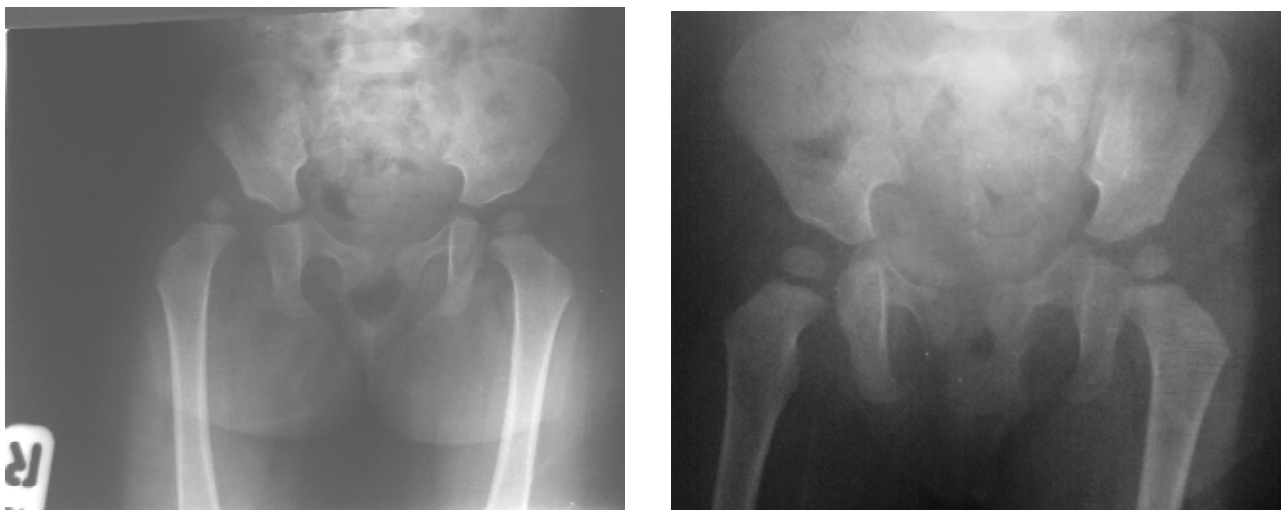


Fig 1a,b: AP x-ray of the patient that shows posterior hip dislocation (left), and after closed reduction (right).

The child reported in this study is the youngest child diagnosed with traumatic hip dislocation. In different studies, the incidence of concomitant fracture in children is reported to range from 4 to 18 percent.^{3,4} The above-mentioned patient had no fracture in the femur or pelvis, indicative of a low-energy trauma. Due to ligament laxity in children younger than 2 years, the traumatic dislocation of the hip occurs with minimal trauma.

As the traumatic dislocation of the hip in children is of rare occurrence, there are few papers dealing with this matter. Therefore, the treatment outcomes are not accurately investigated.^{4,5} In different studies, the age classification of hip dislocation is as follows: 2-6, 6-10, 10-15 years of age.^{4,6}

In a study by Pearson, it was found that hip dislocation was more common in females. The patient of this study was also female. Most of the dislocations in children are of posterior type, like the patient in this study.⁷ Since the epiphyses of the femoral head had appeared, the plain x-ray was sufficient to diagnose the problem. Yet, in suspicious cases or after reduction, there may be a need to do a CT-scan. In cases with anatomic reduction; however, there is no need to do so.⁸

In cases of occurrence of loose body or the asymmetry of the femoral head, an open reduction is necessary to prevent permanent damage to the joint cartilage.⁹ Close reduction using Allis technique is the preferred method, used for the reduction of the above case.⁸

In order to reduce the risk of possible consequences such as avascular necrosis of the head, close reduction under general anesthesia is highly advised.⁹

Due to the laxity of the ligaments and joint capsules in children, hip spica-cast is suggested by many experts,^{9,10} also being used for the above case for 3 weeks. After the removal of the cast, partial weight bearing was permitted.

In a study by Banskota, the incidence of necrosis of the femoral head is reported to be 23%.¹¹ It is worth mentioning that all the patients in that study underwent open reduction.

In a different study, the rate of AVN after simple hip dislocation was reported to range from 8 to 10 percent in which the delay in the reduction and the severity of the trauma were reported as the causes.¹ Still in another study the rate of AVN was reported to be between 5 to 58 percent.¹² In these studies, the patients' age ranged from 4 to 15 years during which the risk of AVN was higher. The risk factors involved in AVN of femoral head are the age over 6, high-energy trauma and delay in reduction more than 24 hours. The appearance of AVN may delay until 2 years after the trauma.³

The sciatic nerve injury after traumatic hip dislocation in children is reported as high as 25 percent.⁴ Some studies have reported the nerve damage as the most common complication in traumatic hip dislocation of children,^{4,12,13} whereas all neurologic examinations were normal in the above case. Due to the incomplete healing

of the posterior capsule of the hip joint, recurrent dislocation is more common in children.¹⁴

In a study by Hamilton, non-weight bearing for 3 to 8 weeks in 18 patients with hip dislocation had no effect on the prognosis of the disease.¹³ Following the AVN of the femoral head in children younger than 12 years old, changes similar to Legg-Calve disease such as sclerosis, coxa plana, coxa magna and coxa brevia have been reported.¹⁵

Osteoarthritis and heterotopic ossification with posterior dislocation of the hip in children are reported to have unknown incidence.⁹ The case in this study had none of the above-mentioned complications during the follow-up period. Considering the low-energy

trauma required in this kind of dislocation and long-term and hazardous complications due to the delayed diagnosis, it is important to consider the probability of hip dislocation in children. The delayed diagnosis of hip dislocation in children leads to high rate of complications. For example, in a study involving 8 patients all of them showed AVN of the femoral head and two of them suffered from vast and progressive changes in the femoral head.¹¹

Regarding the above-mentioned complications, to prevent such irreducible problem, in spite of its rarity, due care and early diagnosis is recommended.

Conflict of interest: None declared.

References

- Canale S.Terry, H. BeatyJames , Campbell's operative orthopaedics ,11th edition, PA USA, Mosby Elsevier, 2008; pp. 1628-9.
- Vemulapalli KK, Dey C, Peckham T, Paterson JM. Traumatic hip dislocation in a 21- month-old child. *Arch Orthop Trauma Surg* 2005;**125(7)**: 490-2. [16052338] [10.1007/s00402-005-0029-x]
- Gartland JJ, Benner JH. Traumatic dislocations in the lower extremity in children. *Orthop Clin North Am* 1976;**7(3)**:687-700. [958690]
- Pearson DE, Mann RJ. Traumatic hip dislocation in children. *Clin Orthop Relat Res* 973;**92**:89-94. [4710833]
- Reiger H, Pennig D, Klein W, Grunert J. Traumatic dislocation of the hip in young children. *Arch Orthop Trauma Surg* 1991;**110(2)**:114-7. [2015133] [10.1007/BF00393886]
- Funk FJ. Traumatic dislocation of the hip in children factors influencing prognosis and treatment. *J Bone Joint Surg Am* 1962;**44**:1135-45.
- Sanjay P, Narayana P, Sudarsanam R, Kama A. Posterior dislocation of the hip In a child following trivial trauma:A case report. *Internet J Emergency Med* 2004;**1(2)**.
- Herring JA. Tachdjians pediatric orthopedics. Texas: WB Saunders Co; 2002; p. 2275.
- Salisbury RD, Eastwood DM. Traumatic dislocation of the hip in children. *Clin Orthop Relat Res* 2000; **377**:106-11. [10943191] [10.1097/00003086-200008000-00015]
- Herring JA. Tachdjians pediatric orthopedics. Texas: WB Saunders Co; 2002; p. 2280.
- Banskota AK, Spiegel DA, Shrestha S, Shrestha OP, Rajbhandary T. Open reduction for neglected traumatic hip dislocation in children and adolescents. *J pediatr orthop* 2007;**27(2)**:187-91. [17314644]
- Hougaard K, Thomsen PB. Traumatic posterior dislocation of the hip – prognostic factors influencing the incidence of avascular necrosis of the femoral head. *Arch Orthop Trauma Surg*1986;**106(1)**: 32-5. [3566493] [10.1007/BF00435649]
- Hamilton PR, Broughton NS. Traumatic hip dislocation in childhood. *J Pediatr Orthop* 1998;**18(5)**:691-4. [9746428] [10.1097/00004694-199809000-00028]
- Simmons RL, Elder JD. Recurrent posttraumatic dislocation of the hip in children. *South Med J* 1972; **65(12)**:1463-6. [4641087]
- Barquet A. Avascular necrosis following traumatic hip dislocation in children: Factors of influence. *Acta Orthop Scand* 1982;**53(5)**:809-13. [7136593]