

Angiomyolipoma of the Adrenal Gland: A Case Report

CH Chee Kong^{1*}, I Mohamed Rose², P Singam¹, G Eng Hong¹, L Boon Cheok¹, ZM Zainuddin¹

¹Department of Surgery, Urology Unit, ²Department of Pathology, University of Kebangsaan, Malaysia Medical Center, Kuala Lumpur, Malaysia

Abstract

Adrenal angiomyolipoma is rare. Only four cases have been reported so far. We report our experience with a 61-year old man who presented with loin pain and abdominal mass. A computerised tomography (CT) scan showed an adrenal mass with features of angiomyolipoma. Adrenalectomy was performed and the histopathological features confirmed the diagnosis of adrenal angiomyolipoma. The patient recovered without any complications following surgery.

Keywords: Angiomyolipoma; Adrenal; Extrarenal

Introduction

Angiomyolipoma is a benign mesenchymal tumor consisting of varying amounts of mature adipose tissue, smooth muscle and thick walled blood vessels.¹ It arises from perivascular epithelioid cells and is commonly seen in the kidney. The extrarenal sites reported include the bone, colon, heart, lung, parotid gland, skin, spermatic cord, gynecologic organs and retroperitoneum with the most common extrarenal site being the liver.² Only 4 cases of angiomyolipoma of the adrenals have been reported in the English literature.¹⁻³

Case Report

A 61-year old man presented with a sudden onset of left loin pain. Abdominal examination revealed a vague mass in the left hypochondrium. There was no evidence of tuberous sclerosis. A computerised tomography (CT) scan showed a well defined heterogeneously enhancing left suprarenal mass measuring

10.0x10.0x10.1 cm, with -90 to +68 Hounsfield Unit (HU), consistent with fat and solid component. It compressed and displaced the left kidney, pancreatic tail, stomach and spleen but a clear fat plane was observed between these structures. CT angiogram did not show any definite arterial supply to the mass. Serum catecholamine, cortisol and urinary VMA were within normal limits.

Since it was symptomatic and malignancy could not be ruled out, he was advised for excision of the tumor. A laparoscopic adrenalectomy was attempted but the procedure was converted to open surgery due to dense adhesions. A left subcostal incision was then utilised for the adrenalectomy. The cut section of the tumor revealed an encapsulated mass with haemorrhagic and yellow to greyish necrotic areas within. Histopathological examination (Figures 1 and 2) showed that the tumor was composed of mature adipose tissue, thick walled blood vessels with irregularly arranged smooth muscle cells. Multinucleated giant cells, haemosiderin laden macrophages and golden brownish granules were also present as well as extensive necrosis and areas of haemorrhage. The smooth muscle cells were positive for smooth muscle antigen (SMA) and weakly positive for HMB45 and negative for Desmin. Based on these findings, the diagnosis made was adrenal angiomyolipoma. Post-operative recovery was uneventful and the patient was well at the one year follow-up.

*Correspondence: Christopher Ho Chee Kong, MD, Department of Surgery, University of Kebangsaan, Malaysia Medical Center, Jalan Yaacob Latif, Bandar Tun Razak, 56000 Cheras, Kuala Lumpur, Malaysia. Tel: +60-391-456202/6212, Fax: +60-391-737831, e-mail: chrisckho2002@yahoo.com
Received: November 1, 2009 Accepted: March 14, 2010

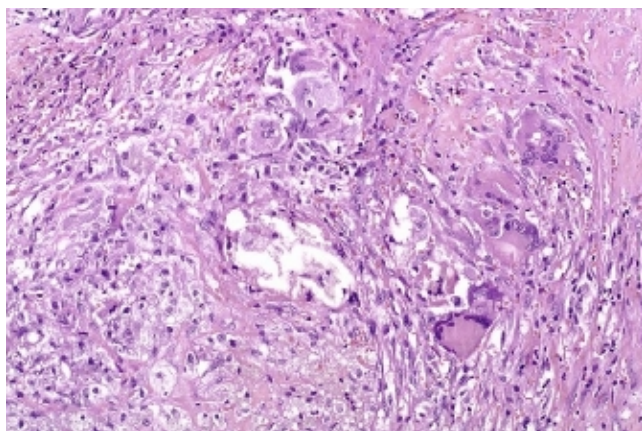


Fig. 1: A mixture of adipose cells with granular cytoplasm and cells that are spindle-shaped. Scattered multinucleated giant cells are also present. The angiomyolipoma is diffusely haemorrhagic (hematoxylin and eosin stain, 100x).

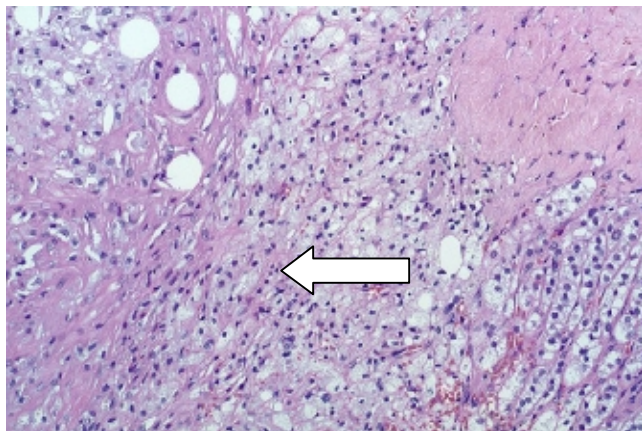


Fig. 2: Normal adrenal tissue on the right with angiomyolipoma (arrow) on the left (hematoxylin and eosin stain, 100x)

Discussion

Angiomyolipoma is a benign hamatomatous tumor. About half of the angiomyolipomas are associated with tuberous sclerosis and in these cases, they are usually multiple and bilateral.⁴ It has been estimated that approximately 80% of the severe and complete forms of tuberous sclerosis have angiomyolipoma.^{5,6} In the previous reported cases, two were associated with tuberous sclerosis, while the other two, including this case, were sporadic. A case of adrenal angiomyolipoma in lymphangiomyomatosis has also been recently reported.⁷

On CT scan, the presence of even a small amount of fat as evidenced by HU less than 10, suggests the

diagnosis of angiomyolipoma. On magnetic resonance imaging (MRI), the typical features of the fatty component include bright signal intensity on non-fat suppressed images, with dropout of signal on fat suppressed images.¹ However, these features can also be seen with other lipomatous tumors (lipoma, liposarcoma, teratoma or myelolipoma) and are not specific for angiomyolipoma. The absence of vascular supply to the tumor in this case initially made the diagnosis of angiomyolipoma remote. The size of the tumor, despite the clear fat plane between it and the adjacent structures, could not rule out the malignancy.

Grossly, angiomyolipomas appear well-circumscribed and depending on the relative amount of adipose tissue, they range from a glistening yellow (“fatty”) appearance to a more white-tan and firm appearance depending on the relative amount of adipose tissue.² Histology typically shows a variable mixture of mature adipocytes, thick-walled blood vessels and spindled and epithelioid stromal cells often radiating out from blood vessel walls. Most angiomyolipomas show predominance of adipocytes but some contain mainly spindled stromal cells and thick-walled vessels with little adipose tissue. A diagnostically helpful feature is the staining of the stromal cells for HMB-45 by immunohistochemistry. In this patient, there were areas of haemorrhage and necrosis in the tumor, suggesting an internal haemorrhage which could have caused the acute pain when he presented.

Management should be the same as that for any adrenal mass. Assessment of functional status of the tumor should be done although all the five adrenal angiomyolipomas reported so far were non-functional. Surgery is indicated if the patient is symptomatic or the tumor is more than 6 cm since the risk of malignancy increases with size.⁸ Also, the risk of spontaneous rupture increases with size, owing to the presence of abundant and abnormal elastin-poor vascularity in the tumor.⁴ Laparoscopic adrenalectomy is an option and had been successfully done for a 6 cm adrenal angiomyolipoma.⁷

Since it is a benign disease, its prognosis is good. One of the four reported patients has been alive for eight years.² Nevertheless, follow up is recommended because of atypical morphology.³ Currently, there is no agreed protocol on follow-up but an ultrasound three to six months following the surgery with annual clinical examination for large tumors is recommended.

Conflict of interest: None declared.

References

- 1 Godara R, Vashist MG, Singla SL, Garg P, Sen J, Mathur SK, Gupta A. Adrenal angiomyolipoma: A rare entity. *Indian J Urol* 2007;**23**:319-20. [19718340] [doi:10.4103/0970-1591.33734]
- 2 Elsayes KM, Narra VR, Lewis JS Jr, Brown JJ. Magnetic resonance imaging of adrenal angiomyolipoma. *J Comput Assist Tomogr* 2005;**29**:80-2. [15665688] [doi:10.1097/01.rct.0000152863.97865.47]
- 3 Lam KY, Lo CY. Adrenal lipomatous tumours: a 30 year clinicopathological experience at a single institution. *J Clin Pathol* 2001;**54**:707-12. [11533079]
- 4 Eble JN. Angiomyolipoma of the kidney. *Semin Diagn Pathol* 1998;**15**:21-40. [9503504]
- 5 Bernstein J, Robbins TO, Kissane JM. The renal lesions of tuberous sclerosis. *Semin Diagn Pathol* 1986;**3**:97-105. [3616220]
- 6 Martignoni G, Pea M, Rocca PC, Bonetti F. Renal pathology in the tuberous sclerosis complex. *Pathology* 2003;**35**:505-12. [14660101] [doi:10.1080/00313020310001619136]
- 7 Sutter R, Boehler A, Willmann JK. Adrenal angiomyolipoma in lymphangioleiomyomatosis. *Eur Radiol* 2007;**17**:565-6. [16586050] [doi:10.1007/s00330-006-0206-5]
- 8 Grumbach MM, Biller BM, Braunstein GD, Campbell KK, Carney JA, Godley PA, Harris EL, Lee JK, Oertel YC, Posner MC, Schlechte JA, Wieand HS. Management of the clinically inapparent adrenal mass ("incidentaloma"). *Ann Intern Med* 2003;**138**:424-9. [12614096]