

Effects of Low Intensity Pulsed Ultrasound on Healing of Denervated Tibial Fracture in the Rabbit

SH Sadraie¹, GhR Kaka^{2*}, M Mofid³, G Torkaman⁴, M Jalali Monfared⁵

¹Trauma Research Center, ²Applied Neuroscience Research Center, ³Department of Anatomy, Baqiyatallah University of Medical Sciences, ⁴Department of Biophysics, Tarbiat Modares University, ⁵Department of Anatomy, Army University of Medical Sciences, Tehran, Iran

Abstract

Background: Low intensity pulsed ultrasound (LIPUS) has been shown in healing of fractures. This study investigates the effect of LIPUS as a fracture-healing adjunct on the denervated tibial fractures in rabbit model.

Methods: Twenty four male Dutch rabbits were randomly divided into four groups including two control and two ultrasound-treated (US-treated) groups. A standardized mid-tibial osteotomy was performed in the right tibia. Ipsilateral sciatic nerve was cut two centimeter above the right knee. After three days, the rabbits of US-treated groups received the therapeutic dose (100 mW/cm²) of ultrasound for 15 minutes per day until the 6th and 8th week and the control groups did not receive any treatment. The rabbits were sacrificed at weeks 6th and 8th post surgery and the external fixator and tibia were carefully removed. Radiographs were taken by lateral and antero-posterior views. Mechanical testing of rabbit's tibiae was used. The specimens were taken from callus of fracture for histomorphometric study of trabecula in the fractured area. Immunohistochemical staining for ki67 was used to evaluate cellular proliferation.

Results: Radiographs showed the callus was visible indicating the ossification of the callus tissue without any significant difference between US- treated and control groups. Biomechanical, histomorphic and immunohistochemical evaluations had no significant difference between control and US-treated groups after 6 and 8 weeks postoperation.

Conclusion: These finding suggest that ultrasound therapy with features which applied in this study had no significant effect on denervated tibial fracture repair in rabbits.

Keywords: Ultrasound; Fracture; Bone healing; Nerve lesion; Rabbit

Introduction

Fracture healing is a special type of wound repair that involves a complex replay of development which leads to the restoration of the bony structure according to Einborn (1995).¹ Disorders of nerves central or peripheral can have substantial influence on bone health and repair. An almost total absence of innervation was observed in nonunited human diaphyseal fractures, raising the possibility that the lack of neural control may have led to delayed fracture healing.²

Ultrasound is a form of mechanical energy that can be transmitted into the body as high-frequency acoustical pressure waves. There are limited data supporting the effect of Low intensity pulsed ultrasound (LIPUS) on denervated bone fracture. Most of the successful studies have used LIPUS to heal fractures, because it is incapable of heating bone. Several experimental studies have confirmed the capability of LIPUS to accelerate and increase the fracture healing process in various animal models.^{3,4} Most researchers would agree that LIPUS can accelerate many kinds of bone healing, especially fracture healing^{3,4} and stimulate nonunion^{5,6} and delayed union fractures.⁵ In a placebo-controlled study of mid-shaft tibial osteotomies in rabbits, Pilla *et al.*,⁴ found that brief periods (20 min/day) of pulsed ultrasound accelerated the

*Correspondence: Gholam Reza Kaka, PhD, Applied Neuroscience Research Center, Baqiyatallah University of Medical Sciences, Tehran, Iran. Tel: +98-21-22289941, Fax: +98-21-22281561, e-mail: gh_kaka@yahoo.com
Received: April 20, 2010 Accepted: June 7, 2010

recovery of torsional strength and stiffness, which was also confirmed by a later study.³ Some investigators have looked for the optimum parameters (repetition rate, frequency, duty cycle, intensity, exposure time and etc.) of ultrasound stimulation for fracture healing.^{7,8} In placebo-controlled animal studies, Duarte⁹ reported that daily LIPUS therapy accelerated bone healing in both fibular osteotomy and femoral defect models. In clinical studies, the time required for healing of radius and tibia fractures has been reduced by 30-40% following exposure to LIPUS.^{10,11} Wang *et al.*³ and Yang *et al.*¹² reported that use of LIPUS produced a statistically significant increase in fracture callus amount, stiffness and strength in a bilateral, placebo-controlled femoral fracture model that used an intramedullary metal rod for fixation. Erdogan *et al.*¹³ found that the use of LIPUS (30 mW/cm²) improves the bone healing of mandibular fractures in rabbits.

A LIPUS (1.5 MHz and 30 mW/cm²) was investigated as an accelerator of cortical and cancellous bone fracture healing in smokers and nonsmokers.¹⁴ Cook *et al.*¹² found that the healing time for a tibial and distal radius fracture was reduced 41% in smokers and 26% in nonsmokers, and for distal radius fracture was reduced by 51% in smokers and 34% in nonsmokers following the ultrasound treatment. These studies confirmed the results obtained in clinical and animal studies of the stimulatory effect on fracture healing of LIPUS therapy. In addition, there are many aspects to evaluate optimum intensity of ultrasound on bone cells *in vitro*, including increased expression of adenylate cyclase activity,¹⁵ proteoglycan synthesis,^{16,17} collagen production,¹⁸ release of intercellular Ca²⁺,¹⁶ aggrecan mRNA expression.^{16,17}

In a study conducted by Esteki, *et al.*¹⁹ evaluating the healing rate of using dental drills at the midshaft of the right tibia in 36 mature New Zealand white rabbits. Animals were then treated with PLIUS (20 minutes/day, five times/week) and were euthanized at week 2nd, 4th, and 6th postoperatively. In control and treatment groups, radiographic and mechanical measures increased as the time point increased. Outcome measures were found to be significantly greater in the LIPUS treatment group compared with that of the control group at 4- and 6-week time points. Esteki *et al.* concluded that LIPUS can enhance healing rates in osteoperforations.

On the other hand, there is some evidences which show the use of LIPUS without any effect on bone healing, fracture repair and cell proliferation. Emami

*et al.*²⁰ did not see any effect of ultrasound on the healing time of intramedullary nailed closed fractures or grade I open tibial shaft fractures. Handolin *et al.*²¹ reported that use of LIPUS (30 mW/cm²) had no effects on bone healing in self-reinforced poly-L-lactide rod fixed experimental distal femur osteotomy in rat. He also in clinical studies^{22,23} revealed that the six-week LIPUS therapy had no effect on radiological bone morphology, bone mineral density or clinical outcome in bioabsorbable screw-fixed lateral malleolar fractures, 18 months after the injury.

In addition, some investigators²⁴ reported that the application of ultrasound did not significantly alter the cellular proliferation in either diabetes mellitus or control groups. However, mechanical testing revealed significantly greater torque to failure and stiffness in US-treated diabetes mellitus versus non-US-treated diabetes mellitus groups at six weeks post-fracture. These studies did not reveal the results obtained in clinical and animal studies of the stimulatory effect on fracture healing of LIPUS therapy.

Delayed union and non-union are common complications after fracture of the tibial shaft associated with sciatic nerve injury. There is also limited data supporting the effect of ultrasound on denervated fractured bone.^{25,26} The purpose of this study was to test the influence of LIPUS as a fracture-healing adjunct on the denervated tibial fracture in rabbit model.

Materials and Methods

Before use of animal subjects, institutional review board approval was obtained. An *in vivo* laboratory experiment using 24 skeletally mature (2.8-3.5 kg) Dutch white rabbits (Pastor Research Institute, Tehran, IR. Iran) was performed. Rabbits were randomly divided into four groups (six rabbits for each group) including US-treated and control groups (at 6th week) and another two animals including US-treated and control groups (at 8th week). The US-treated groups received the therapeutic dose (100 mW/cm²) of ultrasound and the control groups received no treatment.

The surgical procedure involved anesthetizing the rabbits under general anesthesia. The right hind limb was prepared under sterile conditions. A bilateral, one-plane external fixation device was applied to the medial and lateral aspects of the right tibia of rabbits. In four groups, through a 2-cm longitudinal incision at the middle third of the tibia, a standardized midshaft tibial osteotomy was performed resulting in an

osteotomy gap of approximately 1 mm between the bone fragments. The right tibiae only and not the fibulae were fractured. The overlying muscles and fascia were approximated in a single layer with absorbable suture followed by skin closure.

Radiographs including anterior–posterior and lateral views were taken of the right hind legs following fracture and at six and eight weeks of the treatment. Full weight bearing was allowed immediately after surgery. Ultrasound was applied to the lateral tibia in two treatment groups and sham treatment applied in the control group for 15 min/day until sacrifice 6 weeks after osteotomy.

Through a 1-cm incision over the lateral upper part of the thigh, the sciatic nerve was localized and dissected free from the adjoining vascular structures. One cm of the sciatic nerve of the animals was resected. The wound was closed with four skin stitches with absorbable suture.

Three days after surgery all rabbits in the ultrasound groups were treated with the ultrasound for 15 min a day on the fixed point of anteromedial side of right hind leg for a total period of six and eight weeks. A standard medical ultrasound generator and transducer head (Sonopulse 490, Delft Instruments, Enraf-Nonius B.V., Netherlands) was employed in the ultrasound treatments. This unit has a frequency of 1.0 MHz, with an effective radiating area of 5.8 cm². The ultrasound was applied with the rabbits held in the prone position. No anesthesia was required. After a coupling gel was applied to the skin (Aquasonic 100, Parker Laboratories, Fairfield, NJ, USA), the ultrasound transducer was then held against the anteromedial side of the right hind leg. The transducer was held in place throughout the treatment period. Beginning on the third postoperative day, US-treated groups received ultrasound with 1 MHz and pulsed 1:1 and 100 mw/cm² for 15 min/day until the 6 and 8 weeks follow-up visit. This ultrasound device (Sonopulse 490) is currently used in the Physical Therapy Department. The ultrasound physical therapy unit was calibrated to apply defined ultrasound intensity. This intensity calibration was performed by calculating the ratio of the measured ultrasonic power and the measured effective radiation area (ERA) by means of a radiation balance and a beam plot setup with a hydrophone.²⁷

At the end of the study period, six rabbits in each group were sacrificed at 6 and 8 weeks after surgery. Standard X-rays (AP and lateral views) were then taken of right hind legs to evaluate the fusion masses

in the callus region. The standard X-ray uses 50 kV, 6 mA and 1 s for exposure. The fusion masses were graded as either fused or not fused in the radiographs. All radiographs were assessed blinded and independently by a radiologist and an orthopaedic surgeon.

The effect of ultrasound on the mechanical properties of fracture healing in four groups rabbits was also evaluated after six and eight weeks post-fracture. At sacrifice, the fractured tibia was harvested, wrapped in saline soaked gauze, and stored at - 20 degree centigrade until the time of testing. Prior to testing, tibiae were thawed to room temperature and kept moist in a saline solution. The proximal and distal aspects of each tibiae were then placed in the grips of a hydraulically material testing machine (Zwick system, Germany). The bones were tested in bending until failure at a constant angular displacement rate of two degree per second. Failure was defined as the point at which increases in angular displacement failed to produce an increase in torque. Resistance maximum (R_m) was determined from the slope of the linear regression curve of the torque vs. angular displacement plot prior to the point of fracture.

Following the six and eight weeks treatment period, the animals were sacrificed. The right tibiae were removed by disarticulating the ankle and knee joints. Excess muscle tissues were removed around the callus region. The fracture tissues immediately were fixed in 10% neutral buffered formalin, and 10% nitric acid was used for decalcification. After being decalcified, the specimens were processed in a citadel 2000 tissue processor (Shandon, UK) and embedded in paraffin wax. Paraffin-embedded tissues were sectioned (thickness, 4 μm) and placed on glass slides. Six slides were made out of callus region. Six slides were made out of the mid-diaphyseal fracture regions. Five slides were stained with a standard H & E stain for histomorphometric evaluation, the other one stained for cell proliferation (Ki67 labeling) study. The slides were then examined by light microscopy, using an image analyzer (Motic system, Image analyzer) to obtain computerized micrographs, and the trabecular areas were measured under 40 times magnification to obtain computerized micrographs. At least 20 measurements were taken in the cortex and the callus in each specimen.

This portion of the experiment evaluated the effect of ultrasound on the cell proliferation of callus fracture areas in rabbit. Intestine and liver samples were obtained to serve as positive and negative controls, respectively. The fracture tissues were fixed in 10%

formaldehyde, decalcified, and embedded in paraffin. Four-micron sections were cut, prepared, and stained for cell proliferation (Ki67 labeling) analysis according to Gerlach method.²⁸

Briefly, for the detection of the Ki67 protein in paraffin sections of rabbit tissues with MIB-5, antigen retrieval is necessary. Therefore, after dewaxing, sections were immersed in 10 mmol/L citric acid, pH=6.0, and boiled at 2 bars for 3 minutes in a pressure cooker. Subsequently, slides were rinsed with Tris-buffered saline (TBS) at pH=7.2-7.4, and endogenous peroxidase was blocked by incubating the slides in 0.3% H₂O₂ TBS for 15 minutes. Sections were then incubated for 10 minutes with normal serum from the donor species of the secondary antibody followed by 1-hour incubation with the primary antibody (100 mg/mL purified antibodies). After rinsing with TBS at pH=7.2, horseradish peroxidase-conjugated goat anti mouse immunoglobulin G (H / L; Dianova, Hamburg, Germany), diluted 1:30 with 1:8 normal rat serum in TBS, was applied for 30 minutes. Sections were then rinsed with TBS and incubated for 30 minutes with horseradish peroxidase-conjugated rabbit anti-goat immunoglobulin G (H / L; Dianova), diluted 1:50 in 10% fetal calf serum TBS. Sections were rinsed with TBS, and peroxidase activity was developed for 10 minutes with 0.7 mg/mL diaminobenzidine (Sigma Chemical Co., München, Germany) and 1.6 mg/mL urea H₂O₂ in TBS, counterstained with Harris' hematoxylin, dehydrated, cleared, and mounted in Kaiser's glycerol gelatin.

Cell proliferation as a percentage of ki67 labeling cells in the callus area in four groups was also evaluated.

The differences of means among the control Us-treated groups were compared using the two-tailed independent samples *t*-test using SPSS software (Version 15, Chicago, IL, USA). A *p* value less than 0.05 was considered significant.

Results

There were no clinical or radiographical signs of infection in the healing tibia of any animal. The alignment of the tibial fractures was radiographically satisfactory in all groups. No differences were observed between the control and US-treated groups (at both 6th and 8th week) regarding fracture line visualization or callus formation, as assessed by radiographs (Figure 1 and 2).

After radiographic analysis, the stiffness of the fusion mass of tibiae in the four groups was then

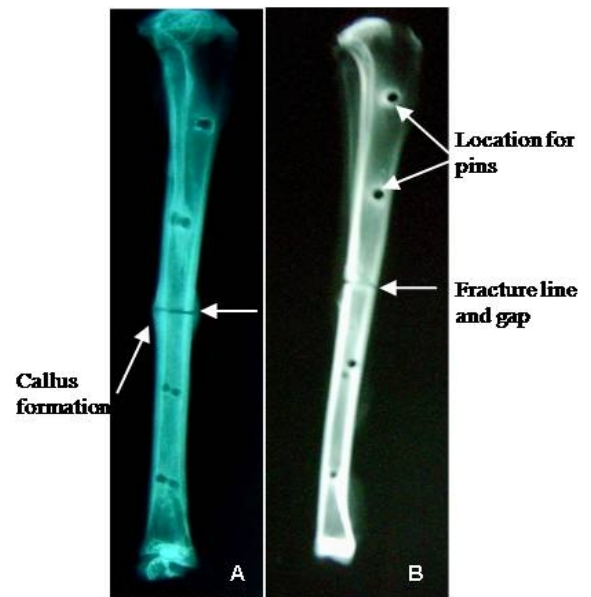

Fig. 1: Lateral radiographs of osteotomized tibiae at 6 weeks postoperatively, after removal of the external fixator. The tibia in both the control group (Fig. 1-A) and the US-treated group (Fig. 1-B) has the same radiolucent feature in the fracture line.

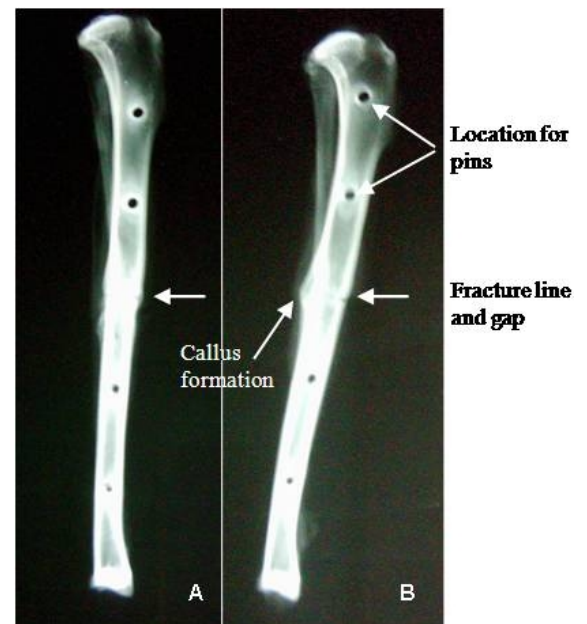


Fig. 2: Lateral radiographs of osteotomized tibiae at 8 weeks postoperatively, after removal of the external fixator. The tibia in both the control group (A) and the US-treated group (B) has dense, thick cortices in the osteotomy area in the fracture line.

determined by biomechanical testing. Biomechanical testing showed that the mean of force maximum in the control group at 6 week was 33.87±3.80 and in

the ultrasound group was 37.42 ± 4.78 . However, the mean of force maximum in the control group at 8th week was 42.79 ± 7.62 and in the US-treated group was 56.71 ± 10.31 . Significant differences in stiffness and strength were not detected between the US-treatment and control groups (both at 6th and 8th week) with the number of the animals tested in the study. The US-treated groups had the greater mean bending stiffness, when compared to the mean stiffness of the control groups but the differences were not statistically significant (Figure 3).

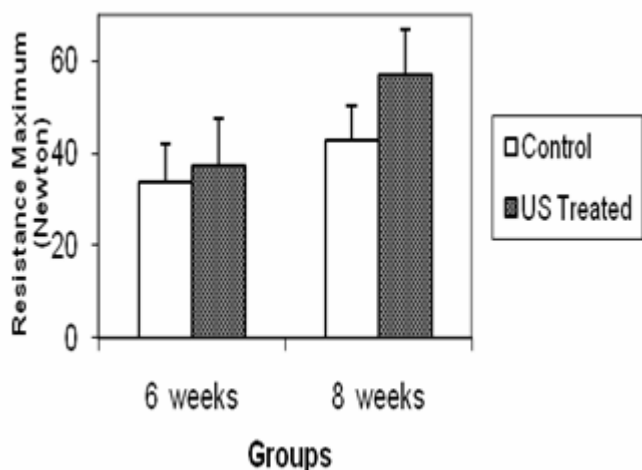


Fig. 3: Biomechanical testing (Resistance Maximum) has no significant differences between control and US-treated groups at 6 and 8 weeks post-operation.

Comparisons of the histological fusion rates demonstrated that the incidence of bone formation in US-treated sites and the histological union rate was not significantly different at 6th and 8th week. Callus histomorphometry was evaluated in 20 of 24 specimens (five specimens in each group). Histomorphometric study of trabecula in the callus region in the control group at 6th week was 57.59 ± 5.32 and in the US-treated group was 63.42 ± 4.17 . The mean of trabecula in the control group at 8th week was 67.34 ± 5.32 and in the US-treated group was 74.16 ± 4.73 . Statistic histomorphometric analysis performed on the total trabecula area did not show any significant changes between US-treated and control animals at 6th and 8th week (Figure 4). However, our histological assessment results showed a slight tendency for enhanced healing in the US-treated groups at sixth and eighth week, but no significant differences were observed between control and US-treated groups.

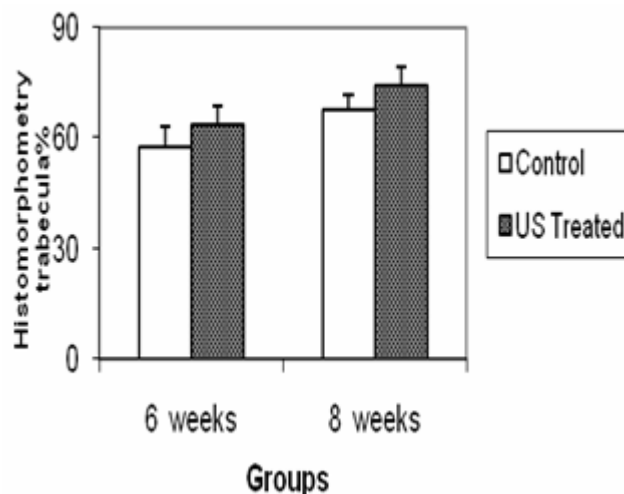


Fig. 4: Histomorphometric evaluation revealed the mean of trabecula has no significant differences between control and US-treated groups at 6 and 8 weeks post-operation.

Cell proliferation as a percentage of ki67 labeling cells in the callus area in the control group was 14.5 % and was 15.8 % of US-treated group at 6th week (Figure 5). And the percentage of ki67 labeling cell in the callus area in the control group was 16.4% and was 17.3 % of US-treated group at 8th week. However, percentage of ki67 labeling cell did not show any significant changes between US-treated and control animals at 6th and 8th week.

Discussion

In this experiment, we used the combination of mid diaphyseal tibial fracture and sciatic nerve resection to evaluate the effects of LIPUS in this animal model. Our biomechanical and histological results showed a slight tendency for enhanced healing in the US-treated groups at six and eight weeks but no significant differences were observed between US-treated and control groups. It has been reported that the appropriate LIPUS dose was 100 mW/cm^2 pulsed ultrasound, a dose alternative to that traditionally used in medicine.²⁹ Most researchers showed that LIPUS can accelerate many kinds of bone healing (especially fracture healing),^{3,4} and stimulate nonunion^{5,6} and delayed union.⁷ In a placebo-controlled study of mid-shaft tibial osteotomies in rabbits, Pilla *et al.*⁴ found that brief periods (20 min/day) of pulsed ultrasound accelerated the recovery of torsional strength and stiffness, which was also confirmed by a later study.³

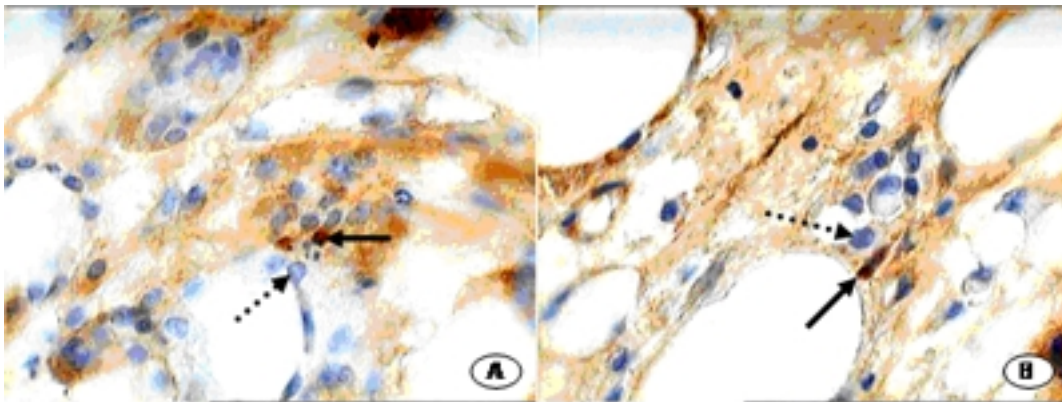


Fig. 5: Immunohistological sections of healing fracture calluses stained with ki67 at six weeks post-fracture observed under 400× magnification. These pictures represent areas of woven bone formation in the callus area. Ki67-positive cells are stained in brown. Comparison of Fig A and B demonstrated that Ki67-positive cells (arrows) and Ki67-negative cells (interrupted arrows) in the callus region of control group (A) appear similar in US-treated group (B).

On the other hand, It has been previously shown that even 12 weeks of daily 20-min low intensity (30 mW/cm²) pulsed ultrasound exposure has no effect on the mechanical or molecular properties of self-reinforced poly-L: -lactide screws in vitro.²¹ They reported that overall compliance for the daily ultrasound treatments was good, but they suggested that LIPUS did not have a clinically significant effect on the biodegradation rate of SR-PLLA screws in vivo.

Our results on healing of fracture by ultrasound are in agreement with Emami *et al.*²⁰ who also found that LIPUS treatment did not shorten healing time in fresh tibial fractures treated with a reamed and statically locked intramedullary nail. But our data are in conflict with study by Perry *et al.*³⁰ who reported that bone formation can be induced by very low-intensity mechanical stimuli, and it is clear that ultrasound could be a useful therapeutic intervention for bone loss diseases. In addition, our results also agree with those of Handolin *et al.*²¹ which reported that no obvious findings were noticed to demonstrate that LIPUS enhances bone healing in self-reinforced poly-L: -lactide rod fixed experimental metaphyseal distal femur osteotomy and our findings are in conflict with earlier study by Wang *et al.*³ Yang *et al.*¹² reported that use of LIPUS produced a statistically significant increase in fracture callus amount, stiffness and strength in femoral fracture model that used an intramedullary metal rod for fixation. This may be due to different dosage of ultrasound used in those studies and because of our smaller size groups. However, the exact mechanism involved in fracture healing is still unclear.

Our findings in denervated fractures have not

shown clear differences between the control and US-treated groups regarding the fracture line in radiographs. This results agree with Handolin *et al.* who showed that LIPUS had no advantages over normal healing when using bioabsorbable screws or rods.²¹ Mai *et al.* also evaluated the effects of ultrasound on Resorb-X plates and pins in sheep.³¹ Their results showed the late phase of wound healing after nine weeks, which is in the normal range of natural bone healing. They concluded that ultrasound does not lead to any cellular reaction in the bone with pin insertion.³¹ In addition, our histomorphometric results showed that at 6th and 8th week, the amount of trabecular formation was found to be a little more in US-treated groups when compared to control groups at sixth and eighth week, indicating that ultrasound had no clear effect on the rate of new bone formation. In addition, the amount of Ki67 labeling was observed to be even in the control US-treated groups during the follow-up, which suggests that ultrasound exposure had no clear effect on the rate of cell proliferation around the healing osteotomy line or the adjacent callus.

Values of radiological, biomechanical, histomorphometrical and cellular proliferation properties in ultrasound exposed animals were not significantly different to control values. The results of the present study are in agreement with the results of Handolin *et al.*²¹ who reported no obvious findings to support the hypothesis that LIPUS enhances bone healing in self-reinforced poly-L: -lactide rod fixed experimental metaphyseal distal femur osteotomy in rats. In other reports,^{22,23} it was shown that LIPUS did not have a clinically significant effect on the biodegradation rate of the SRPLLA screw in human. Therefore, the evi-

dence accumulated in this study suggests that application of LIPUS energy does not significantly affect on healing of denervated tibial fracture in rabbits. It seems that ultrasound may affect earlier phases of fracture healing, but not the remodeling phase.³² However, the specific mechanism by which ultrasound affects on callus formation is unclear.²⁵ These results have no obvious findings that LIPUS enhances bone healing in denervated external fixed mid-diaphyseal osteotomy in rabbits.

No significant differences in indicators of fracture repair such as radiographic, biomechanic and histomorphometric parameters were found between US-treated and control groups in the study. This experiment revealed that ultrasound therapy with features which

applied in this study had no clear effect on denervated tibial fracture repair in rabbits. This does not mean that ultrasound should be discarded as a therapeutic modality. However, it does mean that further studies are needed to examine another doses and durations of LIPUS to evaluate the role of ultrasound therapy in the healing of denervated fractures.

Acknowledgement

We would like to thank Baqiyatallah University of Medical Sciences for financial support of this study.

Conflict of interest: None declared.

References

- 1 Einhorn TA. Enhancement of fracture-healing. *J Bone Joint Surg Am* 1995;**77**:940-56. [7782368]
- 2 Santavirta S, Kontinen YT, Nordestrom D, Makela A, Sorsa T, Hukkanen M, and Rokkannen P. Immunologic studies of nonunited fractures. *Acta Orthop Scand* 1992; **63**:579-86. [1471500]
- 3 Wang SJ, Lewallen DG, Bolander ME, Chao EY, Ilstrup DM, Greenleaf JF. Low intensity ultrasound treatment increases strength in a rat femoral fracture model. *J Orthop Res* 1994;**12**:40-7. [8113941] [doi: 10.1002/jor.1100120106]
- 4 Pilla AA, Mont MA, Nasser PR, Khan SA, Figueiredo M, Kaufman JJ, Siffert RS. Non-invasive low-intensity pulsed ultrasound accelerates bone healing in the rabbit. *J Orthop Trauma* 1990;**4**:246-53. [223 1120] [doi:10.1097/00005131-199004030-00002]
- 5 Dickson K, Katzman S, Delgado E, Contreras D. Delayed unions and nonunions of open tibial fractures. Correlation with arteriography results. *Clin Orthop Relat Res* 1994; **302**:189-93. [8168299]
- 6 Mayr E, Frankel V, Rüter A. Ultrasound--an alternative healing method for nonunions? *Arch Orthop Trauma Surg* 2000;**120**:1-8. [10653095]
- 7 Darder A, Gomar F. A series of tibial fractures treated conservatively. *Injury* 1975;**6**:225-35. [1092615] [doi: 10.1016/0020-1383(75)90110-2]
- 8 Dyson M, Brookes M. Stimulation of bone repair by ultrasound. *Ultrasound Med Biol* 1983;**Suppl 2**:61-6. [6545743]
- 9 Duarte LR. The stimulation of bone growth by ultrasound. *Arch Orthop Trauma Surg* 1983;**101**:153-9. [6870 502] [doi:10.1007/BF00436764]
- 10 Heckman JD, Ryaby JP, McCabe J, Frey JJ, Kilcoyne RF. Acceleration of tibia fracture-healing by non-invasive, low-intensity pulsed ultrasound. *J Bone Joint Surg Am* 1994;**76**:26-34. [8288661]
- 11 Kristiansen TK, Ryaby JP, McCabe J, Frey JJ, Roe LR. Accelerated healing of distal radial fractures with the use of specific, low intensity ultrasound. A multicenter, prospective, randomized, double-blind, placebo-controlled study. *J Bone Joint Surg Am* 1997;**79**:961-73. [9234872]
- 12 Yang KH, Parvizi J, Wang SJ, Lewallen DG, Kinnick RR, Greenleaf JF, Bolander ME. Exposure to low-intensity ultrasound increases aggrecan gene expression in a rat femur fracture model. *J Orthop Res* 1996;**14**:802-9. [8893775] [doi:10.1002/jor.1100140518]
- 13 Erdogan O, Esen E, Ustün Y, Kürkçü M, Akova T, Gönülşen G, Uysal H, Cevlik F. Effects of low-intensity pulsed ultrasound on healing of mandibular fractures: an experimental study in rabbits. *J Oral Maxillofac Surg* 2006;**64**:180-8. [164 13888] [doi:10.1016/j.joms.2005.10.027]
- 14 Cook SD, Ryaby JP, McCabe J, Frey JJ, Heckman JD, Kristiansen TK. Acceleration of tibia and distal radius fracture healing in patients who smoke. *Clin Orthop Relat Res* 1997;**337**:198-207. [9137191] [doi:10.1097/00003086-199704000-00022]
- 15 Ryaby JT, Mathew J, Duarte-Alves P. Low intensity pulsed ultrasound affects adenylate cyclase activity and TGF- α synthesis in osteoblastic cells. *Trans Orthop Res Soc* 1992; **7**:590.
- 16 Parvizi J, Wu CC, Lewallen DG, Greenleaf JF, Bolander ME. Low-intensity ultrasound stimulates proteoglycan synthesis in rat chondrocytes by increasing aggrecan gene expression. *J Orthop Res* 1999; **17**:488-94. [10459753] [doi:10.1002/jor.1100170405]
- 17 Yang KH, Parvizi J, Wang SJ, Lewallen DG, Kinnick RR, Greenleaf JF, Bolander ME. Exposure to low-intensity ultrasound increases aggrecan gene expression in a rat femur fracture model. *J Orthop Res* 1996;**14**:802-9. [8893775] [doi:10.1002/jor.1100140518]
- 18 Reher P, Doan N, Bradnock B, Meghji S, Harris M. Therapeutic ultrasound for osteoradionecrosis: An in vitro comparison between 1 MHz and 45 kHz machines. *Eur J Cancer* 1998;**34**:1962-8. [10023323] [doi:10.1016/S0959-8049(98)00238-X]
- 19 Esteki A, Yasrebi B, Shadmehr A. Pulsed low-intensity ultrasound enhances healing rate in the osteoperforated tibia in a rabbit model. *J Orthop Trauma* 2010;**24**:170-5. [2018 2253] [doi:10.1097/BOT.0b013e3181b778e8]
- 20 Emami A, Petrén-Mallmin M, Larsson S. No effect of lowintensity ultrasound on healing time of intramedullary fixed tibial fractures. *J Orthop Trauma* 1999;**13**:252-7. [103 42350] [doi:10.1097/00005131-199905000-00005]
- 21 Handolin L, Partio EK, Arnala I, Pajarinen J, Päätilä H, Rokkanen P. The effect of low-intensity pulsed ultrasound on bone healing in SR-PLLA rod fixed experimental distal

- femur osteotomy in rat. *J Mater Sci Mater Med* 2007;**18**:1239-45. [17 277987] [doi:10.1007/s10856-006-0096-8]
- 22 Handolin L, Kiljunen V, Arnala I, Kiuru MJ, Pajarinen J, Partio EK, Rokkanen P. No long-term effects of ultrasound therapy on bioabsorbable screw-fixed lateral malleolar-fracture. *Scand J Surg* 2005;**94**:239-42. [16259175]
- 23 Handolin L, Kiljunen V, Arnala I, Kiuru MJ, Pajarinen J, Partio EK, Rokkanen P. Effect of ultrasound therapy on bone healing of lateral malleolar fractures of the ankle joint fixed with bioabsorbable screws. *J Orthop Sci* 2005;**10**:391-5. [16075172] [doi:10.1007/s00776-005-0901-0]
- 24 Gebauer GP, Lin SS, Beam HA, Vieira P, Parsons JR. Low-intensity pulsed ultrasound increases the fracture callus strength in diabetic BB Wistar rats but does not affect cellular proliferation. *J Orthop Res* 2002;**20**:587-92. [12038635] [doi:10.1016/S0736-0266(01)00136-X]
- 25 Tis JE, Meffert CR, Inoue N, McCarthy EF, Machen MS, McHale KA, Chao EY. The effect of low intensity pulsed ultrasound applied to rabbit tibiae during the consolidation phase of distraction osteogenesis. *J Orthop Res* 2002;**20**:793-800. [121 68669] [doi:10.1016/S0736-0266(02)00003-7]
- 26 Madsen JE, Aune AK, Falch JA, Hukkanen M, Kontinen YT, Santavirta S, Nordsletten L. Neural involvement in post-traumatic osteopenia: An experimental study in the rat. *Bone* 1996;**18**:411-6. [8739898]
- 27 Hekkenberg RT, Oosterbaan WA. Evaluation of ultrasound therapy devices: TNO-test radiation safety and dose accuracy often leave something to be desired. *Physiotherapy (UK)* 1986;**72**:390-5.
- 28 Gerlach C, Sakkab DY, Scholzen T, Dassler R, Alison MR, Gerdes J. Ki-67 expression during rat liver regeneration after partial hepatectomy. *Hepatology* 1997;**26**:573-8. [930 3485] [doi:10.1002/hep.510260307]
- 29 Wiltink A, Nijweide PJ, Oosterbaan WA, Hekkenberg RT, Helders PJ. Effect of therapeutic ultrasound on endochondral ossification. *Ultrasound Med Biol* 1995;**21**:121-7. [7754572] [doi:10.1016/0301-5629(94)00092-1]
- 30 Mark J. Perry, Laura K. Parry, Victoria J. Burton, Sabina Gheduzzi, Jon N. Beresford, Victor F. Humphrey, Tim M. Skerry. Ultrasound mimics the effect of mechanical loading on bone formation in vivo on rat ulnae, Medical Engineering.
- 31 Mai R, Lauer G, Pilling E, Jung R, Leonhardt H, Proff P, Stadlinger B, Pradel W, Eckelt U, Fanghänel J, Gedrange T. Bone welding--a histological evaluation in the jaw. *Ann Anat* 2007;**189**:350-5. [17695991] [doi:10.1016/j.aanat.2007.02.023]
- 32 Pilla AA, Mont MA, Nasser PR, Khan SA, Figueiredo M, Kaufman JJ, Siffert RS. Non-invasive low-intensity pulsed ultrasound accelerates bone healing in the rabbit. *J Orthop Trauma* 1990;**4**:246-53. [22 31120] [doi:10.1097/00005131-199004030-00002]