

# The Effect of Estrogen Usage on Eccentric Exercise-Induced Damage in Rat Testes

Serpil Can<sup>1,\*</sup>; Jale Selli<sup>2</sup>; Basak Buyuk<sup>2</sup>; Sergulen Aydin<sup>3</sup>; Ramazan Kocaaslan<sup>4</sup>; Gulname Findik Guvendi<sup>5</sup>

<sup>1</sup>Department of Physiology, School of Medicine, Kafkas University, Kars, Turkey

<sup>2</sup>Department of Histology and Embryology, School of Medicine, Ataturk University, Erzurum, Turkey

<sup>3</sup>Department of Family Medicine, School of Medicine, Kafkas University, Kars, Turkey

<sup>4</sup>Department of Urology, School of Medicine, Kafkas University, Kars, Turkey

<sup>5</sup>Department of Pathology, School of Medicine, Kafkas University, Kars, Turkey

\*Corresponding Author: Serpil Can, Department of Physiology, School of Medicine, Kafkas University, Kars, Turkey. Tel: +90-50566260271, E-mail: drserpilcan@gmail.com

Received: August 4, 2014; Revised: January 24, 2015; Accepted: March 15, 2015

**Background:** Recent years, lots of scientific studies are focused on the possible mechanism of inflammatory response and oxidative stress which are the mechanism related with tissue damage and exercise fatigue. It is well-known that free oxygen radicals may be induced under invitro conditions as well as oxidative stress by exhaustive physical exercise.

**Objectives:** The aim of this study was to investigate the effects of anabolic steroids in conjunction with exercise in the process of spermatogenesis in the testes, using histological and stereological methods.

**Materials and Methods:** Thirty-six male Sprague Dawley rats were divided to six groups, including the control group, the eccentric exercise administered group, the estrogen applied group, the estrogen applied and dissected one hour after eccentric exercise group, the no estrogen applied and dissected 48 hours after eccentric exercise group and the estrogen applied and dissected 48 hours after eccentric exercise group. Eccentric exercise was performed on a motorized rodent treadmill and the estrogen applied groups received daily physiological doses by subcutaneous injections. Testicular tissues were examined using specific histopathological, immunohistochemical and stereological methods. Sections of the testes tissue were stained using the TUNEL method to identify apoptotic cells. Apoptosis was calculated as the percentage of positive cells, using stereological analysis. A statistical analysis of the data was carried out with one-way analysis of variance (ANOVA) for the data obtained from stereological analysis.

**Results:** Conventional light microscopic results revealed that testes tissues of the eccentric exercise administered group and the estrogen supplemented group exhibited slight impairment. In groups that were both eccentrically exercised and estrogen supplemented, more deterioration was detected in testes tissues. Likewise, immunohistochemistry findings were also more prominent in the eccentrically exercised and estrogen supplemented groups.

**Conclusions:** The findings suggest that estrogen supplementation increases damage in testicular tissue due to eccentric exercise.

**Keywords:** Exercise; Testis; Estrogens; Rats

## 1. Background

Exercise, described as any bodily activities that enhance, or maintain physical fitness and overall health and wellness, play an important role in particular in Western societies. It is known that even moderate exercise is a stress situation for which the body must find a new dynamic equilibrium. This process requires, among other things, adaptive responses of the hormonal systems (1). Briefly, during exercise, the body sets up a new system and tries to adapt to it in two ways. One is through the hypothalamic-pituitary axis, which is a major part of the neuroendocrine system that controls and regulates many vital body processes (2). Another is by eliminating, through cellular mechanisms, the increasing levels of Reactive Oxygen Species (ROS), which are highly reactive, toxic and cause damage to proteins, lipids, carbohydrates and DNA (3). These two systems have a close relationship with

each other to overcome stress during exercise. At the microenvironment level, antioxidant enzymes such as catalase, superoxide dismutase and glutathione peroxidase defend the cell against the harmful effects of ROS. The hypothalamic-pituitary axis helps cells via hormones such as Follicle Stimulating Hormone (FSH), Luteinizing Hormone (LH) and end products (cortisone, testosterone, estrogen, etc.), which bind to receptors in the cell cytoplasm or nucleus and accelerate the production of various antioxidants (4-7).

Estrogen exerts a variety of important physiological effects, which have been suggested to be mediated via two known Estrogen Receptors (ERs), alpha and beta. With a higher affinity than ER $\beta$ , 17 $\beta$ -estradiol (E2) binds ER $\alpha$  and promotes higher rates of ER $\alpha$ -mediated transcriptional activity in Estrogen Response Elements (ERE). Estrogen is

believed to have a high antioxidant capacity, membrane stabilizing properties and a gene regulatory effect. It has been suggested that estrogen could play a role in reducing tissue damage (8).

In the literature, there are many studies in which exercise as a stress model has been applied to different animals to show its possible effects on different organs through the help of various laboratory techniques (9, 10). However, there is no information about male infertility associated with stress depending on eccentric exercise and the effect of estrogen used on testes tissues.

## 2. Objectives

In this study, we examined the effects of both extensive exercise and estrogen on rat testes using histological, immunohistochemical and stereological techniques; we also attempted to discover a relationship between infertility and exercise/estrogen.

## 3. Materials and Methods

Thirty-six male Sprague Dawley rats (12 weeks old,  $245 \pm 22.89$  gr in weight) in groups of six per cage, under controlled conditions of constant temperature/humidity, and exposed to a 12-hour light/dark cycle, were housed in facilities accredited by international guidelines. Studies were approved by and conducted in accordance with the Institutional Animal Care and Use committee of Ataturk University (ATADEM-Approval No: 2010 -11/65; No. B30.2.ATA.023.85 - 103). Our study was an experimental research study. Thirty-six rats were allocated randomly to six groups, as shown in Figure 1.

### 3.1. Experimental Model and Named Groups

Exercise was performed on a motorized rodent treadmill with an electric shock grid. Animals ran at  $20 \text{ m/minute}^{-1}$  on a 15% grade (downhill) for 90 minutes. All animals in exercise groups completed 90 minutes of exercise (11).

Animals in estrogen groups received daily  $\beta$ -estradiol 3-benzoate ( $10 \mu\text{g/kg}$   $\beta$ -estradiol dissolved in sesame oil) by subcutaneous injections (12). Injections were made to the neck fold and administered for 30 consecutive days. The animals exercised for 24 hours following the final injection (13, 14). All animals were sacrificed at 1 hour or 48 hours after exercise by the perfusion-fixation method under isoflurane anesthesia. All animals were dissected and testicular tissues were removed for histological procedures and kept in appropriate conditions.

### 3.2. Research Methods

#### 3.2.1. Immunohistochemistry Methods

Immunohistochemistry by NF- $\kappa$ B-p65 and TUNNEL staining in paraffin sections was performed as follows: the sections were deparaffinized and treated with proteinase K solution ( $20 \mu\text{g/mL}$  in PBS) for 15 minutes at room temperature. Subsequently, the sections were washed in distilled water and immersed in 3% hydrogen peroxide for 15 minutes. After several washes with PBS ( $50 \text{ mM}$  sodium phosphate and  $200 \text{ mM}$  NaCl at pH 7.4), the sections were immersed in an equilibration buffer at room temperature for 20 minutes. Some sections were incubated with rabbit anti-human NF- $\kappa$ B/p65 primary

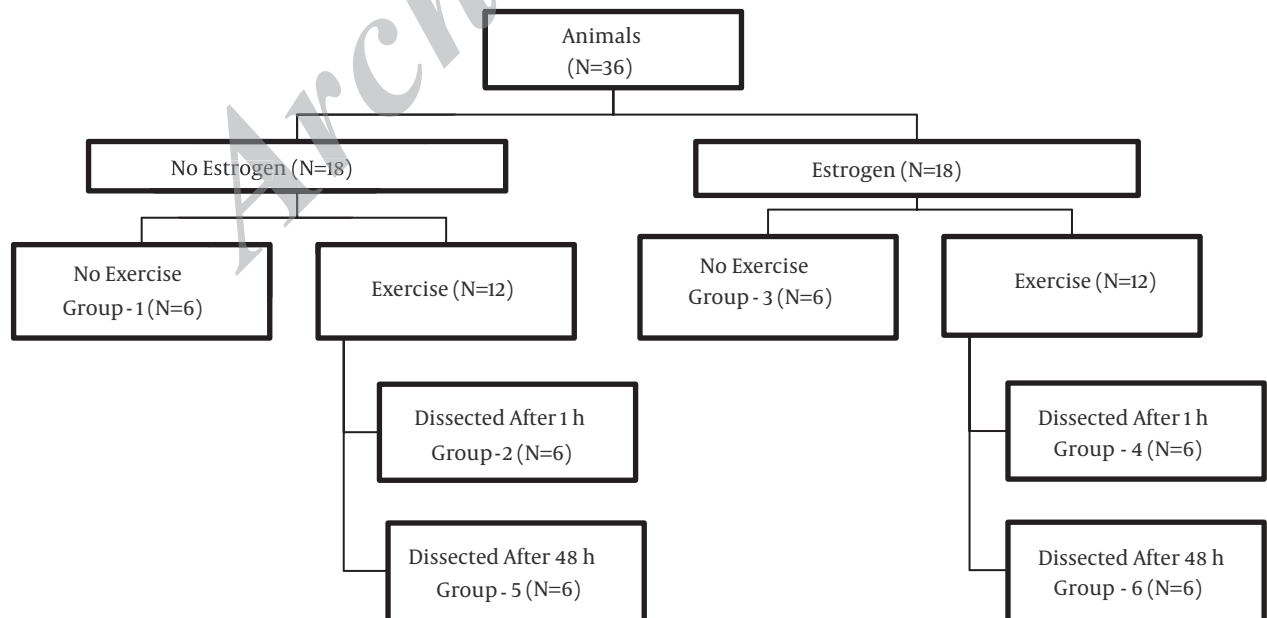


Figure 1. Experimental Protocols and Study Groups

antibody (1:50, Santa Cruz Biotechnology, sc-109) at 37°C for one hour in a humidified chamber to detect immune and inflammatory responses. Others were incubated with terminal deoxynucleotidyl transferase and biotinylated dNTP (Life Technologies, Inc.) at 37°C for one hour in a humidified chamber in order to detect DNA breaks. Then, the reaction was stopped by immersion in a stop/wash buffer. After several washes, all sections were incubated in anti-digoxigenin-peroxidase for 30 minutes at room temperature. The reaction was revealed with 0.06% 3, 3-diaminobenzidine tetrahydrochloride (Sigma Chemical, St. Louis, MO) in PBS for three to six minutes, and the sections were counterstained with Mayer's hematoxylin. The sections were examined and photographed under a light microscope (Olympus BH-40).

### 3.2.2. Histological Examination of Paraffin Sections

After removing the testes, they were fixed with 10% buffered formalin for 24 to 48 hours in order to prepare them for histopathological examinations. After the fixation and routine preparation of the samples, according to the conventional light microscopic technique, they were embedded in paraffin. Using a microtome (Leica RM2125RT), 5- $\mu$ m-thick sections were cut and stained with Mallory's triple stain modified by Crossman in order to determine the general structure of testicular connective tissues.

### 3.2.3. Histological Examination in Semi-Thin Plastic Sections

After dividing the testicular tissue to small pieces under a stereomicroscope (Lumiscope No.KS 65893), samples were fixed in 3% glutaraldehyde in 0.1 M phosphate buffer, post-fixed in 1% phosphate-buffered osmium tetroxide, dehydrated in a graded acetone series and washed in propylene oxide. After dehydration, specimens were embedded in fresh Araldite CY 212 (Agar, Cambridge, UK). Sections were cut using an ultramicrotome (Nova LKB Bromma, Sweden). Each araldite-embedded tissue block was cut to sections of about 1  $\mu$ m thickness and stained with toluidine blue. These sections were photographed by a light photomicroscope (Olympus BH 40) for light microscopy examination.

### 3.2.4. Stereological Examination

Stereological analysis was carried out on immunopositive germ cells with TUNNEL in testicular tissue sections. For this purpose, a microscope with a camera attachment plus a computerized system and specialized software (Stereoinvestigator V-9 (Leica)) were used. Furthermore, TUNNEL-positive germ cells' numerical density was estimated via the Fractionator method as described in previous studies (15, 16).

### 3.2.5. Statistical Analysis

To evaluate the significance of the observed differences,

we used the one-way analysis of variance (ANOVA) followed by Tukey's HSD multiple range test. All statistical calculations were performed using the SPSS 15.0 software for Windows (SPSS Inc., USA). Statistical significance was set at  $P < 0.05$ . All data were expressed as mean  $\pm$  Standard Error of the Mean (SEM) for the six rats in each group.

## 4. Results

### 4.1. Conventional Light Microscopic Results

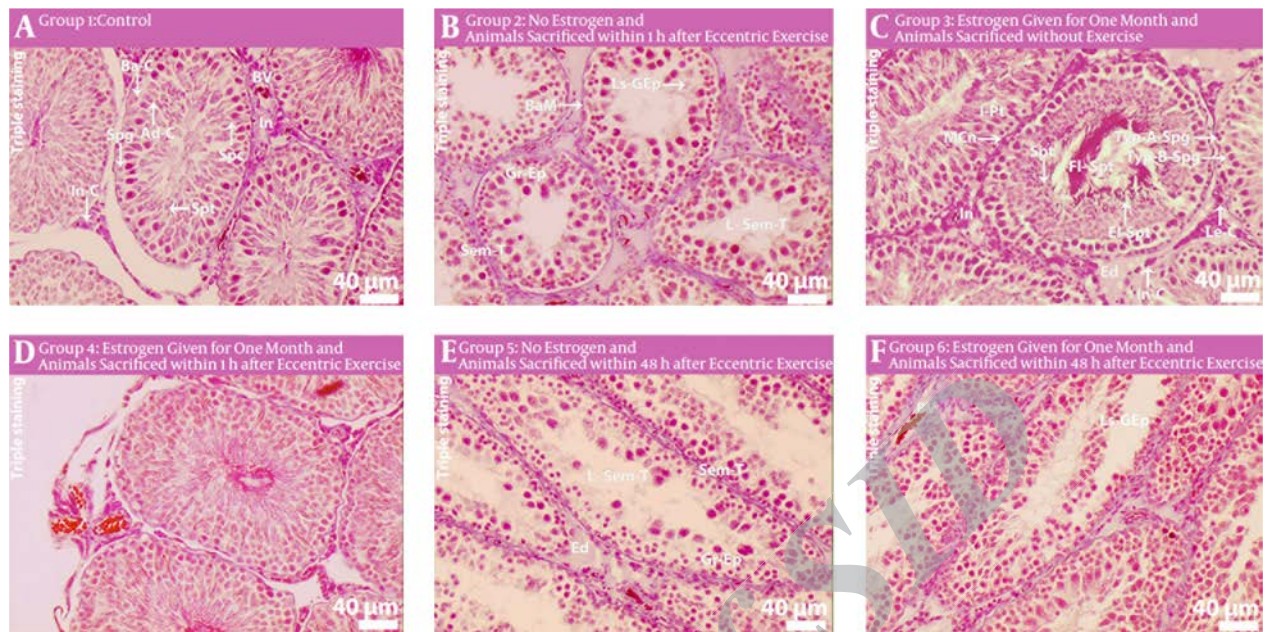
#### 4.1.1. Results of Triple Staining

Histopathological evaluation of the control group's testes revealed regular-shaped seminiferous tubules with germinal epithelium and underlying basement membranes. Spermatogonia, Sertoli cells, which are located in the basal compartment, and spermatocytes, which are located in the adluminal compartment, were observed as normal. Lumen of seminiferous tubules was filled with mature spermatids tails. Leydig cells located in the interstitial tissue showed regular shape (Figure 2 A). In the examination of the non-estrogen applied and dissected one hour after eccentric exercise group, seminiferous tubules were noticed with reduced thickness of germinal epithelium. Lumen of seminiferous tubules was observed free from spermatids (Figure 2 B). Unlike the control group, spermatocytes with condensed and fragmented nuclei were detected in the local areas of seminiferous tubules (Figure 2 B). Cross-sections of the estrogen applied group exhibited normal structures of seminiferous tubules with small irregularities. Additionally, increased mitotic activity of spermatogonial cells was noticed (Figure 2 C). In the examination of the estrogen applied and dissected one hour after eccentric exercise group, the cross-sectional conspicuous feature of testicular tissues was the increasing number of interstitial tissue cellular components. The border of seminiferous tubules was observed as irregular and a thickening of the underlying basement membrane was also detected (Figure 2 D). Evaluation of the testes of the no estrogen applied and dissected 48 hours after eccentric exercise group revealed a reduction of germinal epithelium in tubules and some tubules were completely distorted (Figure 2 E). Lumen of seminiferous tubules was free of mature spermatid tails (Figure 2 E). In examination of the estrogen applied and dissected 48 hours after eccentric exercise group, an extreme irregularity of tubules and a reduction of germinal epithelium in seminiferous tubules was remarkable (Figure 2 F).

#### 4.1.2. Results of Toluidine Blue Staining

Evaluation of the control group's semi-thin plastic sections revealed seminiferous tubules containing normal structured germinal epithelium and the lumen of tubules filled with mature spermatids (Figure 3 A). Cross-sections of the no estrogen applied and dissected one hour after



**Figure 2.** Testes Cross-Sections

Staining: Mallory's triple staining method. Ad-C: Adluminal Compartment, Ba-C: Basal Compartment, BaM: Basement Membrane, BV: Blood Vessel, El-Spt: Elongating Spermatids, Ed: Edema, Fl-Spt: Flagella of Spermatid, Gr-Ep: Germinal Epithelium, In: Interstitium, Inc: Inclusion, I-Pt: Peritubular tissue with irregular outline, Le-C: Leydig cell, L-Sem-T: Lumen of Seminiferous Tubule, Ls-GEp: Loss of Germinal Epithelium, Mcn: Myoid cell nucleus, Sem-T: Seminiferous Tubule, Spc: Spermatocyte, Spg: Spermatogonia, Spt: Spermatid, Typ-A-Spg: Type A Spermatogonia, Typ-B-Spg: Type B Spermatogonia, Z-Spc zygote spermatocyte.

eccentric exercise group exhibited reduced thickness of the germinal epithelium and irregular boundaries of seminiferous tubules (Figure 3 B). In examination of the estrogen applied group, sections of thickening in the basement membrane were observed in the tubules. However, the thickness of the germinal epithelium was found normal, and the number of spermatids was decreased in the lumen of the seminiferous tubules (Figure 3 C). Cross-sections of the estrogen applied and dissected one hour after eccentric exercise group exhibited more irregularity of seminiferous tubules. Additionally, edema was detected between the germinal epithelial cells and basement membranes (Figure 3 D). In examination of the no estrogen applied and dissected 48 hours after eccentric exercise group, sections showed remarkable reduction in the thickness of germinal epithelium. Chromatin condensation was detected particularly in spermatogonia located in the basal compartment. Spermatogenetic arrest was also detected in this group (Figure 3 E). In the evaluation of the estrogen applied and dissected 48 hours after eccentric exercise group, sections revealed excessive irregularity of the seminiferous tubules. Thickness of the basal membranes and germinal epithelium were obviously decreased. Hyperchromasia, vacuolization, edema and spermatogenetic arrest were also determined in the germ cells, which form the germinal epithelium (Figure 3 F).

## 4.2. Immunohistochemistry Results

### 4.2.1. Results of TUNNEL Staining


TUNNEL immunopositivity of germ cells, which form the germinal epithelium and interstitial cells, were not observed in the evaluation of testicular sections of the control group (Figure 4 A). Immunopositivity of most germ cells that make up the germinal epithelium was conspicuous in the examination of sections of the no estrogen applied and dissected one hour after eccentric exercise group. Immunopositivity of Sertoli cells and spermatogonia were detected in the early stage of development (Figure 4 B). In the examination of the estrogen applied group, immunopositivity of cross-sections was remarkable in spermatogonia and in primary spermatocytes (Figure 4 C). Immunopositivity of all germinal cells were only observed in some of the tubules of the estrogen applied and dissected one hour after eccentric exercise group (Figure 4 D). In general, primary spermatocytes do not exhibit immunopositivity, however, some of Sertoli cells had immunopositivity (Figure 4 D). Immunopositivity of Sertoli cells and spermatogonia located in the basal compartment of tubules were remarkable in cross-sections of the no estrogen applied and dissected 48 hours after eccentric exercise group. Spermatids forming the acrosome granules exhibited immunopositivity (Figure 4 E). A strong immunopositivity of spermatogonia and Sertoli cells, which form most of the germinal



epithelium of the seminiferous tubules, was detected in the examination of cross-sections of the estrogen applied and dissected 48 hours after eccentric exercise group.

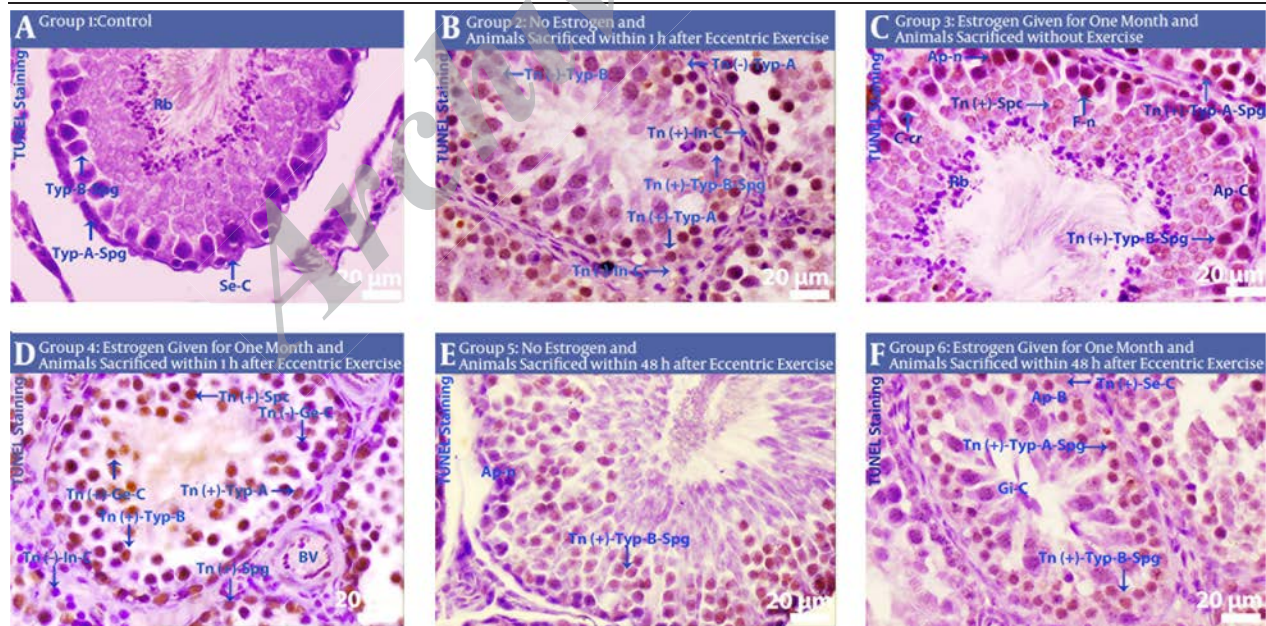
Immunopositivity was not determined in sporadic spermatids located close to the lumen. Additionally, giant cell formations were noticed (Figure 4 F).

**Figure 3.** Testes Cross-Sections



Staining: Toluidine Blue, Ac: Acrosome, Ap-C: Apoptotic Cell, BaM: Basement Membrane, Early-Spt: Early Spermatid (cap phase), El-Spt: Elongating Spermatids, I-Pt: Peritubular tissue with irregular outline, Le-C: Leydig Cell, Ls-GEp: Loss of Germinal Epithelium, M: Meiotic figure, Ne-C: Necrotic Cell, Prm-Spc: Primary Spermatocyte, Rb: Residual bodies, Se-C: Sertoli Cells, Typ-B-Spg: Type B Spermatogonia.

**Figure 4.** Testes Cross-Sections



Staining: TUNNEL. Ap-n: Apoptotic nucleus, Ap-B: Apoptotic Bodies, Ap-C: Apoptotic Cell, BV: Blood Vessel, C-Cr: Condensed Chromosomes, F-n: Fragmented nucleus, Gi-C: Giant Cell formation, Tn (-)-Ge-C: Tunnel negative germinal cell, Tn (+)-Ge-C: Tunnel positive germinal cell, In: Interstitium, Tn (-)-In-C: Tunnel negative interstitial cell, Tn (+)-In-C: Tunnel positive interstitial cell, Rb: Residual bodies, Se-C: Sertoli Cell, Tn (+)-Se-C: Tunnel positive Sertoli cell, Typ-A-Spg: Type A spermatogonia, Typ-B-Spg: Type B spermatogonia, Tn (-)-Typ-A-Spg: Tunnel negative Type A spermatogonia, Tn (-)-Typ-B-Spg: Tunnel negative Type B spermatogonia, Tn (+)-Typ-A-Spg: Tunnel positive Type A spermatogonia, Tn (+)-Typ-B-Spg: Tunnel positive Type B spermatogonia, Tn (+) Spc: Tunnel positive spermatocyte, Tn (+)-Typ Spg: Tunnel positive spermatogonia.

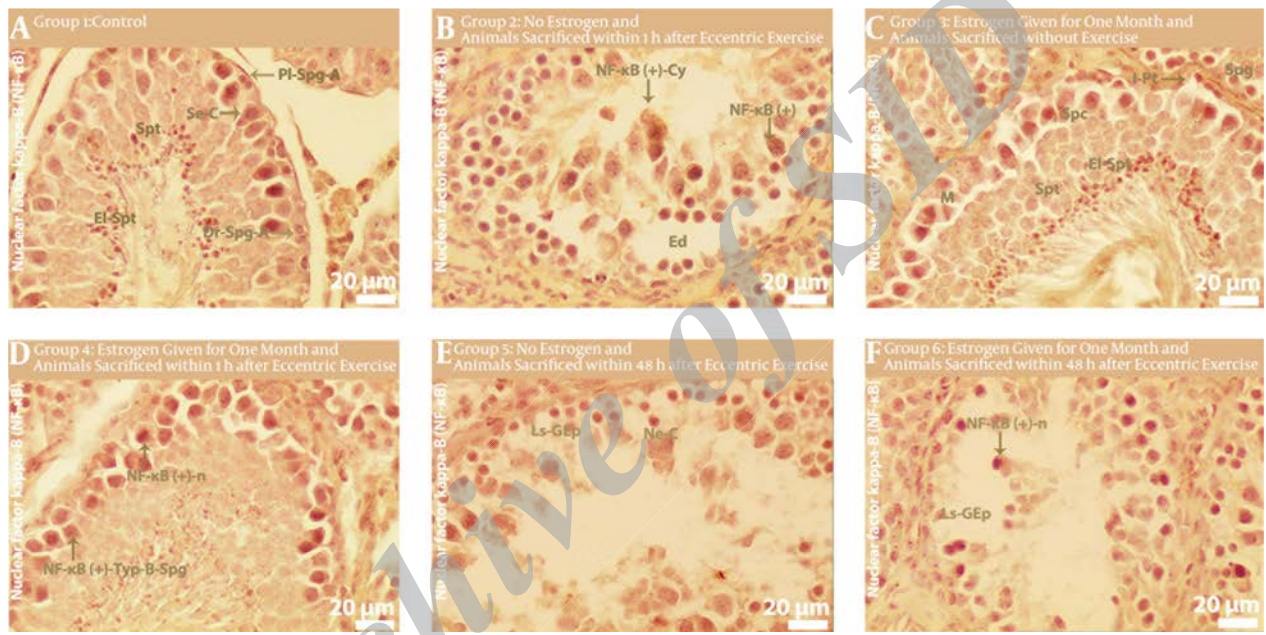


4.2.2. Results of NF-κB Staining

In examination of the control group, weak NF-κB immunopositivity was revealed (Figure 5 A). In the evaluation of the no estrogen applied and dissected one hour after eccentric exercise group, sections revealed mild cytoplasmic immunopositivity in primary spermatocytes (Figure 5 B). Although spermatids exhibit mild immunopositivity, in the examination of the estrogen applied group, cytoplasmic and nuclear immunopositivity in Type A and B spermatogonia were observed (Figure 5 C). Remarkable immunopositivity was found in the majority of Type A and B spermatogonia, primary spermatocytes and early

spermatids in testes sections of the estrogen applied and dissected one hour after eccentric exercise group (Figure 5 D). In the examination of the no estrogen applied and dissected 48 hours after eccentric exercise group, strong cytoplasmic and nuclear immunopositivity was detected in spermatogonia, primary spermatocytes and Sertoli cells (Figure 5 E). In the evaluation of the estrogen applied and dissected 48 hours after eccentric exercise group, the sections revealed strong cytoplasmic and nuclear immunopositivity of spermatogonia, Sertoli cells, primary spermatocytes and early developing spermatids in some tubules (Figure 5 F).

Figure 5. Testes Cross-Sections



Staining: NF-κB-p65. Dr-Spg-A: dark Type A spermatogonia, Ed: Edema, El-Spt: Elongating Spermatids, I-Pt: Peritubular tissue with irregularly outlined, Ls-GEp: loss of germinal epithelium, M: Meiotic figure, Ne-C: Necrotic Cell, NF-κB (+)-Cy: Nuclear Factor kappa b expression positive cytoplasm, NF-κB (+)-n: Nuclear Factor kappa b expression positive nucleus, NF-κB (+)-Typ-B-Spg: Nuclear Factor kappa b expression positive type b spermatogonia, Pl-Spg-A: pale Type A spermatogonia, Se-C: Sertoli Cell, Spc: Spermatocyte, Spg: Spermatogonia, Spt: Spermatid.

Table 1. The Numerical Density of Tunnel Immunopositive Cells<sup>a, b, c</sup>

Groups	Mean Numerical Density of Immunopositive Cells	P Value (ANOVA)	P Value (Tukey)
Control	5.02 ± 0.27	0.000	0.000
Group 2	11.26 ± 0.62	0.000	0.000
Group 3	12.85 ± 0.29	0.000	0.132
Group 4	12.95 ± 0.21	0.000	0.132
Group 5	16.34 ± 0.19	0.000	0.000
Group 6	18.54 ± 0.29	0.000	0.000

<sup>a</sup> One Way ANOVA test (Tukey's HSD) was used for analysis of all the data.  
<sup>b</sup> Data are presented as Mean ± SEM.  
<sup>c</sup> Results of the statistical analysis of quantitative numerical density of all experimental groups revealed a significant increase of TUNNEL immunopositive cells compared to the control group.

4.3. Stereological Results

Assessment results of the numerical density of immunopositive cells in the testes samples of all groups used in this study are summarized in the table below (Table 1).

5. Discussion

Our central hypothesis was that exercise is, in itself, an important stress source because it causes changes in the normal regulation of the hypothalamic-pituitary axis by excessive production of reactive oxygen species. Estrogen supplementation can also be considered in the same way. Our second hypothesis was that this topic might have a connection with infertility in men. For this purpose, the findings obtained from this study were discussed in both contexts.

According to our approach, the first finding was about NF- $\kappa$ B-p65. NF- $\kappa$ B, which is found in almost all animal cell types, is a protein complex. It controls the transcription of DNA (17), which is involved in cellular responses to stimuli, such as bacterial or viral antigens, cytokines and any kind of stress in the body such as extensive or normal physical exercise (18, 19).

In our study, immunopositive cells by staining with NF- $\kappa$ B-p65 were found remarkably in groups 6 and 5, moderately in group 4 and weakly in groups 3 and 2. Additionally, in group 6, both nuclear and cytoplasmic immunopositivity in spermatogonia, Sertoli cells, primary spermatocytes, secondary spermatocyte, early spermatid and the endothelium of interstitial arterioles were determined. Immunopositive cells were observed in all germinal epithelium without exception. In group 5, there were similar findings except in spermatid and interstitial tissues. Immunopositive cells were especially observed in the basal compartment of seminiferous tubules. In group 4, although findings were similar to group 5, immunopositivity was clearly less dense than groups 6 and 5. Immunopositive cells were especially observed in the adluminal compartment of seminiferous tubules. The findings of groups 3 and 2 were almost the same, although there were some small differences. In these two groups, immunopositivity was both less and condensed in spermatogonia.

At this stage, we attempted to investigate what it means, if in tissue, the density of NF- $\kappa$ B-p65 immunopositive cells increases. It has been shown that every physiological and/or pathological process that causes cell stress produces ROS, which can activate the appropriate transcription factor via triggering a signaling cascade and converging on the activation of the transcription factor NF- $\kappa$ B (20). NF- $\kappa$ B, in turn, induces the expression of pro-inflammatory cytokines (21) to arrange or regulate inflammation and to indirectly prevent the possible damaging effect of oxidative stress. Finally, we can say that, first, extensive exercise is a source of oxidative stress and chronic effects are more remarkable than acute effects, and second, in extensive exercise, the situation in testes tissues is exaggerated, instead of protected, by the use of estrogen. Additionally, Cook et al. reported that male rat utero exposure to 17- $\alpha$ -estradiol decreases the number of Sertoli cells as well as sperm production and testicular weight (22).

At this stage, it is important to discuss the presence and density of apoptotic cells in testes tissues suffering from oxidative stress, depending on the severity of the stress. If the tissue encounters any kind of injury, it tries to solve the problem with its own internal mechanisms in order to protect itself against harmful situations. If it succeeds, it repairs the damage and restores the functions. The second choice is to limit the effect of injury by bargaining away some of the cells via apoptosis, which is the normal way to get rid of abnormal cells before necrosis. In this study, the following findings were obtained with the

TUNNEL method. In group 2, there were immunopositive cells by staining with TUNNEL in both basal and adluminal compartments of seminiferous tubules, especially in the early stage spermatogonia and Sertoli cells located on basal side. Although apoptotic primary and secondary spermatocytes were detected, they were lower when compared to those found in the basal compartment. There were no immunopositive cells in the interstitium of testes. In group 3, findings were similar to group 2 with a few exceptions. Immunopositive cell density was a bit less in group 2. There was immunopositivity in early spermatids. In group 3, the presence of spermatids with structural deformity was detected but did not show apoptotic cells. In group 4, immunopositivity exhibited differences from tubule to tubule and the thickness of some tubules clearly decreased. While there were no apoptotic cells in thin tubules, in others there were immunopositive cells in the whole germinal epithelium, especially in primary spermatocytes. Additionally, no immunopositive cells were found in the interstitium of testes. In group 5, it was most remarkable in the density of immunopositive cells in all and different stages of spermatogonia and Sertoli cells. Some primary spermatocytes were stained with TUNNEL, yet others were not. Another interesting finding was related to spermatids. All of the spermatids that contained an acrosome granule were immunopositive. The last important point for this group was the presence of many apoptotic cells in some elements of interstitial tissue, especially in Leydig cells. Group 6 was similar to group 5 with a few exceptions. First, there were no immunopositive cells in the interstitial tissue of testes. Second, there were immunopositive spermatids near the lumen, which had structural defects and giant cell formations. Similar to the classification done in NF- $\kappa$ B-p65 immunopositivity, findings were also valid for TUNNEL. That is to say, according to immunopositivity, there were four categories as follows;

- i) The first consisted of groups 6 and 5
- ii) The second consisted of group 4
- iii) The third consisted of groups 3 and 2 and
- iv) The final was the control group

At this stage of the topic, it is important to discuss what TUNNEL positivity means and what it says to us by implication. Recently, in sport science research, there has been an effort to connect strenuous exercise and oxidative stress, which can lead to programmed cell death, in addition to necrosis or apoptosis (23). In many studies, basic changes occur in mitochondrial function (24, 25) because the mitochondria are the primary source of Reactive Oxygen Species (ROS) in cells, and p53 is regulated by ROS (26). Briefly, whenever mitochondrial function increases to handle the increased metabolic demands of the cell by nutrient absorption (27), the altered ROS formation may also influence p53. Furthermore, mitochondria are vital for carrying out the intrinsic pathway of apoptosis, with p53 facilitating this form of apoptosis through both transcription-dependent and transcription-independent

mechanisms (28).

When histopathological and stereological results were examined in necrosis, cell loss, structural abnormality in some cells, irregularity and fragmentation in cell membranes in both germinal epithelium and Sertoli cells and vascular changes and degeneration in interstitium, as basic indicators of changes in histopathology in testes tissues, were present.

In various studies, it was shown that estrogen is a mitogenic agent, particularly in the endometrium and a variety of tissue cultures (29). However, the suppressing role of estrogen in spermatogenesis was manifested (30). Our findings revealed significantly increased mitotic activity of spermatogonia, especially in group 3. In this context, the estrogen induces oxidative stress and causes damage in testes tissues (31, 32).

The degree of the damage was the same as the results of NF- $\kappa$ B-p65 and TUNNEL. TUNNEL positive germinal epithelium cell density was estimated by the help of the stereological method. Immunopositive cell mean numerical density was 18.54 N/ $\mu$ m<sup>3</sup> in group 6, 16.34 N/ $\mu$ m<sup>3</sup> in group 5, 12.95 N/ $\mu$ m<sup>3</sup> in group 4, 12.85 N/ $\mu$ m<sup>3</sup> in group 3, 11.26 N/ $\mu$ m<sup>3</sup> in group 2 and 5.02 N/ $\mu$ m<sup>3</sup> in group 1. There were significant differences between all groups except group 3 and 4.

In summary, although there are a lot of new studies about testes tissues associated with exercise (33-36) and a few new studies about testes tissues and infertility associated with exercise (36-38), to our knowledge, this is the first study investigating the connection between infertility in males and eccentric exercise/using estrogen according to the SCI-E database. Based on the data presented here, we suggest that eccentric exercise and estrogen supplementation may cause infertility in males.

## Acknowledgements

This study was based on the medical expertise thesis of Jale Selli.

## Authors' Contributions

Study concept and design: Serpil Can and Jale Selli. Analysis and interpretation of data: Basak Buyuk, Sergulen Aydin and Gulname Findik Guvendi. Drafting of the manuscript: Sergulen Aydin, Ramazan Kocaaslan and Jale Selli. Critical revision of the manuscript for important intellectual content: Serpil Can, Jale Selli, Basak Buyuk, Sergulen Aydin, Ramazan Kocaaslan and Gulname Findik Guvendi. Statistical analysis: Serpil Can and Sergulen Aydin.

## References

- Mastorakos G, Pavlatou M, Diamanti-Kandarakis E, Chrousos GP. Exercise and the stress system. *Hormones (Athens)*. 2005;**4**(2):73-89.
- Caston AL, Farrell PA, Deaver DR. Exercise training-induced changes in anterior pituitary gonadotrope of the female rat. *J Appl Physiol (1985)*. 1995;**79**(1):194-201.
- Gill SS, Tuteja N. Reactive oxygen species and antioxidant machinery in abiotic stress tolerance in crop plants. *Plant Physiol Biochem*. 2010;**48**(12):909-30.
- Jarow JP, Kirkland J, Koritnik DR, Cefalu WT. Effect of obesity and fertility status on sex steroid levels in men. *Urology*. 1993;**42**(2):171-4.
- Vicdan K. [ Erkek üreme sisteminin gelişimi ve fonksiyonları üzerinde östrojenin rolü]. *Androloji Bülteni*. 2006;**26**:213-6.
- Pinilla L, Garnelo P, Gaytan F, Aguilar E. Hypothalamic-pituitary function in neonatally oestrogen-treated male rats. *J Endocrinol*. 1992;**134**(2):279-86.
- Chennaoui M, Gomez Merino D, Lesage J, Drogou C, Guezennec CY. Effects of moderate and intensive training on the hypothalamo-pituitary-adrenal axis in rats. *Acta Physiol Scand*. 2002;**175**(2):13-21.
- Riant E, Waget A, Cogo H, Arnal JF, Burcelin R, Gourdy P. Estrogens protect against high-fat diet-induced insulin resistance and glucose intolerance in mice. *Endocrinology*. 2009;**150**(5):2109-17.
- Talbot JA, Morgan DL. The effects of stretch parameters on eccentric exercise-induced damage to toad skeletal muscle. *J Muscle Res Cell Motil*. 1998;**19**(3):237-45.
- Clarkson PM, Sayers SP. Etiology of exercise-induced muscle damage. *Can J Appl Physiol*. 1999;**24**(3):234-48.
- Tsivitse SK, McLoughlin TJ, Peterson JM, Mylona E, McGregor SJ, Pizza FX. Downhill running in rats: influence on neutrophils, macrophages, and MyoD+ cells in skeletal muscle. *Eur J Appl Physiol*. 2003;**90**(5-6):633-8.
- Andersen HL, Weis JU, Fjalland B, Korsgaard N. Effect of acute and long-term treatment with 17-beta-estradiol on the vasomotor responses in the rat aorta. *Br J Pharmacol*. 1999;**126**(1):159-68.
- Rooney TP, Kendrick ZV, Carlson J, Ellis GS, Matakovich B, Lorusso SM, et al. Effect of estradiol on the temporal pattern of exercise-induced tissue glycogen depletion in male rats. *J Appl Physiol (1985)*. 1993;**75**(4):1502-6.
- Warren GL, Lowe DA, Inman CL, Orr OM, Hogan HA, Bloomfield SA, et al. Estradiol effect on anterior crural muscles-tibial bone relationship and susceptibility to injury. *J Appl Physiol (1985)*. 1996;**80**(5):1660-5.
- Aslan H, Altunkaynak BZ, Altunkaynak ME, Vuraler O, Kaplan S, Unal B. Effect of a high fat diet on quantitative features of adipocytes in the omentum: an experimental, stereological and ultrastructural study. *Obes Surg*. 2006;**16**(11):1526-34.
- Halici Z, Keles ON, Unal D, Albayrak M, Suleyman H, Cadirci E, et al. Chronically administered risperidone did not change the number of hepatocytes in rats: a stereological and histopathological study. *Basic Clin Pharmacol Toxicol*. 2008;**102**(5):426-32.
- Xiao W. Advances in NF-kappaB signaling transduction and transcription. *Cell Mol Immunol*. 2004;**1**(6):425-35.
- Zheng X, Long W, Liu G, Zhang X, Yang X. Effect of seabuckthorn (*Hippophae rhamnoides* ssp. *sinensis*) leaf extract on the swimming endurance and exhaustive exercise-induced oxidative stress of rats. *J Sci Food Agric*. 2012;**92**(4):736-42.
- Radak Z, Taylor AW, Ohno H, Goto S. Adaptation to exercise-induced oxidative stress: from muscle to brain. *Exerc Immunol Rev*. 2001;**7**:90-107.
- Bouwmeester T, Bauch A, Ruffner H, Angrand PO, Bergamini G, Croughton K, et al. A physical and functional map of the human TNF-alpha/NF-kappa B signal transduction pathway. *Nat Cell Biol*. 2004;**6**(2):97-105.
- Dijkstra G, Moshage H, van Dullemen HM, de Jager-Krikken A, Tiebosch AT, Kleibeuker JH, et al. Expression of nitric oxide synthases and formation of nitrotyrosine and reactive oxygen species in inflammatory bowel disease. *J Pathol*. 1998;**186**(4):416-21.
- Cook JC, Johnson L, O'Connor JC, Biegel LB, Krams CH, Frame SR, et al. Effects of dietary 17 beta-estradiol exposure on serum hormone concentrations and testicular parameters in male Crl:CD BR rats. *Toxicol Sci*. 1998;**44**(2):155-68.
- Sharafi H, Rahimi R. The effect of resistance exercise on p53, caspase-9, and caspase-3 in trained and untrained men. *The Journal of Strength & Conditioning Research*. 2012;**26**(4):1142-8.
- Alipour M, Salehi I, Ghadiri Soufi F. Effect of exercise on diabetes-induced oxidative stress in the rat hippocampus. *Iran Red Crescent Med J*. 2012;**14**(4):222-8.



25. Raha S, Robinson BH. Mitochondria, oxygen free radicals, and apoptosis. *Am J Med Genet.* 2001;**106**(1):62-70.
26. Liu B, Chen Y, St Clair DK. ROS and p53: a versatile partnership. *Free Radic Biol Med.* 2008;**44**(8):1529-35.
27. Madsen KL, Brockway PD, Johnson LR, Hardin JA, Gall DG. Role of ornithine decarboxylase in enterocyte mitochondrial function and integrity. *Am J Physiol.* 1996;**270**(5 Pt 1):G789-97.
28. Moll UM, Zaika A. Nuclear and mitochondrial apoptotic pathways of p53. *FEBS Lett.* 2001;**493**(2-3):65-9.
29. Wang JM, Liu L, Brinton RD. Estradiol-17beta-induced human neural progenitor cell proliferation is mediated by an estrogen receptor beta-phosphorylated extracellularly regulated kinase pathway. *Endocrinology.* 2008;**149**(1):208-18.
30. Liu C, Duan W, Li R, Xu S, Zhang L, Chen C, et al. Exposure to bisphenol A disrupts meiotic progression during spermatogenesis in adult rats through estrogen-like activity. *Cell Death Dis.* 2013;**4**.
31. Chaki SP, Misro MM, Gautam DK, Kaushik M, Ghosh D, Chainy GB. Estradiol treatment induces testicular oxidative stress and germ cell apoptosis in rats. *Apoptosis.* 2006;**11**(8):1427-37.
32. Sikka SC, Wang R. Endocrine disruptors and estrogenic effects on male reproductive axis. *Asian J Androl.* 2008;**10**(1):134-45.
33. Aksoy Y, Yapanoglu T, Aksoy H, Demircan B, Oztasan N, Canakci E, et al. Effects of endurance training on antioxidant defense mechanisms and lipid peroxidation in testis of rats. *Arch Androl.* 2006;**52**(4):319-23.
34. Dominguez J2, Davis R3, McCullough DJ, Stabley JN, Behnke BJ. Aging and exercise training reduce testes microvascular PO2 and alter vasoconstrictor responsiveness in testicular arterioles. *Am J Physiol Regul Integr Comp Physiol.* 2011;**301**(3):R801-10.
35. Naraghi MA, Abolhasani F, Kashani I, Anarkooli JJ, Hemadi M, Azami A, et al. The effects of swimming exercise and supraphysiological doses of nandrolone decanoate on the testis in adult male rats: a transmission electron microscope study. *Folia morphologica.* 2010;**69**(3):138-46.
36. Shokri S, Aitken RJ, Barbarestani M, Abdolvahhabi M, Abolhasani F, Ghasemi F, et al. Exercise and supraphysiological dose of nandrolone deconoate increase apoptosis in spermatogenic cells| NOVA. The University of Newcastle's Digital Repository. *Basic & clinical pharmacology & toxicology.* 2010;**106**(4):324-30.
37. Ruiz Plazas X, Burgues Gasion JP, Ozonas Moragues M, Piza Reus P. [Utility of inhibin B in the management of male infertility]. *Actas Urol Esp.* 2010;**34**(9):781-7.
38. Safarinejad MR, Azma K, Kolahi AA. The effects of intensive, long-term treadmill running on reproductive hormones, hypothalamus-pituitary-testis axis, and semen quality: a randomized controlled study. *J Endocrinol.* 2009;**200**(3):259-71.