

Effect of Topical Morphine on Cutaneous Leishmaniasis in an Animal Model: A Preliminary Report

Fariborz Ghaffarpasand,¹ Afsoon Akbarzadeh,^{2,*} Hamid Reza Heiran,³ Ali Asghar Karimi,¹ Armin Akbarzadeh,⁴ and Mohamed Amin Ghobadifar⁵

¹Neuroscience Research Center, Shiraz University of Medical Sciences, Shiraz, IR Iran

²Student Research Committee, Shahid Beheshti University of Medical Sciences, Tehran, IR Iran

³Autoimmune Disease Research Center, Shiraz University of Medical Sciences, Shiraz, IR Iran

⁴Student Research Committee, Shiraz University of Medical Sciences, Shiraz, IR Iran

⁵Zoonoses Research Center, Jahrom University of Medical Sciences, Jahrom, IR Iran

*Corresponding author: Afsoon Akbarzadeh, Student Research Committee, Shahid Beheshti University of Medical Sciences, Tehran, IR Iran. Tel: +98-7112122970, Fax: +98-7112122970, E-mail: akbarzadeh.af@gmail.com

Received 2014 October 17; Revised 2016 February 13; Accepted 2016 April 02.

Abstract

Background: Pentavalent antimonials remain the choice of treatment for leishmaniasis, despite their toxicity, high cost, and difficult administration. As an alternative, morphine may induce the healing process of cutaneous leishmaniasis by its immunoregulatory characteristics.

Objectives: To study the effect of morphine on the wound-healing process of cutaneous leishmaniasis (CL) in a mouse model.

Materials and Methods: This was an experimental study in which 40 BALB/c mice (female, 6 - 8 weeks) were divided into four groups (each n=10) who received either placebo alone (group 1), morphine ointment after parasite inoculation (group 2), morphine ointment after wound occurrence (group 3), or placebo after wound occurrence (group 4). Wound size was measured weekly for eight weeks.

Results: On the first day of treatment, the lesions measured 1.5 mm in diameter. After eight weeks of treatment, the wound size was significantly smaller in the mice who received morphine ointment (4.81 ± 3.22 mm) compared to those who received placebo after parasite inoculation (8.95 ± 5.71 mm; $P = 0.0001$) or placebo after wound occurrence ($P = 0.028$).

Conclusions: The above data suggest that topical application of morphine accelerates the healing process of CL wounds. We are cautiously optimistic that the results of this study can be used clinically for potentiating CL wound-healing.

Keywords: Cutaneous Leishmaniasis, Topical Morphine, BALB/c, Mice, *Leishmania major*

1. Background

Leishmaniasis is a major world health problem, with an annual incidence of 1 - 1.5 million cases (90% occurring in the old world, including southern Europe, the Middle East, parts of southwest Asia, and Africa) resulting in 70,000 deaths each year, with 350 million individuals at risk (1). It is also endemic in some parts of Iran, and its prevalence has been reported to vary from 1.8% to 37.9% in different provinces of the country (2-4). The most common type of the disease is cutaneous leishmaniasis (CL) which is caused by several species of *Leishmania*, especially *L. major*.

Pentavalent antimonials (sodium stibogluconate or meglumine antimoniate) are still the choice of treatment for leishmaniasis. These medications are widely used despite their toxicity, high cost, and difficult administration. Other treatment options include topical paromomycin (5), topical amphotericin B (6), oral miltefosine (7), and additional immunomodulators, including topical imiquimod (8, 9) and human granulocyte macrophage

colony-stimulation factor (GM-CSF) (10), which have been shown to be effective in the treatment of CL (11, 12). However, as CL is a health problem mostly in developing countries and therefore does not offer enough commercial motivation for pharmaceutical companies to develop cheaper effective anti-leishmaniasis medications, there is no effective drug or vaccine against it.

Opioids, including morphine, have been shown to have immunoregulatory effects through their receptor interactions with immune cells, and can thus be classified as part of the cytokine family (13). Many investigations have demonstrated the effect of opioid treatment on antibody responses. It seems that the molecular basis for this effect is due to the modulation of cytokines and altered expression of cytokine receptors (13, 14). Low doses of morphine, administered subcutaneously in *L. donovani*-infected BALB/c mice or hamsters, significantly suppressed or even sterile-cleared the infection; paradoxically, high doses exacerbated the infection (15, 16). On the other hand,

Poonawala et al. (17) have shown that morphine hastens the healing process of ischemic wounds by stimulating nitric oxide (NO) via the μ opioid receptor, thus promoting vasodilation.

It can be hypothesized that morphine may induce the healing process of cutaneous leishmaniasis (18).

2. Objectives

Therefore, the aim of this study was to study the efficacy of topical morphine in the treatment of *L. major*-infected BALB/c mice.

3. Materials and Methods

3.1. Materials

Pharmacological-grade morphine (Baxter Esilerderle Mfd. Healthcare Corporation, Cherry Hill, NJ, USA) was added to the ointment base in our laboratory. The ointment base consisted of cetomacrogol 1000, Vaseline, liquid paraffin, methylparaben, and propylparaben (Sigma-Aldrich, Prague, Czech Republic), cetostearyl alcohol, and water. Morphine was added to this ointment in 1.5 mg/mL doses. After completely cleaning the wounds with sterile normal saline, the ointment was topically applied to the wound area twice per day (16, 19).

3.2. Animals

A total of 40 BALB/c mice (female, 6 - 8 weeks old) were obtained from the Pasteur Institute of Iran in Tehran, each weighing 20 g at the time of infection. A regular rodent diet and tap water were supplied. The rats were maintained under controlled environmental conditions (12-hour light/dark cycle at 23°C). The mice were divided into four groups of 10 each. The first group received the parasite plus placebo for two months, while the second group simultaneously received parasite and morphine ointment twice daily for two months. The third group received the parasite, and after the occurrence of wounds (ulcers), the placebo was applied twice daily for eight weeks. The fourth group received the parasite, and after the occurrence of ulcer wounds, morphine ointment was applied twice daily for two months. The experiments were performed in accordance with the regulations specified by the institute's animal ethics committee, and conformed to national guidelines on the care and use of laboratory animals in Iran.

3.3. Parasites

Amastigotes of *L. major* (MHOM/IR/76/ER) were taken from previously infected BALB/c mice. The parasites were made into a final concentration of 10^3 - 10^4 cell/mL, and 200 μ L of this solution was used for each inoculation.

3.4. In Vivo Cutaneous Leishmaniasis

The mice were subcutaneously infected in the tail area (0.2 mL) with 10^3 - 10^4 late-stage *L. major* MHOM/IR/76/ER amastigotes. Cutaneous lesions were measured weekly for eight weeks using analog rulers, and compared with the untreated controls to evaluate the therapy. Topical formulations were applied only to the lesions.

3.5. Statistical Analysis

All statistical analyses were performed using the statistical package for social sciences, version 15.0 (SPSS Inc., Chicago, IL, USA). The results are expressed as mean \pm standard deviation. independent student's t-test was applied for comparisons between mean wound sizes. All tests were two-sided. A power of 0.8 was expected for the present study, and the level of significance was set at $P < 0.05$.

4. Results

4.1. Development of Cutaneous Leishmaniasis in BALB/c Mice

Over the 2 - 3 weeks after inoculation of BALB/c mice with 10^3 - 10^4 amastigotes of *L. major* (MHOM/IR/76/ER) into the base of the tail, nodules developed in groups 1, 3, and 4. Two weeks later (after four weeks of study), the nodules transformed into ulcers. At this stage, placebo or morphine ointment was applied to groups 3 and 4, respectively.

Lesion diameter was measured weekly for 8 weeks. In all groups, the diameter of the lesions increased over time. On the first day of treatment, the lesions measured approximately 1.5 mm in diameter in all groups. During the eight weeks of evaluation of the lesions, their sizes differentiated. As Figure 1 shows, lesions in the animals treated with topical morphine after inoculation did not expand as much as in the other groups. The lesions treated with topical morphine after lesion presentation had smaller diameters compared to both placebo groups. The wound areas of the lesions treated with morphine ointment were smaller in size and did not ulcerate compared to the control groups. However, none of the lesions healed completely. The mean diameter of the lesions is illustrated in Figure 1.

4.2. Comparison of Lesion Size Between Study Groups

The sizes of the lesions in the four study groups after eight weeks are shown in Table 1. After eight weeks, the diameters increased to 8.9 mm and 4.8 mm, respectively, in the placebo and morphine groups that were treated after inoculation ($P = 0.0001$). Similarly, after eight weeks of evaluation, the sizes of the lesions treated after their presentation were significantly greater in the placebo group compared to the morphine group (10.8 ± 6.32 mm vs. 7.81

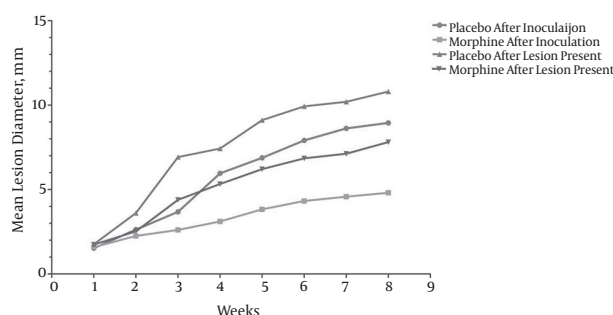


Figure 1. Mean Lesion Diameter of BALB/c Mice Infected With *L. major* MHOM/IR/76/ER and Treated With Morphine Formulations Versus Controls

± 4.22 mm; $P = 0.003$). Administration of morphine ointment after parasite inoculation significantly reduced the lesion size compared to administration of morphine ointment after wound occurrence (4.81 ± 3.22 mm vs. 7.81 ± 4.22 mm; $P = 0.028$). Topical morphine administration after wound occurrence had no extra advantage in reducing lesion size compared to placebo administration at the time of parasite inoculation (7.81 ± 4.22 mm vs. 8.95 ± 5.71 mm; $P = 0.087$). From the fifth week of the study, the lesion size became significantly smaller in both morphine groups (groups 2 and 4) compared to the controls (groups 1 and 3) (Table 1).

5. Discussion

Few studies have been conducted on problems with topical treatments used for any form of leishmaniasis, although these treatments are commonly used for topical bacterial, viral, and fungal infections. Indications for topical treatment of CL include a lack of risk of developing mucosal lesions, old world CL, *L. mexicana* CL, small and single lesions, and absence of lymph node metastasis (20). The present study attempted to develop a new topical treatment for CL by examining the simple question of whether topically-applied morphine accelerates the wound-healing process of CL lesions in mice. Previously, it was shown that opioids, including morphine, act as analgesics for pain relief in peripheral ulcers (21). In addition, receptors of the opioid are present at the site of the wound and can even be activated (22). Of relevance, opioids, such as morphine and β -endorphin, stimulate production of interleukin (IL)-6 in animal models (23, 24), which would be suggestive for enhancing wound-healing. Previous studies revealed that the process of wound-healing is significantly delayed in IL-6-deficient transgenic mice (25-27). Therefore, the faster healing observed in the present study of CL lesions with topical morphine application is consistent with

all of the above effects of opioids on peripheral tissues. Wound closure was accelerated particularly in the first five weeks with morphine ointment. Therefore, the major effect of morphine in the present study was to shorten the lag phase during the wound-healing process. These results can have direct implications in the healing of CL lesions, which have a long lag phase in the initial healing process. It is likely that the topical morphine receptors mediate this process. Thus, the direct availability of opioids at the site of injury is probably required for the healing of CL lesions. Moreover, endogenous opioid receptor agonists via peripheral opioid receptors may be involved in the healing process.

Opioids have been applied topically for pain management and have not caused any side-effects, such as dependence and tolerance, when used peripherally at low doses (21).

These experiments on BALB/c mice infected with *L. major* indicate that topical formulations of morphine delay the progression of these lesions. Several factors should be taken into account that can alter the efficacy of the medication. For example, the timing of the start of treatment can influence the outcome. In the present study, topical treatment was started at the time of parasite inoculation or after wound occurrence. After eight weeks of evaluation, treatment that was started immediately post-infection had a more significant effect on lesion progression compared to treatment started after wound occurrence ($P = 0.028$). On the other hand, topical morphine administration after wound occurrence did not have any extra advantage in reducing lesion size compared to placebo administration at the time of parasite inoculation ($P = 0.087$). However, treatment with topical morphine after wound occurrence significantly delayed wound progression compared to the controls ($P = 0.003$). A previous study investigated the effect of subcutaneous administration of morphine on *L. donovani* lesions. Similar to our study, the results revealed that low doses of morphine can suppress the infection and increase the number of monocytes, while high doses exacerbate the infection in animal models.

Previous investigations have shown different penetration levels of medications in human versus mouse skin (28, 29). Consequently, an ointment formulation that has been optimized for an animal model will probably have different outcomes on human skin. Thus, it seems that human studies are needed in order to evaluate the effect of topical morphine on *Leishmania* lesions.

There were some limitations to our study. First, this was a preliminary study and lacked certain additional variables, including the parasite burden of the lesions or the drainage of lymph nodes, as well as pathologic evaluations of the lesions. Future studies should include these vari-

Table 1. Comparison Between *Leishmania* Lesion Sizes After Eight Weeks of Treatment^{a,b}

Treatment, w	Group 1	Group 2	P Value ^c	Group 3	Group 4	P Value ^c
One	1.53 ± 0.75	1.59 ± 0.62	0.953	1.76 ± 1.12	1.74 ± 0.93	0.758
Two	2.63 ± 1.25	2.25 ± 1.61	0.356	3.61 ± 0.85	2.52 ± 0.76	0.276
Three	3.68 ± 0.56	2.61 ± 1.56	0.391	6.92 ± 2.55	4.39 ± 1.57	0.096
Four	5.96 ± 0.34	3.11 ± 0.98	0.088	7.43 ± 3.86	5.33 ± 1.66	0.072
Five	6.88 ± 2.28	3.83 ± 1.55	0.031	9.11 ± 2.11	6.21 ± 2.54	0.033
Six	7.91 ± 3.56	4.32 ± 1.27	0.046	9.93 ± 4.38	6.85 ± 3.14	0.024
Seven	8.62 ± 3.25	4.58 ± 1.86	0.002	10.2 ± 5.84	7.12 ± 3.57	0.013
Eight	8.95 ± 5.71	4.81 ± 3.22	0.0001	10.8 ± 6.32	7.81 ± 4.22	0.003

^a Group 1, placebo after inoculation; group 2, morphine ointment after inoculation; group 3, placebo after lesions present; group 4, morphine after lesions present.

^b P value < 0.05 is considered significant.

^c Using independent Student's t-test.

ables in order to better determine the effects of morphine. Second, we did not measure cytokine levels, including IL-6. Measuring these will lead to a better understanding of the mechanism of action of topical morphine for CL treatment. Thirdly, we did not include a group of mice receiving conventional treatment, including topical paromomycin or topical imiquimod. It is likely that a combination of morphine with a substance active against leishmaniasis (such as 15% paromomycin plus 12% methylbenzethonium chloride) would give better results than each substance alone. Also, similar future research should be performed with larger sample sizes. Further investigations are needed in order to clarify the effectiveness of morphine on *Leishmania* lesions and its probable side effects, so that it can be applied in human studies.

5.1. Conclusions

The above data suggest that topical application of morphine may accelerate the healing of CL wounds. Therefore, we optimistically suggest that topical morphine can be used clinically for potentiating CL wound-healing. More studies, preferably on humans, should be performed in order to clarify the effects of topical morphine on the wound-healing process in CL.

Acknowledgments

The authors would like to thank the center for development of clinical research of Nemazee hospital. We also thank Nasrin Shokrpour for editorial assistance and Sareh Roosta for statistical assistance.

Footnotes

Authors' Contribution: Study concept and design: Fariborz Ghaffarpasand and Armin Akbarzadeh; acquisition of data: Ali Asghar Karimi and Mohamed Amin Ghobadifar; analysis and interpretation of data: Afsoon Akbarzadeh and Hamid Reza Heiran; drafting of the manuscript: Fariborz Ghaffarpasand and Afsoon Akbarzadeh; critical revision of the manuscript for important intellectual content: Fariborz Ghaffarpasand, Armin Akbarzadeh, Mohamed Amin Ghobadifar, Hamid Reza Heiran and Ali Asghar Karimi; statistical analysis: Hamid Reza Heiran and Ali Asghar Karimi; administrative, technical, and material support: Afsoon Akbarzadeh, Hamid Reza Heiran and Mohamed Amin Ghobadifar; study supervision: Fariborz Ghaffarpasand and Hamid Reza Heiran.

Funding/Support: The investigation was financially supported by a research grant from the student research committee of Fasa University of Medical Sciences (FUMS-2009-2614).

References

- McGwire BS, Satoskar AR. Leishmaniasis: clinical syndromes and treatment. *QJM*. 2014;**107**(1):7-14. doi: [10.1093/qjmed/hct116](https://doi.org/10.1093/qjmed/hct116). [PubMed: [23744570](https://pubmed.ncbi.nlm.nih.gov/23744570/)].
- Mohebbali M, Edrissian GH, Shirzadi MR, Akhond B, Hajjaran H, Zarei Z, et al. An observational study on the current distribution of visceral leishmaniasis in different geographical zones of Iran and implication to health policy. *Travel Med Infect Dis*. 2011;**9**(2):67-74. doi: [10.1016/j.tmaid.2011.02.003](https://doi.org/10.1016/j.tmaid.2011.02.003). [PubMed: [2149708](https://pubmed.ncbi.nlm.nih.gov/2149708/)].
- Youssefi MR, Esfandiari B, Shojaei J, Jalali H, Amoli S, Ghasemi H, et al. Prevalence of cutaneous leishmaniasis during 2010 in Mazandaran Province, Iran. *Afr J Microbiol Res*. 2011;**5**(31):5790-2.
- Kassiri H, Shemshad K, Kassiri A, Shojaei S, Sharifinia N, Shemshad M. Clinical laboratory and epidemiological research on cutaneous leishmaniasis in the south west of Iran. *Arch Clin Infect Dis*. 2012;**7**(4):128-31.

5. Iraj F, Sadeghinia A. Efficacy of paromomycin ointment in the treatment of cutaneous leishmaniasis: results of a double-blind, randomized trial in Isfahan, Iran. *Ann Trop Med Parasitol*. 2005;**99**(1):3-9. doi: [10.1179/136485905X16372](https://doi.org/10.1179/136485905X16372). [PubMed: [15701249](https://pubmed.ncbi.nlm.nih.gov/15701249/)].
6. Zvulunov A, Cagnano E, Frankenburg S, Barenholz Y, Vardy D. Topical treatment of persistent cutaneous leishmaniasis with ethanolic lipid amphotericin B. *Pediatr Infect Dis J*. 2003;**22**(6):567-9. [PubMed: [12828157](https://pubmed.ncbi.nlm.nih.gov/12828157/)].
7. Soto J, Arana BA, Toledo J, Rizzo N, Vega JC, Diaz A, et al. Miltefosine for new world cutaneous leishmaniasis. *Clin Infect Dis*. 2004;**38**(9):1266-72. doi: [10.1086/383321](https://doi.org/10.1086/383321). [PubMed: [15127339](https://pubmed.ncbi.nlm.nih.gov/15127339/)].
8. Arevalo I, Ward B, Miller R, Meng TC, Najar E, Alvarez E, et al. Successful treatment of drug-resistant cutaneous leishmaniasis in humans by use of imiquimod, an immunomodulator. *Clin Infect Dis*. 2001;**33**(11):1847-51. doi: [10.1086/324161](https://doi.org/10.1086/324161). [PubMed: [11692295](https://pubmed.ncbi.nlm.nih.gov/11692295/)].
9. Arevalo I, Tulliano G, Quispe A, Spaeth G, Matlashewski G, Llanos-Cuentas A, et al. Role of imiquimod and parenteral meglumine antimoniate in the initial treatment of cutaneous leishmaniasis. *Clin Infect Dis*. 2007;**44**(12):1549-54. doi: [10.1086/518172](https://doi.org/10.1086/518172). [PubMed: [17516397](https://pubmed.ncbi.nlm.nih.gov/17516397/)].
10. Almeida RP, Brito J, Machado PL, D. E. Jesus AR, Schrieffer A, Guimaraes LH, et al. Successful treatment of refractory cutaneous leishmaniasis with GM-CSF and antimonials. *Am J Trop Med Hyg*. 2005;**73**(1):79-81. [PubMed: [16014838](https://pubmed.ncbi.nlm.nih.gov/16014838/)].
11. Hooshyar H, Talari S, Feyzi F. Therapeutic Effect of Hedera helix Alcoholic Extract Against Cutaneous Leishmaniasis Caused by Leishmania major in Balb/c Mice. *Jundishapur J Microbiol*. 2014;**7**(4):ee9432. doi: [10.5812/jjm.9432](https://doi.org/10.5812/jjm.9432). [PubMed: [25147703](https://pubmed.ncbi.nlm.nih.gov/25147703/)].
12. Ebrahimisadr P, Ghaffarifar F, Hassan ZM, Sirousazar M, Mohammadnejad F. Effect of Polyvinyl Alcohol (PVA) Containing Artemether in Treatment of Cutaneous Leishmaniasis Caused by Leishmania major in BALB/c Mice. *Jundishapur J Microbiol*. 2014;**7**(5):ee9696. doi: [10.5812/jjm.9696](https://doi.org/10.5812/jjm.9696). [PubMed: [25147717](https://pubmed.ncbi.nlm.nih.gov/25147717/)].
13. Boland JW, Foulds GA, Ahmedzai SH, Pockley AG. A preliminary evaluation of the effects of opioids on innate and adaptive human in vitro immune function. *BMJ Support Palliat Care*. 2014;**4**(4):357-67. doi: [10.1136/bmjspcare-2013-000573](https://doi.org/10.1136/bmjspcare-2013-000573). [PubMed: [24644198](https://pubmed.ncbi.nlm.nih.gov/24644198/)].
14. Kardeh S, Ashkani-Esfahani S, Alizadeh AM. Paradoxical action of reactive oxygen species in creation and therapy of cancer. *Eur J Pharmacol*. 2014;**735**:150-68. doi: [10.1016/j.ejphar.2014.04.023](https://doi.org/10.1016/j.ejphar.2014.04.023). [PubMed: [24780648](https://pubmed.ncbi.nlm.nih.gov/24780648/)].
15. Singh PP, Singal P. Morphine-induced neuroimmunomodulation in murine visceral leishmaniasis: the role(s) of cytokines and nitric oxide. *J Neuroimmune Pharmacol*. 2007;**2**(4):338-51. doi: [10.1007/s11481-007-9094-y](https://doi.org/10.1007/s11481-007-9094-y). [PubMed: [18040852](https://pubmed.ncbi.nlm.nih.gov/18040852/)].
16. Singal P, Kinshikar AG, Singh S, Singh PP. Neuroimmunomodulatory effects of morphine in Leishmania donovani-infected hamsters. *Neuroimmunomodulation*. 2002;**10**(5):261-9. [PubMed: [12759563](https://pubmed.ncbi.nlm.nih.gov/12759563/)].
17. Poonawala T, Levay-Young BK, Hebbel RP, Gupta K. Opioids heal ischemic wounds in the rat. *Wound Repair Regen*. 2005;**13**(2):165-74. doi: [10.1111/j.1067-1927.2005.130207.x](https://doi.org/10.1111/j.1067-1927.2005.130207.x). [PubMed: [15828941](https://pubmed.ncbi.nlm.nih.gov/15828941/)].
18. Alavi-Naini R. Topical morphine for the treatment of cutaneous leishmaniasis. *Med Hypotheses*. 2008;**70**(1):81-4. doi: [10.1016/j.mehy.2007.04.027](https://doi.org/10.1016/j.mehy.2007.04.027). [PubMed: [17582693](https://pubmed.ncbi.nlm.nih.gov/17582693/)].
19. Ribeiro MD, Joel SP, Zeppetella G. The bioavailability of morphine applied topically to cutaneous ulcers. *J Pain Symptom Manage*. 2004;**27**(5):434-9. doi: [10.1016/j.jpainsymman.2003.09.011](https://doi.org/10.1016/j.jpainsymman.2003.09.011). [PubMed: [15120772](https://pubmed.ncbi.nlm.nih.gov/15120772/)].
20. Blum J, Desjeux P, Schwartz E, Beck B, Hatz C. Treatment of cutaneous leishmaniasis among travellers. *J Antimicrob Chemother*. 2004;**53**(2):158-66. doi: [10.1093/jac/dkh058](https://doi.org/10.1093/jac/dkh058). [PubMed: [14729756](https://pubmed.ncbi.nlm.nih.gov/14729756/)].
21. Leppert W, Krajnik M, Wordliczek J. Delivery systems of opioid analgesics for pain relief: a review. *Curr Pharm Des*. 2013;**19**(41):7271-93. [PubMed: [23489205](https://pubmed.ncbi.nlm.nih.gov/23489205/)].
22. Argoff CE. Topical analgesics in the management of acute and chronic pain. *Mayo Clin Proc*. 2013;**88**(2):195-205. doi: [10.1016/j.mayocp.2012.11.015](https://doi.org/10.1016/j.mayocp.2012.11.015). [PubMed: [23374622](https://pubmed.ncbi.nlm.nih.gov/23374622/)].
23. Vodo S, Arcelli D, Fiorenzani P, Meriggiola MC, Butkevich I, Di Canio C, et al. Gonadal ERalpha/beta, AR and TRPV1 gene expression: modulation by pain and morphine treatment in male and female rats. *Physiol Behav*. 2013;**110-111**:80-6. doi: [10.1016/j.physbeh.2012.12.014](https://doi.org/10.1016/j.physbeh.2012.12.014). [PubMed: [23287630](https://pubmed.ncbi.nlm.nih.gov/23287630/)].
24. Fan H, Gong N, Li TF, Ma AN, Wu XY, Wang MW, et al. The non-peptide GLP-1 receptor agonist WB4-24 blocks inflammatory nociception by stimulating beta-endorphin release from spinal microglia. *Br J Pharmacol*. 2015;**172**(1):64-79. doi: [10.1111/bph.12895](https://doi.org/10.1111/bph.12895). [PubMed: [25176008](https://pubmed.ncbi.nlm.nih.gov/25176008/)].
25. Gallucci RM, Sugawara T, Yucesoy B, Berryann K, Simeonova PP, Matheson JM, et al. Interleukin-6 treatment augments cutaneous wound healing in immunosuppressed mice. *J Interferon Cytokine Res*. 2001;**21**(8):603-9. doi: [10.1089/10799900152547867](https://doi.org/10.1089/10799900152547867). [PubMed: [11559438](https://pubmed.ncbi.nlm.nih.gov/11559438/)].
26. Lin ZQ, Kondo T, Ishida Y, Takayasu T, Mukaida N. Essential involvement of IL-6 in the skin wound-healing process as evidenced by delayed wound healing in IL-6-deficient mice. *J Leukoc Biol*. 2003;**73**(6):713-21. [PubMed: [12773503](https://pubmed.ncbi.nlm.nih.gov/12773503/)].
27. Noorafshan A, Kardeh S, Ashkani-Esfahani S, Namazi M, Saleh E. The Effects of Oltipraz on Tissue Regeneration in the Process of Wound Healing: A Stereological Study. *Bull Emerg Trauma*. 2014;**2**(4 OCT):161-5.
28. Reimao JQ, Colombo FA, Pereira-Chioccola VL, Tempone AG. Effectiveness of liposomal buparvaquone in an experimental hamster model of Leishmania (L.) infantum chagasi. *Exp Parasitol*. 2012;**130**(3):195-9. doi: [10.1016/j.exppara.2012.01.010](https://doi.org/10.1016/j.exppara.2012.01.010). [PubMed: [22281156](https://pubmed.ncbi.nlm.nih.gov/22281156/)].
29. Garnier T, Mantyla A, Jarvinen T, Lawrence MJ, Brown MB, Croft SL. Topical buparvaquone formulations for the treatment of cutaneous leishmaniasis. *J Pharm Pharmacol*. 2007;**59**(1):41-9. doi: [10.1211/jpp.59.1.0006](https://doi.org/10.1211/jpp.59.1.0006). [PubMed: [17227619](https://pubmed.ncbi.nlm.nih.gov/17227619/)].